Gustave L. and Janet W. Levy
Library of Mount Sinai

THE MOUNT SINAI HOSPITAL
JACOBI
LIBRARY
NEW YORK

Digitized by the Internet Archive
in 2015

https://archive.org/details/journalofmountsi2219moun

MAY 25 1955

S. Schmerson p. 1.
Wachel, Dr. Jenkins p. 6.
A. G. White p. 15.
Mandelbaum, David Bryk p. 24.
S. R. Robbin, Dack p. 34
Jemerin, Cornell p. 47
Laval, Chatzinoff p. 54.
B. Wolf; M. Bender + S. Brahms p. 62.
Dr Khilnani, Dr Wolf, Dr Arnheim p. 53.

THE MOUNT SINAI HOSPITAL
JACOBI LIBRARY
NEW YORK

JOURNAL OF THE MOUNT SINAI HOSPITAL NEW YORK

(4) 99

VOLUME XXII
NUMBER 1
MAY-JUNE 1955

the easy, pleasant way

to administer hydrochloric acid

Lilly

QUALITY / RESEARCH / INTEGRITY

'Acidulin'

(GLUTAMIC ACID HYDROCHLORIDE, LILLY)

safe hydrochloric acid therapy in tasteless pulvule form

'Acidulin' offers your patient complete freedom from unpleasant taste and injury to the mucous membranes and teeth. It is convenient and safe to carry when traveling or dining out.

Each pulvule is equivalent to about 10 minims of Diluted Hydrochloric Acid, U.S.P. For the average patient with hypochlorhydria or achlorhydria, 2 to 3 Pulvules 'Acidulin' before meals are usually adequate.

Supplied in bottles of 100, 500, and 1,000.

ELI LILLY AND COMPANY • INDIANAPOLIS 6, INDIANA, U.S.A.

THE MOUNT SINAI HO
JACOBI
LIBRARY
NEW YORK

BACTERIAL SENSITIVITY TO ERYTHROMYCIN: TWO YEARS EXPERIENCE (1953–1954)

S. STANLEY SCHNEIERSON, M.D.

New York, N. Y.

The introduction and widespread administration of each antibiotic has invariably resulted in the development of resistance to its action by a number of originally sensitive bacterial species, thereby limiting the scope and effectiveness of each new discovery (1–5). It becomes of prime interest therefore to ascertain whether or not a similar situation with respect to erythromycin has also prevailed, especially since it is possible to produce erythromycin-resistant strains of bacteria from erythromycin-sensitive organisms in the laboratory by repeated subculture in media containing graded concentrations of erythromycin (6). Erythromycin has been in ever increasing use at The Mount Sinai Hospital and in the general community for the past two years, stimulated no doubt by such inherent attributes as its therapeutic effectiveness, ease of administration and relatively low index of toxicity. Furthermore, the discovery of such serious deficiencies in the earlier antibiotics as increasing bacterial resistance, severe adverse reactions and even deaths from their use has certainly tended to enhance this trend. As a result, more and more physicians are presently prescribing erythromycin as the drug of choice for many of their cases, thereby accounting for its much wider general employment as illustrated by the five to six fold increase in the amount of erythromycin ordered from the Mount Sinai Hospital Pharmacy in 1954 as compared to 1953.

Most of the microorganisms isolated at the hospital from a variety of clinical sources, e.g., blood, urine, spinal fluid, abscesses and purulent exudates, sputum, the nose and throat, etc., are ordinarily subjected to sensitivity tests to a number of different antibiotics, including erythromycin. Analysis of the results of these erythromycin determinations throughout the period under investigation afforded an excellent opportunity to ascertain whether or not any changes in the susceptibility pattern of any bacterial species, as expressed by a relative increase in the percentage of resistant strains, had taken place during this interval. Only those organisms ordinarily considered sensitive to the action of erythromycin and obtained on primary isolation immediately following admission to the hospital or the initial development of the pathological lesion prior to the institution of treatment are included in this survey.

No technical or procedural changes in the performance of the tests have been introduced during this time so that the findings are directly comparable. The method for determining antibiotic sensitivity employed in this laboratory is the tube dilution method. The type of medium, preparation of antibiotic standards, size of inoculum for each species, temperature, and duration of incubation are all

From the Department of Microbiology, The Mount Sinai Hospital, New York, N. Y.

11323

carefully controlled. The test is performed by adding one milliliter of the standardized inoculum to a series of tubes containing varying concentrations of the antibiotic in one milliliter of broth. The end point, read after eighteen hours incubation at 37° C, is the first clear tube, indicating complete visual inhibition of growth, containing the least amount of drug. A growth control tube containing the test inoculum without antibiotic is employed with each determination.

The findings have been divided into four equal six-month periods in order to facilitate the analysis and discover any progressive changes, if present. To cover the broad range of values, the results of the sensitivity determinations were listed in three categories, depending upon the concentration of antibiotic needed to inhibit the growth of a standardized inoculum of the organism under test, namely, Sensitive, Moderately Resistant and Resistant. Strains inhibited by 1 mcg/ml or less of erythromycin were classified as Sensitive; greater than 1.0 mcg/ml but less than 5.0 mcg/ml as Moderately Resistant; and those not inhibited by 5.0 mcg/ml as Resistant.

RESULTS

The results of this survey are presented in Table I.

As may be noted from Table I, with the exception of an occasional Moder-

TABLE I

Comparative sensitivity to erythromycin of pathogenic microorganisms isolated over two year period

Period		(I) Jan. 1–June 30, 1953		(II) July 1–Dec. 31, 1953		(III) Jan. 1–June 30, 1954		(IV) July 1–Dec. 31, 1954	
Organism	Sensitivity Status*	Number	% Total	Number	% Total	Number	% Total	Number	% Total
Staphylococcus aureus	Sensitive	56	93.4	111	92.5	126	90.0	216	90.4
	Mod. Resistant	2	3.3	—	0.0	3	2.2	2	0.8
	Resistant	2	3.3	9	7.5	11	7.8	21	8.8
Staphylococcus albus	Sensitive	14	93.4	14	100.0	15	100.0	33	94.4
	Mod. Resistant	1	6.6	—	0.0	—	0.0	1	2.8
	Resistant	—	0.0	—	0.0		0.0	1	2.8
Streptococcus fecalis	Sensitive	10	90.9	27	90.0	49	83.1	137	87.8
	Mod. Resistant	—	0.0		0.0	2	3.4	2	1.3
	Resistant	1	9.1	3	10.0	8	13.5	17	10.9
Streptococcus viridans	Sensitive	13	100.0	16	94.1	14	100.0	18	94.7
	Mod. Resistant	—	0.0	1	5.9	—	0.0	1	5.3
	Resistant	—	0.0	—	0.0	—	0.0	—	0.0
Beta Hemolytic Streptococcus	Sensitive	10	100.0	7	100.0	18	100.0	11	100.0
	Mod. Resistant	—	0.0	—	0.0	—	0.0	—	0.0
	Resistant	—	0.0	—	0.0	—	0.0	—	0.0
Pneumococcus	Sensitive	4	100.0	11	100.0	5	100.0	2	100.0
	Mod. Resistant	—	0.0	—	0.0	—	0.0	—	0.0
	Resistant	—	0.0	—	0.0	—	0.0	—	0.0

* Strains inhibited by 1 mcg/ml or less are designated as Sensitive; by more than 1.0 mcg/ml but less than 5 mcg/ml as Moderately Resistant; and those not inhibited by 5.0 mcg/ml as Resistant.

TABLE II

Over-all incidence of erythromycin-resistant bacterial strains isolated during 1953–1954*

Organism	Number Tested	Erythromycin Resistant	
		Number	Per cent
Staphylococcus aureus	559	50	8.9
Staphylococcus albus	79	3	3.8
Streptococcus fecalis	256	33	12.9
Streptococcus viridans	63	2	3.2
Beta Hemolytic Streptococcus	46	0	0.0
Pneumococcus	22	0	0.0
Total	1,025	88	8.6

* Strains not inhibited by 1 mcg/ml of erythromycin.

ately Resistant or Resistant strain, all cultures of Staphylococcus albus, Streptococcus viridans, Beta Hemolytic Streptococcus and Pneumococcus isolated throughout the period of investigation were found to be sensitive to erythromycin. However, some changes in the sensitivity patterns of Staphylococcus aureus and Streptococcus fecalis have apparently taken place with the passage of time. Thus, in the four consecutive periods into which this study has been divided, 6.6%, 7.5%, 10.0% and 9.6% respectively of all strains of Staphylococcus aureus recovered have proven to be either Resistant or Moderately Resistant to erythromycin. At the same time, 9.1%, 10.0%, 16.9% and 12.2% of all strains of Streptococcus fecalis isolated were similarly resistant.

It would seem at first glance that with both these microorganisms some increase in erythromycin resistance, although slight, has developed. However, when these data were subjected to statistical analysis by means of the chi square test,* significance could not be ascribed to any of these apparent changes. Considering a probability value of less than 0.05 as significant, the P value for the Staphylococcus percentage variations was 0.8; whereas that for Streptococcus fecalis was computed as 0.73.

It was therefore concluded that for the present at least, the development of increasing resistance to erythromycin by Staphylococcus aureus and Streptococcus fecalis after two years of widespread employment has been minimal and has not assumed significant clinical proportions. The vast majority of strains of both species are still susceptible to the action of this antibiotic. Whether or not the situation will change at a later date after more time has elapsed remains to be determined.

Finally, the overall incidence of erythromycin-resistant bacterial strains within the recommended effective microbial spectrum, including those classified as Moderately Resistant and Resistant, has proven to be exceedingly low during the entire two year period covered by this investigation. Of 1,025 cultures belonging to species ordinarily considered as susceptible to the action of erythromycin, 937 or 91.4% proved to be so by test.

* I am greatly indebted to Mrs. Constance Percy for the statistical analysis.

TABLE III

Source of strains of staphylococcus aureus and streptococcus fecalis found resistant to erythromycin

	Staphylococcus Aureus				Streptococcus Fecalis			
Period	I	II	III	IV	I	II	III	IV
Total Number	4	9	14	23	1	3	10	19
Source								
Wounds or drainage exudate	1	8	7	14	0	1	2	5
Urine	1	0	5	2	0	2	6	12
Blood	1	0	1	0	0	0	0	1
Chest or pleural fluid	1	0	0	0	0	0	1	0
Nose and throat culture	0	1	1	6	1	0	0	1
Peritoneal fluid	0	0	0	0	0	0	1	0
Eye	0	0	0	1	0	0	0	0

Staphylococcus aureus and Streptotoccus fecalis has provided nearly all the erythromycin-resistant strains of bacteria encountered. Table III records the clinical source from which each was isolated.

From the table it may be seen that as far as Staphylococcus aureus is concerned, infected wounds and purulent drainage was the chief source of erythromycin-resistant strains, while the urinary tract and the nose and throat, particularly in the last quarter, furnished most of the remainder. On the other hand although the great majority of erythromycin-resistant forms of Streptococcus fecalis were isolated from the urinary tract, a considerable percentage was recovered from infected wounds and purulent exudates. Of a total of 83 erythromycin-resistant strains obtained from both bacterial species during the entire two year period, 66 or approximately 80% were obtained from infected wounds, purulent exudates or from the urinary tract.

SUMMARY

In the light of the experience with the older chemotherapeutic agents where increasing bacterial resistance to their action invariably developed after a period of widespread administration, a survey was undertaken to determine whether or not a similar complication had also arisen with erythromycin in the two years since its introduction. No such development could be clearly demonstrated. With Staphylococcus albus, Streptococcus viridans, Beta Hemolytic Streptococcus and Pneumococcus, all strains, with but an occasional rare exception, proved to be sensitive in vitro to erythromycin throughout the entire period of investigation. A small percentage of strains of both Staphylococcus aureus and Streptococcus fecalis were found to be Moderately Resistant or Resistant to erythromycin and although a slight progressive increase in the percentage of erythromycin-resistant strains has been noted with the passage of time, these changes have not been proven to be statistically significant. The vast majority of strains of Staphylococcus aureus and Streptococcus fecalis isolated from clinical material are still sensitive to erythromycin.

The overall incidence of erythromycin-resistant bacterial strains, within the recommended effective spectrum, has proven to be exceedingly low for the entire two year period. Of 1,025 strains tested, 937 or 91.4% were found to be sensitive to the action of erythromycin in vitro.

The sources from which erythromycin-resistant strains of Staphylococcus aureus and Streptococcus fecalis were isolated have also been recorded. Wounds and purulent exudates provided the chief source for the former microorganism while most of the latter were recovered from the urinary tract. Together, these sites accounted for approximately 80% of all erythromycin-resistant strains of bacteria isolated during the entire two year period.

BIBLIOGRAPHY

1. Barber, M., and Rozevadowska-Dowzenko, M.: Infection by Penicillin-Resistant Staphylococci. Lancet, 2: 641, 1948.
2. Spink, W. W.: Clinical and Biological Significance of Penicillin-Resistant Staphylococci, Including Observations with Streptomycin, Aureomycin, Chloramphenicol and Terramycin. J. Lab. and Clin. Med., 37: 278, 1951.
3. Schneierson, S. S.: Changes in Bacterial Sensitivity to Aureomycin and Chloramphenicol in the Course of the Past Three Years. J. Lab. and Clin. Med., 40: 48, 1952.
4. Finland, M., and Haight, T. H.: Antibiotic Resistance of Pathogenic Staphylococci: Study of Five Hundred Strains Isolated at Boston City Hospital from October, 1951, to February, 1952. A. M. A. Arch. Int. Med., 91: 143, 1953.
5. Needham, G. M., and Nichols, D. R.: Recent Changes in Sensitivity of Micrococcus Pyogenes to Various Antibiotic Agents. J. Lab. and Clin. Med., 41: 150, 1953.
6. Haight, T. H., and Finland, M.: Resistance of Bacteria to Erythromycin. Proc. Soc. Exp. Biol. and Med., 81: 183, 1952.

SPONTANEOUS RUPTURE OF THE NORMAL ESOPHAGUS: REPORT OF A CASE WITH AN UNUSUAL CLINICAL COURSE AND PATHOLOGIC FINDINGS

FRED W. WACHTEL, M.D., AND GABRIEL GENKINS, M.D.

New York, N. Y.

The number of reported cases of spontaneous rupture of the normal esophagus has been rising markedly of late (1–5). Of even greater importance is the fact that many of the recent reports have dealt with cases in which, through early diagnosis and prompt surgery, a successful outcome was obtained. This is particularly interesting in that prior to 1936 only four reported instances of antemortem diagnosis were noted (6). Within the following decade, isolated reports of clinical diagnosis were made, and a few attempts at early surgical repair were successful. In fact, since 1946, the cure rate of numerous series ranges as high as 50%.

In all of the recent publications on this subject, the authors note that the success of management varies inversely with the length of time elapsing from onset of symptoms to definitive diagnosis. It would seem therefore that clinicians should become increasingly aware of the clinical and laboratory features of spontaneous rupture of the esophagus, since this awareness forms the main basis for diagnosis and cure.

Classically, an individual presents himself to a physician within hours after an episode of moderate to severe vomiting. The patient characteristically will be a male of middle age or older. The chief complaint is usually excruciating lower chest or upper abdominal pain, frequently associated with severe dyspnea. On examination, the patient appears seriously ill, at times in clinical shock, often severely dyspneic, tachypneic, and cyanotic. In approximately half of the cases, there is evidence of mediastinal or subcutaneous emphysema, bilateral pleural effusions, and/or hydropneumothorax. The upper abdomen is frequently held in guard, with some rigidity and maximum tenderness in the subxyphoid area.

Roentgenologic examination (without contrast material) confirms these findings and in addition *fails* to show any free air in the peritoneal cavity (7). Barium or lipiodol swallow may graphically demonstrate the exact lesion. There is a moderate to marked leukocytosis. Thoracentesis usually reveals a coffee-ground, sour-smelling fluid, containing food particles.

When reports of successfully treated cases are analyzed, one is struck with the fact that when certain clinical features are present prompt diagnosis is almost always made. These are:

1) Rapidly developing pain after an episode of vomiting;

2) Discovery of subcutaneous or mediastinal emphysema, either clinically or via the roentgenogram (seen in 40–60% of cases) (2, 7);

From the Departments of Medicine and Pathology, The Mount Sinai Hospital New York, N. Y.

3) Presence of hydro or hydropneumothorax, with typical gastric contents present on thoracentesis; and

4) The absence of other conditions, such as coronary thrombosis, gall bladder disease, perforated peptic ulcer, etc., which conceivably could have their onset with similar clinical symptoms.

Recently, a patient came under our observation with symptoms suggesting the syndrome under discussion, but in whom the diagnosis could not be substantiated. The typical clinical signs and symptoms did not develop, and the sequence of events did not take place as rapidly as is usually described. Pathognomic X-ray and laboratory evidence were also not obtained. The case is being reported and discussed in the hope that recognition of its features may further increase the salvage rate of patients with this condition.

CASE REPORT

This was the first Mount Sinai Hospital admission of an 80-year-old, retired, male, white school teacher, with complaints of severe upper abdominal and lower chest pain of six hours duration. He was known to have had a duodenal ulcer in the past, but gastro-intestinal symptoms had been well controlled and recent X-ray examination was reported to be negative. Past medical history was otherwise non-contributory.

The patient had retired without complaints on the night before admission, after a meal of lamb chops, (with no other material which could conceivably be a source for a perforating foreign body). At one AM, he was suddenly awakened by a desire for emesis, which promptly took place. The episode repeated itself within one hour. Nature of the vomitus was unknown. With the second bout of emesis, he noted the onset of a severe, dull, aching pain, constant in character, not aggravated by cough or deep respirations, non-radiating, and localized to the epigastrium and lower substernal region. The pain was not relieved by two injections of morphine sulphate, and the patient was immediately admitted to the hospital. Shortly before admission, dyspnea was first noted.

Physical examination showed a well-developed, well-nourished, elderly, white male, complaining of chest pain and in acute respiratory distress.

Blood Pressure 130/80. Pulse 132. Temperature 98.0°. Respirations 40.

Except for moderate cyanosis of the lips, examination of the head and neck was unremarkable. The respirations were rapid and somewhat labored, though of good, symmetrical excursion. The lungs were resonant to percussion, but a few scattered, medium moist rales were audible at the left base posteriorly. The heart was not enlarged, and, though rapid, the sounds were of fair quality. No significant murmurs were heard, and there was no pericardial friction rub. There was moderate voluntary resistance in the upper quadrants of the abdomen, but no localized tenderness was demonstrated. The bowel sounds were hypoactive. With the exception of nailbed cyanosis in all the extremities, the remainder of the physical examination was within normal limits.

The laboratory findings revealed a normal hemoglobin, a leukocytosis of 12,000 WBC/cubic mm, with a marked shift to the left. The sedimentation rate was 17

FIG. 1. Bedside Roentgenogram of the chest on the day of admission, revealing focal areas of atelectasis at both bases and haziness of the costophrenic sinuses.

mm/hour (Westergren). A bedside electrocardiogram revealed a regular sinus tachycardia, small Q_2, Q_3, and QAVF, but no ST segment or T wave changes as seen with acute myocardial injury.

Bedside upright chest and abdominal films showed no free air in the peritoneal cavity, but did demonstrate bilateral, focal lower lobe atelectasis, (Fig. 1) as well as bilateral blunting of the costophrenic sinuses. No pleural effusions of significant extent were seen.

The patient was given oxygen, and a Levin tube was passed to the stomach. The aspirate consisted of 450 cc of brackish, sour-smelling fluid, which was positive for HCl and occult blood. For the next sixteen hours, examination revealed no essential change, other than a temperature rise to 101°. On the next day, audible friction rubs developed on both sides of the chest. Antibiotic therapy was instituted.

During the same 24 hour period, auricular fibrillation appeared, and digoxin was given. A fluid diet was well tolerated, without any dysphagia or pain on swallowing, but the persistent lower-thoracic and upper-abdominal pain required several injections of merperidene daily. Electrocardiogram demonstrated auricular fibrillation, but no other change, and physical examination revealed some consolidation at the left lung base, in addition to the friction rubs.

The diagnosis of ruptured or perforated esophagus was suggested at this time, but the absence of pleural effusions, aberrant emphysema, and improvement in terms of lessened respiratory distress all militated against this possibility.

For the next four days, improvement continued, so that oxygen therapy was no longer required. The previously described pain was, however, still present. On the sixth day, bilateral pleural effusions were found on physical examination, more marked on the left than on the right. X-ray of the chest confirmed this impression, the picture being compatible with bilateral bronchopneumonia, with pleural effusions.

Thoracentesis obtained 600 cc of cloudy, amber fluid, with a high total leukocyte count from the left pleural cavity and similar material from the right two days later. Following these procedures, the patient felt well and was eating without difficulty. Repeat chest x-ray revealed reaccumulating bilateral effusions of moderate degree, but no other significant changes. Abdominal and lower chest distress continued however.

On the thirteenth day after admission, there developed a sudden episode of tachycardia, cyanosis, dyspnea, and very rapidly, clinical shock. Despite all attempted therapy, the patient ceased four hours after the onset of the tachycardia.

At post mortem examination the significant findings were confined to the thoracic cavity and upper gastro-intestinal tract.

The pleural cavities were both obliterated by adhesions. On the left side this process appears somewhat older with formation of an irregular cavity whose walls are a thickened and inflamed serous membrane covered with a shaggy necrotic exudate. The walls of this space are the parietal pleura laterally, an-

FIG. 2. Photograph of the posterior aspect of the mediastinum, demonstrating a probe emerging from the left posterior aspect of the esophagus and entering the abscess cavity in the left thorax.

teriorly and posteriorly and the mediastinal pleura medially. The roof is formed by the retracted left lung and pleural adhesions while the floor is the diaphragmatic pleura. The contents of the cavity are some 1500 cc of dark brown, sour-smelling, brackish fluid which is guaiac and HCl positive. A probe introduced into the intact esophagus is seen to enter this cavity. The mediastinum proper, from the level of the tracheal bifurcation to just above the diaphragm is a conglutinated mass, with the esophagus, pericardium, aorta and lungs tightly adherent to one another. Without separating these layers several tracts can be demonstrated posteriorly, where communication exists with the right pleural cavity. In this area some 200 cc of material similar to that described above are noted in a small irregular loculated space. On the right side the process appears more recent in that all adhesions are separated with greater ease (Fig. 2).

The superior portion of both thoracic cavities, particularly the left, contain several small loculated collections of slightly turbid straw-colored fluid, judged to be sympathetic effusions.

The lungs, grossly and microscopically demonstrated atelectasis, inflammatory edema and focal areas of necrotizing pneumonitis. The cause of the latter is obvious as gastric contents are also seen in the larger and smaller air passages with accompanying tracheobronchitis.

The heart and pericardium are unusual only in that the pericardial cavity is affected by the mediastinal inflammation so that a distinct pericarditis is noted. This is particularly marked at the base of the heart where some purulent exudate is found sheathing the great vessels. No evidence of significant myocardial damage was noted grossly or microscopically (Fig. 3).

The upper half of the esophagus is normal in all respects. The lower third is

Fig. 3. Photograph of the inflammatory exudate, which has extended from the mediastinum to involve the pericardium and root of the great vessels.

FIG. 4. Photograph of the esophagus, opened posteriorly, with a probe entering the small linear rent 9½ cms from the cardia, traversing the mediastinum, and entering the left thorax.

slightly reddened but lined with an intact smooth mucosa. Some 9½ cm from the cardio-esophageal junction, in the left posterior aspect of the esophagus there is a small ½ cm linear tear in the mucosa. The area surrounding this lesion demonstrates some necrosis and undermining of the mucosa. A probe passed into this defect is noted to communicate with the left-sided pleural cavity. No gross or microscopic abnormality of the esophageal mucosa (chronic inflammation, ectopic gastric mucosa, etc.) could be demonstrated (Fig. 4).

The stomach was moderately dilated and distinct pyloric stenosis was noted. A deep punched out ulcer crater is seen in the duodenum, penetrating into the head of the pancreas and forming a firm inflammatory mass. The walls and floor of this ulcer consist of thick scar tissue which involves the duodenal bulb and pylorus. There is, however, no edema or hyperemia associated with the ulcer complex.

The remainder of the examination was non-contributory.

DISCUSSION

There are no evidences in the clinical history and post-mortem findings to indicate any pre-existing pathology of the esophagus or mediastinum. An ingested foreign body, such as a meat or fish bone, was not encountered at necropsy. Furthermore, this patient had not been subjected to endoscopy prior to the development of his symptoms. This case then is an example of spontaneous rupture of the normal esophagus.

What is it then that causes the normal esophagus to rupture? Most authorities believe that the principal factor in producing this tear is a rise in the intraluminal

pressure of the organ past its bursting point. Review of case histories of patients with this syndrome points out the fact that 85% of these individuals were retching and/or vomiting immediately prior to onset of symptoms (8). The remaining 15% were straining at stool, were in the labor of childbirth, or had suffered trauma to the lower chest or abdomen. It is apparent that all of these acts are accompanied by marked increases in intra-abdominal pressure. In the case of vomiting, this pressure is transmitted via the gastric contents to the esophagus. The acts of retching and vomiting are usually well coordinated ones and, in themselves, benign occurrences. The experimental production of esophageal rupture in the intact human cadaver requires about 3.7 pounds per square inch of intraluminal pressure (9). When pressures exceeding these limits coincide with incoordinate muscular action, rupture of the esophagus may take place. For example, spontaneous rupture has been observed in patients suffering from brain tumors, inebriation, and violent motion sickness. It is not unreasonable to assume that some dysfunction in reflex neuromuscular activity exists in such patients (10).

Further proof of this is demonstrated by comparing clinical lesions, observed in the operating room and autopsy table, with those produced artificially in the laboratory. As observed clinically, the tear in the esophagus is usually located just proximal to the cardio-esophageal junction. It is longitudinal, from one to seven centimeters in length, most often on the left side posteriorly, occasionally on the right, and very rarely higher up. As confirmed in 48 of 53 cases, reviewed by Cram, Brant, and Preston, the tear was located supradiaphragmatically (2). By the use of varying techniques, several investigators have subjected the esophagi of fresh human cadavers to intraluminal pressures great enough to burst them (9, 11, 12). The perforations produced appeared similar as to position, length, and direction to those seen in patients who suffered this catastrophe spontaneously. Bodi tied off the esophagi of fresh cadavers superiorly and just below the cardio-esophageal junction. With as little anatomical distortion as possible, he then injected barium into the esophagus under fluoroscopic control. He observed a constant herniation of the lower left lateral portion of the esophagus just prior to actual rupture (13).

This lowermost region of the esophagus is an anatomically weak point for several reasons. There is little external support for the organ here, and major blood vessels and nerves enter in this area. The muscular coats have become more poorly defined, and a distinct spiral layer is often absent. There is also angulation of the organ near the diaphragm.

Many authors maintain that rupture of the normal esophagus does not occur (14–18). They postulate pre-existing esophageal disease, such as the cases of esophagitis associated with peptic or gastric ulcer with high acidity, as reported by Winkelstein, Wolf, Som, and Marshak (19). In others, evidence of previous esophageal disease, though not clearly demonstrated, was assumed. In these cases also, the site of rupture was the typical lower esophageal location.

Certain aspects of this particular case are therefore worthy of further consideration. The most important is that the site of the perforation in the esophagus was

located in the middle third of the organ and not in the commonly observed lower several centimeters. This aberration has been reported previously, but it is an extremely rare occurrence, both clinically and experimentally. Pathologically, no evidence of previous esophageal disease (especially of the segment involved by the perforation) was noted. However, this unusual site of the perforation might account for the protracted course of the illness in this man. Under the usual circumstances, once the esophagus ruptures, the mediastinum is contaminated by gastric contents. Because of the typical proximity of the tear to the cardiac orifice of the stomach, continued gastric regurgitation allows large volumes of fluid to collect in the mediastinal space. This may then secondarily rupture into the left pleural cavity. Volumes of one to two liters have been found in this cavity within hours after onset of symptoms (20). The high location of rupture in this patient probably prevented marked mediastinal fluid collection.

However, enough fluid entered initially to elicit a marked inflammatory response, with the development of adhesive mediastinitis, sympathetic pneumonitis, and pleural effusion during the ensuing several days. Indeed, examination of the pleural effusion on the sixth and eighth day after onset gave no indication that the fluid was gastric in origin. The inherent vitality of the patient and supportive therapy maintained him for thirteen days. We feel that only during the terminal event were both pleural cavities contaminated with gastric content. This fact is borne out by the pathological findings.

SUMMARY

A case of spontaneous rupture of the normal esophagus is presented. The usual clinical and pathophysiological features of this condition are reviewed. Suggested reasons for the atypical course in this patient are presented.

We are indebted to Dr. S. H. Averbuck for permission to use the case material.

BIBLIOGRAPHY

1. Brock, W., and Wever, G.: Spontaneous Perforation of the Esophagus. California M., 80: 45, 1954.
2. Cram, R. W., Brant, D. J., and Preston, F. T.: Two Cases of Spontaneous Rupture of Oesophagus. Canad. M. Assoc. J., 71: 250. 1954.
3. Irvin, C. W., and Bunch, G. H.: Spontaneous Rupture of the Esophagus With a Note on Tissue Necrosis from Norepinephrine. Am. J. Med., 17: 571, 1954.
4. Alt, R. E., Bixby, F. E., and Rowell, R. J.: Spontaneous Rupture of the Normal Esophagus. N. England J. M., 249: 1060, 1953.
5. Migliaccio, A. V., Forsythe, T., and Cavanaugh, C.: Spontaneous Rupture of the Esophagus; Report of a Case Occurring Five Years After Gastric Resection. Surgery, 36: 826, 1954.
6. Eliason, E. L., and Welty, R. F.: Spontaneous Rupture of the Esophagus. Surg. Gynec. Obst., 83: 234, 1946.
7. Priviteri, C. A., and Gay, B. B.: Spontaneous Rupture of the Esophagus. Radiology, 57: 48, 1951.
8. Ware, G. W., Shnider, B. I., and Davis, E. W.: Spontaneous Rupture of Esophagus. A.M.A. Arch. Surg., 65: 723, 1952.

9. Kinsella, T. J., Morse, R. W., and Hertzog, A. J.: Spontaneous Rupture of the Esophagus. J. Thorac. Surg., 17: 613, 1948.
10. Fincher, E. F., and Swanson, H. S.: Esophageal Rupture Complicating Craniotomy—Symptom Complex and Proposed Surgical Treatment. Ann. Surg., 129: 619, 1949.
11. MacKenzie, M., *Diseases of Nose and Throat*, Vol. 2, 1884, Blakiston Company, Philadelphia, p. 169.
12. Mackler, S. A.: Spontaneous Rupture of the Esophagus. Surg. Gynec. Obst., 95: 345, 1952.
13. Bodi, T., Fangin, H., and Forsythe, T.: Spontaneous Rupture of the Esophagus. Ann. Int. Med., 41: 553, 1954.
14. Williams, T. H., and Boyd, W.: Spontaneous Rupture of the Oesophagus. Surg. Gynec. Obst., 42: 57, 1926.
15. Anderson, R. L.: Rupture of the Esophagus. J. Thorac. Surg., 24: 369, 1952.
16. Wangensteen, O. H. in discussion of Anderson's paper. J. Thorac. Surg., 24: 369, 1952.
17. Samson, P. C.: Postemetic Rupture of the Esophagus. Surg. Gynec. Obst., 93: 221, 1951.
18. Ferguson, D. J., Sanchez-Palomera, E., Sako, Y., Clatworthy, H. W., Jr., Toon, R. W., and Wangensteen, O. H.: Studies on Experimental Esophagitis. Surgery, 28: 1022, 1950.
19. Winkelstein, A., Wolf, B. S., Som, M. L., and Marshak, R. H.: Peptic Esophagitis with Duodenal or Gastric Ulcer. J. Am. Med. Assoc., 154: 885, 1954.
20. Bugden, W. F.: Spontaneous Rupture of Thoracic Esophagus, Its Surgical Cure. Am. J. Surg., 83: 225, 1952.

DIABETES INSIPIDUS: A DISCUSSION, INCLUDING A REEXAMINATION OF THE SITE AND MODE OF ACTION OF THE ANTIDIURETIC HORMONE[1]

ABRAHAM G. WHITE, M.D.

New York, N. Y.

Beset, on the one hand, by insensate, burning, unquenchable thirst, and on the other, by outpouring of water from the body, the patient with diabetes insipidus is almost an atavism, a throw-back to a primeval, ancestral marine dweller dependent upon intimate contact with the surrounding water for its very existence, and doomed to dry destruction when separated from its aqueous habitat.

In essence, this clinical syndrome, characterized by polydipsia, polyuria, and the excretion of urine with low specific gravity, represents a disturbance in the regulation of body water exchange by the neurohypophysial antidiuretic hormone (1). It is the purpose of this report to review briefly 219 cases of diabetes insipidus, including 14 from this hospital, with reference to the etiology, incidence, diagnosis, and treatment of this syndrome, and to present a clinicophysiological correlation between the signs and symptoms and underlying physiological mechanisms. Observed clinical and physiological data are used to reexamine the question of where and how the antidiuretic hormone acts.

ETIOLOGY

Table I presents a classification of 205 cases of diabetes insipidus collected by Rowntree (2), Jones (3), and Fink (4), to which are added 14 from this hospital. Since the series presented by Fink is based exclusively on postmortem reports, it distorts the etiologic incidence as detected clinically; nevertheless, it is valuable because of the large number of cases represented. 51 cases (23.3%) were of the primary or idiopathic variety in which no underlying disease process could be diagnosed clinically, while in 168 (76.7%) the syndrome of diabetes insipidus was secondary to some detectable disease.

Of these secondary cases, 95 (43.4% of the total) had their origin in cerebral and pituitary neoplasms. Among the 5 patients with such lesions in our series, 2 were secondary to metastatic infiltration of the posterior lobe of the pituitary from a primary carcinoma of the breast, 2 from a primary bronchogenic carcinoma, and 1 to invasion by a craniopharyngioma. In this respect, the onset of diabetes insipidus in a patient with a known neoplasm (whether or not surgical removal has been effected) is practically pathognomonic of metastatic involvement of the posterior lobe of the pituitary.

Most of the remaining cases may be ascribed to disruption of the supraopticohypophysial tract by syphilis, encephalitis, tuberculosis, trauma, and

From the Department of Medicine, The Mount Sinai Hospital, New York, N. Y.

[1] This work was supported by a grant-in-aid from the National Heart Institute, National Institutes of Health, U.S.P.H.S.

TABLE I

Etiology of diabetes insipidus in 219 cases, including 14 from this hospital

Classification	A*	B*	C*	D*	Total	%
I) *Primary or idiopathic*	36	8	0	7	51	23.3
II) *Secondary or symptomatic*	20	34	107	7	168	76.7
Secondary to cerebral & pituitary neoplasm	(9)	(13)	(68)	(5)	(95)	(43.4)
Tuberculosis			(5)		(5)	(2.3)
Syphilis	(7)	(3)	(14)		(24)	(10.9)
Encephalitis	(2)	(7)	(9)		(18)	(8.2)
Trauma	(2)	(3)	(11)	(1)	(17)	(7.8)
Hand-Schüller-Christian		(4)		(1)	(5)	(2.3)
Hypothalamic damage, cause unknown		(1)			(1)	(0.5)
Cerebrovascular accident		(3)			(3)	(1.3)
Total	56	42	107	14	219	100

* A. Rowntree (ref. 2); B. Jones (ref. 3); C. Fink (ref. 4); D. Mount Sinai Hospital series.

Hand-Schüller-Christian disease. Other, less common, causes include cerebrovascular hemorrhage in the region of the hypothalamus. Spillane (5) has described four cases of pulmonary disease associated with diabetes insipidus; the diagnoses in these instances included Boeck's sarcoidosis, xanthomatosis, and eosinophilic granuloma.

Although not among the cases listed in Table I, two types of hereditary diabetes insipidus have been described. First, a Pitressin-resistant type, showing a sex-linked recessive pattern of inheritance and occurring in males while transmitted by females, has been characterized in several reports (6–9). This type of "nephrogenic" or "congenital" diabetes insipidus appears to be caused by an apparently inborn defect in renal tubular metabolism. As a result of this tubular cell defect there is diminished reabsorption of water in the distal segment of the nephron, which is unresponsive to extracts of the posterior lobe of the pituitary. Such patients exhibit the typical polyuria, with consequent dehydration and polydipsia, and tend to be febrile during the phase of dehydration. The second type of hereditary diabetes insipidus has been reviewed by Pender and Fraser (10), and appears to follow a pattern of inheritance that fits the expectation for a simple Mendelian dominant factor, with approximately equal proportions of affected males and females. In contrast to the "nephrogenic" type, the physiological defect in this group of cases appears to lie in deficient production of the antidiuretic hormone rather than in any diminished responsiveness of the tubules to the hormone. As a result, in patients of this group, Pitressin is effective in reducing the urinary output to within normal range.

INCIDENCE

Diabetes insipidus is a rare syndrome. Thus, Rowntree collected 56 cases out of a total patient registration of 428,000 during a 15-year period at the Mayo

TABLE II

Age at time of onset of diabetes insipidus

Age (Decades)	A*	B*	C*	Total	%
First	3	17	1	21	18.8
Second	5	6	2	13	11.6
Third	15	7	2	24	21.5
Fourth	20	5	1	26	23.0
Fifth	10	5	2	17	15.2
Sixth	2	2	5	9	8.1
Seventh	1		1	2	1.8
Total	56	42	14	112	100

* Rowntree (ref. 2); B. Jones (ref. 3); C. Mount Sinai Hospital series.

Clinic, a frequency of 1 per 7600 cases (2). In a compilation from various sources he found an incidence of 160 cases of diabetes insipidus per 1,000,000 patients.

Table II summarizes the age of onset in 112 patients with diabetes insipidus. Approximately three-fourths of the cases had their origin in the first four decades of life, emphasizing that this syndrome is one of youth rather than of old age.

With respect to the sex distribution of this condition, there were 30 male and 26 female patients in the Mayo Clinic series, with 8 males and 6 females in the series from this hospital, totaling 38 males and 32 females.

SIGNS AND SYMPTOMS

The classic triad of diabetes insipidus is that of polydipsia, polyuria and the excretion of urine with low specific gravity. Other signs and symptoms depend upon: (a) the underlying disease, where one exists, and (b) the supervention of dehydration that occurs in the untreated patient when the intake of fluids does not keep pace with the output.

The thirst occurring in diabetes insipidus is often overpowering, and has almost a parasthetic quality of "burning." It is not relieved immediately by drinking water, so that the patient drinks again and again with a resultant "bloated" feeling leading to anorexia and marked fatigue. Dehydration, when severe, may lead to contraction of the extracellular and plasma compartments, and ultimately to vasomotor collapse.

CLINICOPHYSIOLOGICAL CORRELATION (PATHOLOGIC PHYSIOLOGY)

A. Polydipsia

Whether the thirst in diabetes insipidus is primary, or secondary to polyuria long has been a point of contention. This subject has been reviewed by Holmes and Gregersen (11), among others. On the basis of the rate of salivary flow in dehydrated and hydrated cases of diabetes insipidus, and the observations of Richter (12) on rats with experimental diabetes insipidus in whom polydipsia ceased following the ligation of both ureters, these authors conclude that poly-

dipsia is secondary to polyuria. Thus, the origin of polydipsia in diabetes insipidus may be schematized as follows:

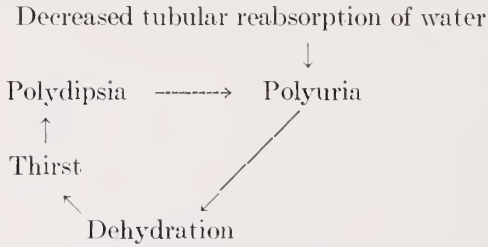

This concept, which is accepted generally, does not exclude the possibility that polydipsia may occur as a primary symptom following trauma or disease of the central nervous system. In fact, the author recently saw a young college student who developed paroxysmal polydipsia approximately 3 months after a head injury sustained in an automobile accident. The polydipsia was associated with polyuria, leading to a presumptive diagnosis of diabetes insipidus on a traumatic basis. However, a detailed history indicated that the polyuria was secondary to the polydipsia, and a random urine specimen had a specific gravity of 1.016, virtually excluding the diagnosis of true diabetes insipidus. Over a period of months the polydipsia subsided gradually.

B. Polyuria (renal function in diabetes insipidus)

1. *Renal hemodynamics.* a. *Clinical diabetes insipidus.* As seen in Table III, the glomerular filtration rate ranges from low to normal values, while the renal plasma flow tends to be somewhat low (13–18). Differences in the state of hydration may account, in part, for some of these variations in the renal hemodynamics (17).

b. *Experimental diabetes insipidus.* The mean glomerular filtration rate of dogs with diabetes insipidus is significantly lower (about one-half) than normal, with the filtration fraction the same as in normal dogs, indicating that the renal plasma flow is diminished proportionately (19–21).

2. *Excretion of water.* The curve of water diuresis following hydration of the patient with diabetes insipidus is blunted and does not show the peak seen nor-

TABLE III

Renal hemodynamics in clinical diabetes insipidus

No. of Pts.	Glomerular Filtration Rate	Renal Plasma Flow	Reference
	cc/min	*cc/min*	
7	93.0–143.0	250–760	13
1	106	450	14
2	104.2*	498*	15
	54.5*	325*	
1	53.4	298	16
4	37.5–142.0	—	17, 18

* Values are corrected to surface area of 1.73 M^2.

mally approximately 90 minutes following the administration of fluids (18). The twenty-four hour excretion of water may represent only 5 per cent of the daily filtered load (18). Rarely has there been a report of approximately 15 per cent of the filtered load of water being excreted per 24 hours, an amount that would be expected on the basis of release of the "facultative" reabsorption of water from control by the neurohypophysial antidiuretic hormone (22).

3. *The bearing of studies dealing with osmotic diuresis on the site and mode of action of the antidiuretic hormone.* Brodsky and associates have discussed osmotic diuresis as a measurement of renal function in man (23). Of interest is the fact that osmotic loading in hydropenic man causes increments of urine flow at a tonicity of 477–953 mOs./L (23). However, both in clinical and experimental diabetes insipidus osmotic loading, no matter what the amount or type of solute used, causes increments of urine flow at a tonicity of 150–185 mOs./L (15–17, 19, 24); this is true, both of short-term, acute, experiments, as well as of metabolic experiments lasting days. Furthermore, calculations show that osmotic diuresis superimposed on an already existing diuresis in the dog (25) may cause increments of urine flow at a tonicity of 145.5 mOs./L. The slope of the line relating twenty-four hour urine output to urinary osmotic load in patients with chronic neprhitis is 280 mOs./L (18a).

These data are interpreted here as suggesting that the antidiuretic hormone may regulate the osmotic activity of solute in the renal (proximal?) tubule. Thus, when the hormone activity is deficient, as in diabetes insipidus or during water diuresis in the normal, the tubular permeability to water is altered so that non-reabsorbed solute does not carry water with it in isotonic (or greater) concentrations, but rather in the ratio of 1 l./approx. 150 mOs. This suggested action of the antidiuretic hormone on the osmotic activity of solute does not exclude the hitherto postulated action on the distal tubule (22), but may be considered as an additional mechanism in the formation of dilute urine.

DIAGNOSIS

The diagnosis of diabetes insipidus depends upon a systematic study including:

1. *History and physical examination.* A detailed inquiry should be made into the temporal relation between the onset of polydipsia and polyuria. As indicated previously, polyuria usually precedes polydipsia in diabetes insipidus. Renal disease should be excluded because of the polyuria and inability to excrete urine with high specific gravity that may occur, particularly in chronic nephritis (18). Possible etiologic disease processes (as suggested in Table I) should be sought for.

2. *Stimulation of secretion of endogenous antidiuretic hormone by dehydration.* The withdrawal of all fluids and food for periods up to 16 or more hours, the exact duration depending upon the patient's ability to withstand such deprivation, is a simple diagnostic procedure. The patient is weighed both at the beginning (after the evening meal) and at the termination of this dehydration. All urine excreted should be collected and measured, but at the end of the test period the patient is asked to void a fresh specimen, the specific gravity of which

presumably provides a measure of the maximal urinary concentrating power of the patient's kidneys.

Under these conditions, the patient with diabetes insipidus may excrete from 2 to 3 or more liters of urine in 16 hours, suffer a weight loss of 4 or more pounds, and yield urine with a maximal specific gravity between 1.000 and 1.006, although specific gravities as high as 1.014 have been reported in apparently well-documented cases of diabetes insipidus (26).

3. *Stimulation of secretion of endogenous antidiuretic hormone in response to elevation of plasma osmotic pressure by means of intravenously administered hypertonic saline (Hickey-Hare Test).* Originally described by Hickey and Hare (27), and modified by Carter and Robbins (28), the first half of this procedure entails hydrating the patient over a period of 45 to 60 minutes either by the oral administration of 20 ml water/kg. body weight or by infusing 5% glucose in water intravenously at 10 cc. per minute (the method employed in this laboratory). A catheter is introduced into the bladder at zero time and urine is collected in 15-minute periods. When the urine flow exceeds 5 ml per minute for at least 2 collection periods, the intravenous infusion of 2.5% sodum chloride is begun and continued for 45 minutes at the rate of 0.25 cc./kg./min. The normal response is characterized by a progressive decrease in the rate of urine flow that is noted in the first collection period following onset of the saline infusion and continues into the first post-saline period. In contrast, in the patient with diabetes insipidus, not only may there be no decrease in the rate of urinary flow during the infusion of saline, but an actual increase. Somewhat intermediate responses between these two antipodes have been reported, and ascribed to varying degrees of severity of diabetes insipidus (26).

4. *Stimulation of secretion of endogenous antidiuretic hormone in response to stimulation of the supraoptic nuclei by the intravenous administration of nicotine.* As described by Cates and Garrod (26), fluid and tobacco are withheld from the patient for at least 4 hours, following which hydration and catheterization are carried out as described under the hypertonic saline test. If at 60 minutes, the rate of urine flow exceeds 5 ml./min., nicotine is given intravenously (1 mgm. to non-smokers and 3 mgm. to smokers), and urine is collected in 5 to 10 minute periods. If antidiuresis ensues, indicating absence of diabetes insipidus, urine is collected at short intervals until a maximum rate of flow returns. None of seven patients with diabetes insipidus in their series responded normally to 1 or 3 mgm nicotine, but when they were given a large injection (up to 6 mgm.) of nicotine, five of the seven showed a good antidiuretic response. The hypothetical explanation for this phenomenon offered by these authors is that the lesion causing diabetes insipidus was incomplete, and that a potent stimulus could result in the secretion of antidiuretic hormone. In considering the use of this procedure, it should be noted that in 30 of 32 tests performed, the nicotine produced side-effects, including "dizziness, tinglings, hyperpnea, sweating, marked hyperpnea, construction in chest, and in distress." The preponderant incidence of such adverse reactions appears to render unsuitable and undesirable the use of nicotine as a routine procedure, especially when the information provided is obtainable by the diagnostic measures outlined previously.

DIFFERENTIAL DIAGNOSIS

The polyuria of diabetes insipidus must be differentiated from that seen in diabetes mellitus, chronic nephritis and psychogenic polydipsia. Pender and Fraser (10) indicate that Addisonian crisis occurring in young infants also may present a diagnostic problem in this respect.

While the exclusion of diabetes mellitus and chronic nephritis is fairly simple, that of psychogenic polydipsia may provide some difficulty. In patients suffering from compulsive drinking, the history usually will indicate that the onset of polydipsia precedes that of polyuria. It often is difficult to determine the maximal concentration of urine in response to dehydration because these patients may suffer intensely from deprivation of water. Thus, the intravenous administration of hypertonic saline serves as the most reliable diagnostic measure, since in these patients the rate of urine flow decreases promptly and normally in response to elevation of plasma osmotic pressure.

TREATMENT OF CLINICAL DIABETES INSIPIDUS

1. *Exogenous Antidiuretic Hormone.* With few exceptions, such as patients suffering from "nephrogenic" or "congenital" diabetes insipidus, most cases respond to preparations of the posterior lobe of the pituitary gland containing the antidiuretic hormone, and this specific treatment is the one of choice.

Once the diagnosis is established, treatment may be begun with aqueous Pitressin (20 units/cc) administered intramuscularly or subcutaneously in doses of 0.5 cc. every 8 hours. The frequency and dose are determined by the patient's response to the initial doses. Doses of 1.0 cc. every 4 to 6 hours may be required. A less satisfactory method of administering aqueous Pitressin consists of inserting nasally a cotton pledget with the correct dose, but absorption from the nasal mucosa seems to be somewhat variable and unpredictable.

Since the effect of aqueous Pitressin is of relatively short duration, Pitressin Tannate in Oil (5 units/cc.) may be administered intramuscularly in doses of 0.3 to 1.0 cc. The effect of one injection may last up to 96 hours, so that the frequency of administration is determined by the patient's response.

Where it is especially desirable to avoid injections, as in children suffering from diabetes insipidus, the nasal application of posterior lobe powder may be tried. The powder is weighed out in doses of 40 mgm., to begin with, and this amount is blown into the nose with an insufflator four times a day. The frequency and size of further doses are determined by the patient's response. The interval between applications may be lengthened or shortened and the size of the dose may be decreased or increased in steps of 10 mgm.

2. *Reduction of urinary solute load.* Since, as shown previously, the rate of urinary flow in diabetes insipidus is proportional to the urinary osmotic load (the largest portion of which consists of urea and salt), and adjuvant treatment of this syndrome consists of limiting the daily intake of salt and protein. In milder cases, such limitation may be sufficient to reduce the daily output of urine to within the normal range.

3. *Other hormonal influences.* The induction of hypothyroidism to alleviate

diabetes insipidus does not appear to be reasonable, because the discomfort and hazards of myxedema would appear to outweigh those of the administration of Pitressin.

PROGNOSIS

The prognosis in diabetes insipidus primarily is that of the underlying disease, where one exists. The idiopathic form of this syndrome is compatible with a normal life expectancy. Not all patients will continue self-treatment with Pitressin for the rest of their lives; for psychological reasons some will prefer the discomforts of the polydipsia and polyuria to those of the self-administration of the hormone, especially if the diabetes insipidus is mild or moderate in intensity. In this respect, it is of interest that only 5 of the 56 patients in Rowntree's series (2) were continuing systematic treatment with daily hypodermic use of pituitary extract. Eight patients were known to be dead (4 from tumors, 1 from meningoencephalitis and suprarenal atrophy). Three patients were symptomatically cured; all 3 had lumbar punctures, although in no instance did marked improvement follow immediately on spinal drainage. Eight patients were definitely improved, while in 9 the condition was unchanged.

SUMMARY AND CONCLUSIONS

Two hundred and nineteen cases of clinical diabetes, including 14 from this hospital, are summarized with respect to their etiology and other clinical features. Diagnostic measures and the treatment of this syndrome are discussed, while physiological mechanisms underlying the signs and symptoms are reviewed. Finally, observed clinical and physiological data are used to reexamine the question of the site and mode of action of the neurohypophysial antidiuretic hormone. It is suggested that the hormone may act not only on the distal tubule, as postulated hitherto, but perhaps on the proximal tubule of the nephron by altering the osmotic activity of solutes so that they carry along with them at least twice as much water as they do during osmotic diuresis in hydropenic man.

BIBLIOGRAPHY

1. Fisher, C., Ingram, W. R., and Ransom, S. W.: Diabetes Insipidus and the Neurohormonal Control of Water Balance. Ann. Arbor, 1938. Edwards Brothers, Inc.
2. Rowntree, L. G.: Studies in Diabetes Insipidus. J. A. M. A., 83: 399, 1924.
3. Jones, G. M.: Diabetes Insipidus. Clinical observations in forty-two cases. Arch. Int. Med., 74: 81, 1944.
4. Fink, E. B.: Diabetes Insipidus: A Clinical Review and Analysis of Necropsy Reports. Arch. Pathol., 6: 102, 1928.
5. Spillane, J. D.: Four Cases of Diabetes Insipidus and Pulmonary Disease. Thorax, 7: 134, 1952.
6. Waring, A. J., Kajdi, L., and Tappan, V.: A Congenital Defect of Water Metabolism. Am. J. Dis. Child., 69: 323, 1945.
7. Williams, R. H.: Nephrogenic Diabetes Insipidus Occurring in Males and Transmitted by Females. J. Clin. Investigation, 25: 937, 1946.
8. Dancis, J., Birmingham, J. R., and Leslie, S. H.: Congenital Diabetes Insipidus Resistant to Treatment with Pitressin. Am. J. Dis. Child., 75: 316, 1948.

9. Weller, C. G., Elliott, W., and Gusman, A. R.: Hereditary Diabetes Insipidus: Unusual Urinary Tract Changes. J. Urol., 64: 716, 1950.
10. Pender, C. B. and Fraser, F. C.: Dominant Inheritance of Diabetes Insipidus: A Family Study. Pediatrics, 11: 246, 1953.
11. Holmes, J. H. and Gregersen, M. I.: Origin of Thirst in Diabetes Insipidus. Am. Jour. Med., 4: 503, 1948.
12. Richter, C. P. and Eckert, J. F.: Further Evidence for Primacy of Polyuria in Diabetes Insipidus. Am. J. Physiol., 113: 578, 1935.
13. Winer, N. J.: Renal Function in Diabetes Insipidus. Arch. Int. Med. 70: 61, 1942.
14. Williams, R. H., and Henry, C.: Nephrogenic Diabetes Insipidus: Transmitted by Females and Appearing in Males. Ann. Int. Med., 27: 84, 1947.
15. Brodsky, W. A. and Rapoport, S.: The Mechanism of Polyuria of Diabetes Insipidus in Man. The Effect of Osmotic Loading. J. Clin. Invest., 30: 282, 1951.
16. Leaf, A., Mamby, A. R., Rasmussen, H., and Marasco, J. P.: Some Hormonal Aspects of Water Excretion in Man. J. Clin. Invest., 31: 914, 1952.
17. White, A. G.: Diabetes Insipidus Associated with Edema. New Eng. J. Med., 250: 633, 1954.
18. White, A. G., Kurtz, M., and Rubin, G.: Comparative Renal Responses to Water and the Antidiuretic Hormone in Diabetes Insipidus and in Chronic Renal Disease. Am. J. Med., 16: 220, 1954.
18a. White, A. G. and Rubin, G.: Physiological Mechanisms Regulating Rate of Urinary Flow in Renal Disease. Proc. Soc. Exp. Biol. and Med., 86: 30, 1954.
19. Brodsky, W. A., Austing, M. E., Moxley, T. L., and Grubbs, T. A.: Composition of Excreted Solutes in Experimental Diabetes Insipidus; Mechanism of Urinary Dilution. Am. J. Physiol., 174: 448, 1953.
20. White, H. L. and Heinbecker, P.: Observations on Creatinine and Urea Clearances, on Responses to Water Ingestion and on Concentrating Power of Kidneys in Normal, Diabetes Insipidus and Hypophysectomized Dogs. Am. J. Physiol., 123: 566, 1938.
21. Handley, C. A. and Keller, A. D.: Changes in Renal Functions Associated with Diabetes Insipidus Precipitated by Anterior Hypothalamic Lesions. Am. J. Physiol., 160: 321, 1950.
22. Smith, H. W.: The Kidney: Structure and Function in Health and Disease. New York, 1951. Oxford Univ. Press.
23. Brodsky, W. A., Rapoport, S., Graubarth, H. N., and Levkoff, A. H.: Osmotic Diuresis as a Measurement of Renal Function in Man. J. Appl. Physiol., 5: 62, 1952.
24. Beaser, S. B.: Renal Excretory Function and Diet in Diabetes Insipidus, Am. J. M. Sc., 213: 441, 1947.
25. Wesson, L. G. and Anslow, W. P.: Effect of Osmotic and Mercurial Diuresis on Simultaneous Water Diuresis. Am. Journ. Physiol., 170: 255, 1952.
26. Cates, J. E. and Garrod, O.: The Effect of Nicotine on Urinary Flow in Diabetes Insipidus. Clin. Sc., 10: 145, 1951.
27. Hickey, R. C. and Hare, K.: Renal Excretion of Chloride and Water in Diabetes Insipidus. J. Clin. Investigation, 23: 768, 1944.
28. Carter, A. C. and Robbins, J.: Use of Hypertonic Saline Infusions in Differential Diagnosis of Diabetes Insipidus and Psychogenic Polydipsia. J. Clin. Endocrinol, 7: 753, 1947.

IDIOPATHIC CHRONIC ULCERATIVE COLITIS AND AMYLOIDOSIS

ISIDORE MANDELBAUM, M.D.,* AND DAVID BRYK, M.D.

Since the description of chronic ulcerative colitis as a pathological entity in 1875 by Wilks and Moxon (1), there have been only rare instances in which this disease has been associated with amyloidosis. The first case of amyloidosis and chronic ulcerative colitis was described by Moschcowitz in 1936 (2); and in the past twenty years, three additional cases have been reported: by Mallory in 1947 (3), Jensen et al. in 1950 (4), and Frenkel and Groen in 1954 (5).

Recently, a postmortem examination of a 48 year old female revealed chronic ulcerative colitis and amyloidosis. This prompted a review of the 107 cases of chronic ulcerative colitis autopsied at The Mount Sinai Hospital in the last twenty years. The rarity of the association of the two pathological conditions was further emphasized by the discovery of only one additional case.

CASE REPORTS

Case No. 1, J. N., MSH #498,498. This was the first Mount Sinai Hospital admission of a 28 year old unmarried man who entered because of an exacerbation of severe diarrhea which he had had intermittently for ten years. In 1933, because of diarrhea and a productive cough, the diagnosis of tuberculous enteritis was made at another hospital. Chest x-rays were negative. Several months later, admission to a second hospital was necessary due to a recrudescence of abdominal pain and bloody diarrhea. Barium enema showed advanced ulcerative colitis of the entire colon; and sigmoidoscopy revealed pseudo-polypi. After nearly two years in that hospital because of abdominal pain and diarrhea, a pararectal abscess developed, was drained surgically, and healed. After drainage of the abscess, there was general improvement in the patient's condition with progressive weight gain. From 1935 until November, 1942, there were intermittent exacerbations of diarrhea usually associated with upper respiratory infections. Two weeks prior to admission to The Mount Sinai Hospital, the patient experienced severe abdominal cramps and diarrhea (4–8 bowel movements per day) during an attack of "grippe". Vomiting occurred each of the fourteen days prior to hospitalization, and there was a twelve pound weight loss.

Physical examination revealed an acutely and chronically ill male. The temperature was 98.6°. There was marked cheilosis, and the tongue was beefy red. The abdomen was soft and non-tender; the fingers and toes were clubbed. The perianal skin was indurated, and two perianal fistulae were present. The urine showed 1+ albumin with occasional granular casts; the hemoglobin was 75%; the white blood count was 23,000 per cubic millimeter with 87% polys. The blood urea nitrogen and blood sugar were within normal limits and the total protein was 4.0 gms.% with an A/G ratio of 2.3/1.7. There were irregular

From the Department of Pathology of The Mount Sinai Hospital, New Yory, N. Y.
* Fellow of the Dazian Foundation for Medical Research.

spikes of temperature up to 102.8° and bloody diarrhea of 10–15 stools per day. Despite numerous small blood transfusions and vitamins, the patient's condition deteriorated. Several days prior to death, he complained of striking left lower chest pain and abdominal distention was noted. Diffuse abdominal tenderness developed, following which the patient died on December 9, 1942, eleven days after admission.

Postmortem Findings: Two perianal fistulae were found. The anterior fistula entered the rectum, while the posterior fistula ended blindly in the perirectal tissue. The small intestinal loops were distended and matted together by a dull, fibrinous exudate. A small amount of fecal material was present in the peritoneal cavity, and a pinpoint perforation of the proximal jejunum was found. The heart and lungs were not remarkable on gross examination. The liver was large and weighed 2500 grams. It had a smooth surface, was reddish-yellow in color and was of firm consistency. On cut section, yellow streaks were present throughout the parenchyma. The spleen weighed 180 grams, and there was an increased resistance to sectioning. The cut surface was glossy with grayish opalescent areas. The pancreas was unremarkable, and the adrenal gland was firm in consistency. The kidneys weighed 260 grams together, and the cut section showed a yellowish-red mottling. The upper gastrointestinal tract was not remarkable. In the mid-jejunum and ileum, focal ulcerations were seen. One jejunal ulceration perforated into the peritoneal cavity. The mucosa between the ulcerations was thick and showed a yellowish-gray network. The colon was foreshortened and measured 60 cm. to the anus. The lumen was narrowed, and the mucosa was thin, pale, and atrophic. There were linear interconnecting mucosal scars. A polypoid mucosal projection was present in the descending colon. The rectal mucosa was severely congested, and the perirectal tissue was indurated. One perianal fistula entered the inflamed perirectal tissue which showed a small evacuated abscess cavity.

Microscopic Examination: The heart revealed focal perivascular scarring and a small amount of amyloid in a few small artery walls. The lungs showed emphysema. Small fibrin clots were seen in artery branches. The liver showed massive amyloid deposition in the peri-sinusoidal tissue, walls of hepatic artery branches, and periportal fields. Massive amyloid deposition in the arterial walls and in the perifollicular areas of the spleen were present. There was striking amyloidosis of the interlobular arteries of the pancreas. Except at the periphery, almost the entire adrenal cortex was infiltrated by amyloid. The kidneys showed extensive amyloid deposition in the arterial walls and glomeruli. Peritubular amyloid deposition was present in the medulla. Moderate amyloid deposition was present in the arterioles of the bone marrow. The stomach and duodenum revealed amyloid deposits in a few arteriole walls. In the small intestine, amyloid was present in the arterial walls. Mucosal ulcerations extended to the muscle with evidence of chronic inflammation. The mucosa of the colon was atrophic, and the submucosa was fibrotic and thickened. A mesenteric lymph node had amyloid deposition.

Summary: A twenty-eight year old man with a ten year history of chronic

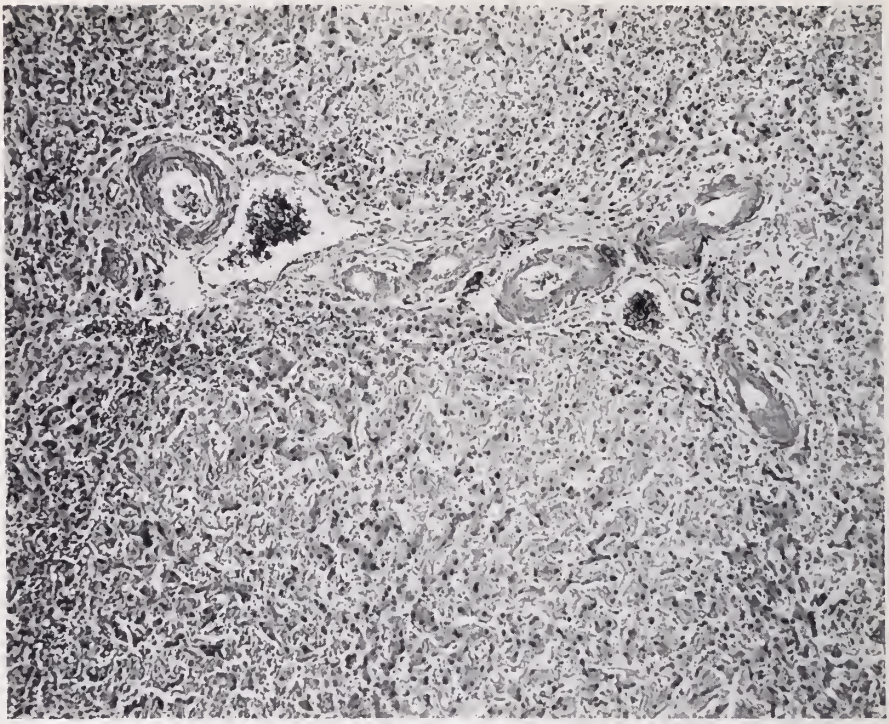

FIG. 1.: Amyloid deposition in the liver of case 1 (×76). The amyloid masses are present in the walls of the hepatic artery and in the sinusoids.

ulcerative colitis and perirectal infection died of peritonitis after eleven days of hospitalization. At autopsy, extensive ulcerative jejuno-ileitis and chronic ulcerative colitis with perforation of the jejunum were noted. There was generalized amyloid deposition, especially massive in the liver and spleen.

Case No. 2, Y. K. MSH #21,434. This was the first Mount Sinai admission of a 48 year old white female who entered with a chief complaint of weakness and anemia. She was well until 1934, when at the age of 28, she had the onset of bloody diarrhea with 30–40 bowel movements per day. Concomitantly, she developed joint pains and swelling of the fingers and ankles. During a two year period, she was admitted on three separate occasions to another hospital where a diagnosis of idiopathic chronic ulcerative colitis was made. Treatment with numerous blood transfusions was followed by a remission in symptoms for two years. However, the arthritis and bloody diarrhea recurred in 1938, and the patient remained bedridden at home for one and one-half years. In this period, she lost sixty pounds. In the next twelve years, the patient felt fairly well and required no medical care. In 1952, because of several months of bloody diarrhea (40 bowel movements per day) and crampy abdominal pains, she was admitted to another hospital.

Physical examination in 1952 revealed a woman who appeared older than her stated age of forty-six, and somewhat thin. Aside from hyperactive bowel sounds and rectal tenderness, there were no contributory physical findings. The he-

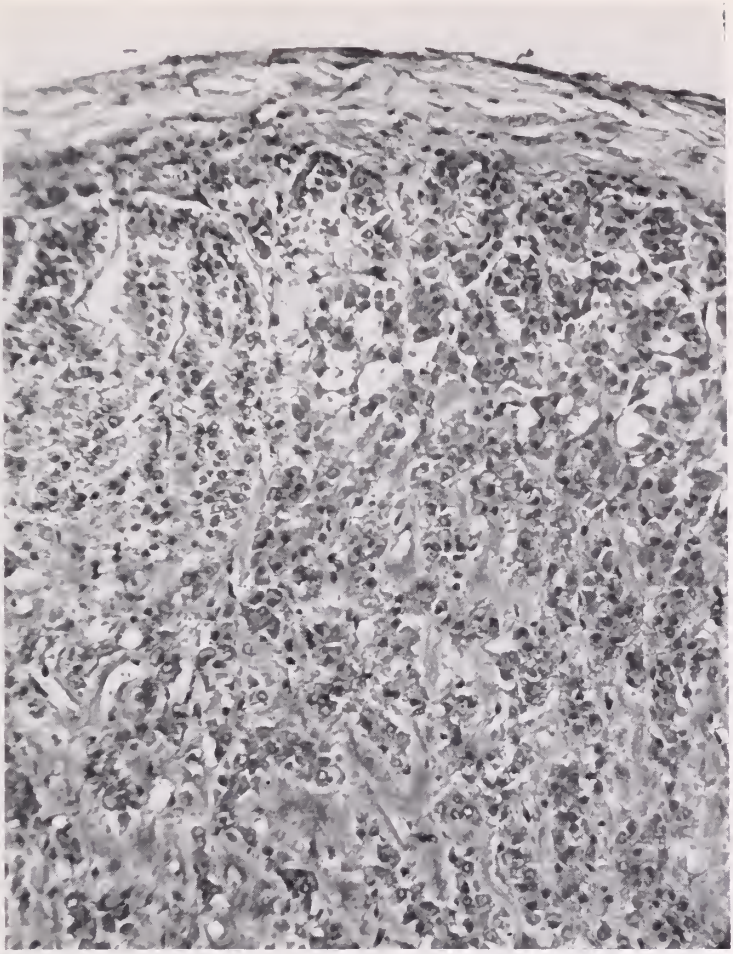

FIG. 2: Amyloidosis of the adrenal gland in case 2 (×200). The usual cord-like architecture is altered by the amyloid infiltration.

moglobin was 9.7 gms.%; the white blood cell count was 20,500 cells per cubic millimeter with 57% polymorphonuclear leukocytes, 30% band forms, 11% lymphocytes, and 2% monocytes. Sigmoidoscopy revealed a granular, red, friable mucosa which was interpreted as chronic ulcerative colitis. Cortisone and ACTH were administered for thirteen days with no effect on the low-grade fever or the diarrhea. Then, while a barium enema was being performed, under fluoroscopy, barium was seen to escape into the peritoneal cavity from "low in the left colon". At the same time, the abdomen became diffusely tender and spastic. An emergency laparotomy was undertaken and feces, fluid, and barium were found in the peritoneal cavity. The perforation was not visualized, and a transverse ileostomy was done with complete division of the ileum nineteen centimeters from the ileocecal valve. After several weeks of a stormy postoperative course characterized by sanguinopurulent rectal discharges and fever,

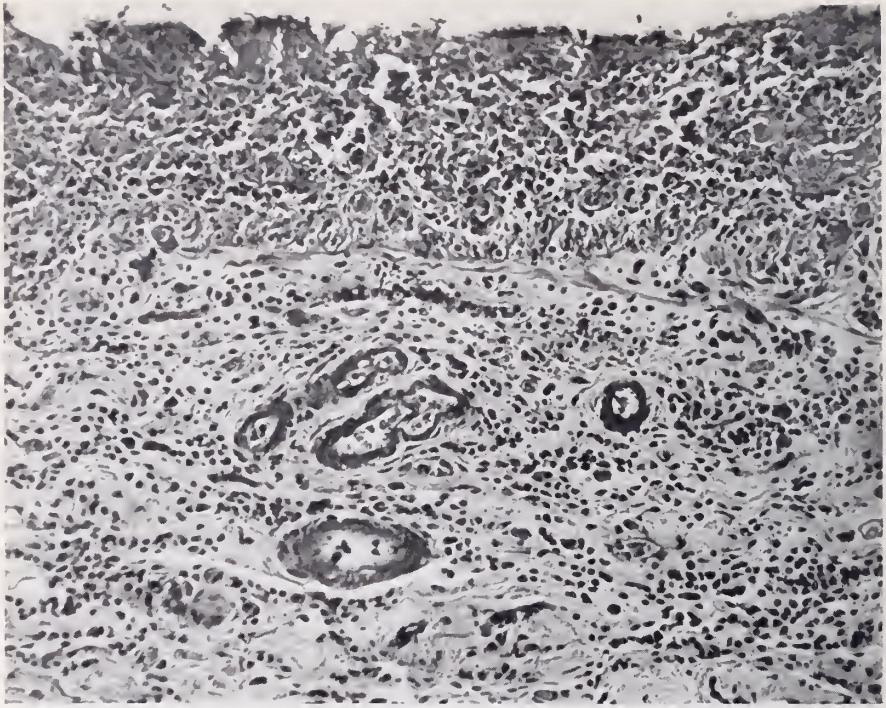

FIG. 3: Small intestine showing amyloid deposition in case 2 (×200). There is a striking amount of amyloid scattered throughout the lamina propria and in the blood vessel walls of the mucosa. Similar findings were present in the mucosa of the sigmoid colon and rectum.

the patient began to improve. Three months after the ileostomy, a subtotal colectomy was done by removing the distal nineteen centimeters of ileum and bringing out the sigmoid colon as a mucous fistula.

Pathological examination of the operative specimen revealed an ulcerated, granular colon typical of chronic ulcerative colitis, and a normal ileum. There was postoperative shock, auricular flutter, and pulmonary edema which responded to digitalis and mercuhydrin. Due to repeated subcutaneous clyses in the left thigh, an area of skin sloughed. Trypsin was used for debridement, and one month later a split-thickness skin graft was successfully applied to the granulating tissue on the thigh. Several weeks later, because of recurrent abdominal pains and intestinal obstruction, the ileostomy was revised with excision of about eight feet of ileum.

The patient was discharged from the hospital to a convalescent home where she remained for two years. Despite bloody and purulent rectal drainage, the patient did fairly well and gained weight. However, two months before her final admission, she developed nausea, anorexia, and weakness.

She was admitted for the first time to The Mount Sinai Hospital on September 9, 1954. Physical examination revealed a feeble, chronically-ill woman with an ileostomy in the midline of the upper abdomen and a mucous fistula in the midline of the lower abdomen. Vital signs were within normal limits. On rectal

examination, there was a stricture one and one-half inches from the anal orifice. There was a scarred 10 x 10 cms. area of the left thigh: the site of the previous slough.

Laboratory examination showed: hemoglobin 9.0 gms.%; white cell count of 17,000 with 85% polys. Urine: Specific gravity—1.030, 1+ albumin, few red cells and many white cells on microscopic examination. BUN—21 mgms.%, total protein 6.7 gms.%; A/G ratio—2.9/3.8; calcium—9.7 mgs.%; phosphorus —4.9 mgms.%; sodium—120 meq./L.; potassium—6.3 meq./L; CO_2—19.8 meq./L.; chlorides—102 meq./L.

Sigmoidoscopy to one and one-half inches showed a friable, granular, edematous, red mucosa. There was a stricture at one and one half inches with a considerable amount of pus coming through the very narrow lumen. Biopsy showed inflamed granulation tissue with purulent exudate adjacent to atrophic rectal mucosa. A G.I. series showed no evidence of intrinsic organic lesion of the small bowel. On x-ray, the ileostomy appeared to be in the proximal ileum. Barium was seen in droplets and streaks within the peritoneal cavity along the left lumbar gutter and in the pelvis.

Two weeks after admission, an abscess of the left buttock developed which drained spontaneously and healed. On September 29, 1954, there was profuse ileostomy drainage and fecal vomiting, and the patient became pulseless, and the blood pressure was unobtainable. She responded dramatically to intra-arterial blood and saline. One week later, a similar episode of shock occurred which was treated in the same way. However, the patient remained hypotensive and cyanotic for two days. The blood urea nitrogen rose to 33 mgms.%. Although the blood pressure returned to 110/65, peripheral cyanosis persisted and continuous oxygen was required. Cortisone, intravenous fluids, and antibiotics were administered, but the patient lapsed into shock one week later and died. Terminally, the blood urea nitrogen was elevated to 65 mgms.%.

Postmortem Findings. In the middle of the upper abdomen, there was a patent ileostomy opening. Six cms. below the ileostomy, there was a mucous fistula; and in the midline between the ileostomy opening and the fistula, there was an incisional hernia. A few loops of small bowel were caught in this hernia by adhesions, but did not appear to be obstructed or strangulated. There was 2 plus pitting edema of the ankles.

Adhesions in the region of the ileostomy opening separated the peritoneal cavity to some extent into upper and lower parts. In the upper part, the peritoneum was smooth and glistening. In the lower part and in the pelvis, there was a small amount of thick, brown, malodorous fluid. The peritoneal surfaces were moderately injected and scattered over them were numerous yellowish-white, slightly elevated flecks. The fundus of the stomach was herniated through the esophageal hiatus into the posterior mediastinum for a distance of 5 cms. In the lungs, there was a small, old infarct in the right upper lobe. The heart was unremarkable. The liver weighed 1350 grams. The spleen weighed 140 grams and was firm, dark red, and the Malpighian corpuscles were not clearly discernible. The kidneys weighed 100 grams each and were grossly unremarkable.

The adrenal glands were firm and very brown. The remaining small intestine from the duodeno-jejunal junction to the ileostomy opening measured 225 cms. in length. The mucosa was markedly congested, but it was intact throughout. The remaining sigmoid and rectum measured 30 cms. in length. The rectum was surrounded by a large amount of indurated fibrotic fatty tissue. About 4 cms. from the anus, the lumen was narrowed to about 0.5 cm. in diameter. The wall of the remaining sigmoid and rectum was markedly thickened. The mucosal surface showed numerous depressed ulcerated areas. The intervening mucosa was granular and injected.

Microscopic Examination. There was a moderate amount of amyloid deposited in the spleen around and within the Malpighian corpuscles and around the blood vessels. In the kidney there were small amounts of amyloid within the glomeruli. The adrenal glands similarly showed large amounts of amyloid within the cortex. There were small amounts of amyloid beneath the capsules of the lymph nodes. The wall of the small intestine was markedly congested and was infiltrated with inflammatory cells. There was amyloid in the lamina propria and in the wall of the mucosal blood vessels. The mucosa of the sigmoid and rectum was ulcerated in numerous areas and the intervening mucosa was atrophic, congested and infiltrated with inflammatory cells. The submucosa was fibrotic and thickened, and there was amyloid deposited around the mucosal blood vessels.

Summary: A 48 year old white female who had ulcerative colitis for twenty years underwent an ileostomy and subtotal colectomy. Three months prior to death, there was nausea, vomiting, diarrhea and weight loss. Profuse ileostomy drainage was followed by two episodes of shock. On postmortem examination, in addition to ulcerative colitis of the sigmoid colon and rectum, there was amyloid in the spleen, kidneys, adrenal glands, lymph nodes, and in the remaining large and small intestine.

DISCUSSION

It is interesting to speculate as to why amyloidosis has been rarely reported associated with ulcerative colitis, especially in view of the relative frequency of the latter disease. Up to date, including the present two cases, there have been only six authenticated cases in which both conditions have been present and identified at autopsy. In addition, one recorded case with chronic ulcerative colitis survived and showed 100% retention of congo red (2). Fishberg (6) mentions having seen a case of amyloidosis and chronic ulcerative colitis, and Dahlin (7) cites two such cases, one of which is fully discussed by Jensen et al. (4). In 1898, Nowak (8) discussed amyloidosis and noted that of seventy cases, there were forty-one with "chronic intestinal catarrh". However, the description of "chronic intestinal catarrh" by Nowak makes it highly improbable that this is the same disease as chronic ulcerative colitis. We, therefore, prefer not to include those cases in our discussion and mention Nowak's report from the historical standpoint.

The two patients with chronic ulcerative colitis and amyloidosis in the present report show striking similarities, both clinically and pathologically, with those

patients previously described in the literature. Firstly, the long duration of colitis, i.e., ten years in the first case, and twenty years in the second case, is a rather characteristic feature in the history of patients with chronic ulcerative colitis developing amyloidosis. The patients described by Moschcowitz (2), Mallory (3), Jensen et al. (4), and Frenkel and Groen (5) had symptoms of ulcerative colitis for five, five, twelve, and five years, respectively.

Interestingly enough, one can surmise further from the clinical histories and from what is known about generalized amyloidosis associated with chronic infection that the amyloidosis probably developed during the course of the colitis and not vice versa. Thus, in four patients with ulcerative colitis, the nephrotic syndrome became the predominant problem terminally after numerous hospital admissions for ulcerative colitis. In the second case presented, it was possible to obtain both clinical and anatomical evidence as to the chronological relationship between chronic ulcerative colitis and amyloidosis. Fortunately, the postmortem findings in the small intestine and rectal stump could be compared with the operative specimen of terminal ileum and colon two years prior to death. Whereas, there was striking amyloid deposition in the small intestine and rectum at postmortem examination, no amyloid was present in the surgical specimen of ileum and colon extirpated two years previously. It may, therefore, be concluded that the amyloidosis developed in the last two years of life after the patient had suffered with ulcerative colitis for eighteen years.

Although the second patient underwent ileostomy and then subtotal colectomy with some improvement two years prior to her demise, the retention in situ of diseased lower sigmoid and rectal colons constituted a focus of chronic infection with continuous sanguinopurulent discharge and stricture formation. This is of some importance when one considers the well known association of amyloidosis with such chronic infections as tuberculosis, chronic osteomyelitis, lung abscess, and bronchiectasis (2, 9). It is equally pertinent that in tuberculosis and other chronic suppurative diseases associated with amyloidosis, there has been regression of the amyloidosis following regression of the inflammatory process (10, 11). Unfortunately, in the first case and in the other known patients with colitis and amyloidosis, removal of diseased bowel was not possible, although an ileostomy was done terminally in two cases.

Jensen, Bargen and Baggenstoss (4) have stressed the presence of perirectal infection with chronic ulcerative colitis on the basis of their case report and two previously reported cases. They state that "it would seem that the suppurative processes in the three cases mentioned above may well have been responsible for the development of the amyloidosis." Since perirectal infection was also a conspicuous finding in the first patient, the aforementioned tenet may seem reasonable and applicable. However, to relate a pathogenetically obscure morphological finding such as amyloidosis to perirectal inflammation would seem to disregard almost entirely the severe chronic inflammation which existed in the entire colon, pericolonic tissues, and lymphatics.

For example, of 107 cases of chronic ulcerative colitis which were autopsied at the Mount Sinai in the past twenty years, six had a history of severe chronic

perirectal infection for more than one year with abscesses and fistulae. The longest duration of perirectal inflammation was in a twenty-six year old male who had had a six year history of recurrent perirectal infection and suppuration prior to death. However, in none of the six patients was amyloidosis present. Moreover, the second patient, who showed massive amyloidosis, never had perirectal abscess formation or fistulization. We are, therefore, of the opinion that perirectal infection is not requisite for the development of amyloidosis in chronic ulcerative colitis. On the other hand, there is sufficient evidence to conclude that amyloidosis is not a necessary sequela of chronic perirectal infection associated with colitis.

Amyloidosis of the adrenal glands is a rare but definite cause of Addison's disease (12–15). Guttman (13) reported 7 of 566 cases of Addison's disease to be due to amyloidosis of the adrenal glands, and Soffer, in an excellent review, points out the relative rarity of amyloidosis as a cause of Addison's disease (15). The two cases presented revealed striking amyloidosis of the adrenal glands as did three of the four previous cases, but no stigmata of Addison's disease were present in any of these patients. The poor correlation between massive amyloidosis of the adrenal glands and the development of Addison's disease is, therefore, confirmed in these cases of adrenal amyloidosis associated with chronic ulcerative colitis. In view of this, the conclusions of Heller and Camarata (14) are substantiated: that "probably bilateral amyloid deposition extensive to the point of almost total replacement of cortical tissue is requisite before insufficiency becomes clinically manifest."

In the second case, the diarrhea from the ileostomy which preceded each of the two episodes of clinical shock is an interesting facet to the association of amyloidosis and chronic ulcerative colitis. That amyloidosis of the gastrointestinal tract can be responsible for gastrointestinal symptoms was known in the nineteenth century. Thus, for example, Virchow (16) wrote:

> "Now this state of things (amyloid of the gastrointestinal tract) is very apt to escape observation, because this kind of metamorphosis, which exercises such a decided influence upon the functions of the intestines, causing deficiency of absorption and tendency to diarrhea, produces scarcely any effect perceptible to the naked eye. The intestines are pale and have a gray, translucent, sometimes slightly wax-like appearance."

In chronic ulcerative colitis, it has been difficult to relate which of the gastrointestinal disturbances were due to the colitis and which to the amyloidosis. However, from the second case in which the major portion of the inflamed colon was removed and the remaining small bowel was isolated by means of an ileostomy, one can conclude that the profuse ileostomy drainage was directly related to the amyloidosis of the intestinal mucosa and blood vessels. Amyloidosis of the gastrointestinal tract associated with chronic infections other than ulcerative colitis has been reputed by authors since Virchow not only capable of provoking diarrhea as in the second case, but also capable of causing severe anorexia, nausea, vomiting and abdominal cramps (17, 18). In certain cases of para-amyloidosis, constipation has been a prominent symptom. This has been correlated with the deposition of amyloid substance within the smooth muscle of the intestine resulting in disturbances in intestinal motility (17–20).

SUMMARY

Two cases of amyloidosis associated with chronic ulcerative colitis are discussed from the clinico-pathological viewpoint and compared with the four previously reported cases in the literature.

Interesting features of both cases relating to amyloidosis of the adrenal glands and gastrointestinal tract are described. In one patient it was possible over a two year period to trace the development of amyloid disease in the gastrointestinal tract.

Although the pathogenesis of amyloidosis is obscure and its association with chronic ulcerative colitis rare, the development of generalized amyloidosis in the six patients was associated in all cases with the retention in situ of severely diseased bowel.

ACKNOWLEDGEMENT

We are deeply grateful to Dr. Paul Klemperer for his advice, encouragement and critical review of the manuscript. We would also like to express our thanks to Dr. Edwin Rivera for his valuable assistance.

BIBLIOGRAPHY

1. Wilks, S., and Moxon, W.: *Lectures on Pathological Anatomy.* London: J. and A. Churchill, 1875.
2. Moschcowitz, E.: The Clinical Aspects of Amyloidosis. Ann. Int. Med., 10: 73, 1936.
3. Mallory, T. B., Castleman, B. and Parris, E. E.: Case Records of the Mass. Gen. Hosp., Case No. 33021, N. Eng. J. Med., 236: 75, 1947.
4. Jensen, E. J., Bargen, J. A. and Baggenstoss, A. J.: Amyloidosis Associated with Chronic Ulcerative Colitis. Gastroenterology, 15: 75, 1950.
5. Frenkel, M., and Groen, J.: Amyloidosis Na Behandeling Met ACTH. Nederl. Tijd. voor Geneesk., 98: 2352, 1954.
6. Fishberg, A. M.: *Hypertension and Nephritis.* Phil.: Lea and Febiger, 1939.
7. Dahlin, D. C.: Amyloidosis. Proc. Staff Meet. Mayo Clin., 24: 637, 1949.
8. Nowak, J.: Experimentelle Untersuchungen uber die Aetiologie der Amyloidosis. Virch. Archiv., 152: 162, 1898.
9. Dahlin, D. C.: Secondary Amyloidosis. Ann. Int. Med., 31: 105, 1949.
10. Pearlman, A. W.: Regression of Amyloidosis. Quart. Bull. Sea View Hosp., 6: 92, 1940.
11. Rosenblatt, M. B.: Recovery From Generalized Amyloidosis Secondary to Pulmonary Tuberculosis, report of a case. Arch. Int. Med., 57: 562, 1936.
12. Bowman, M.S., and Redfield, E. S.: Secondary Amyloidosis in Quadriplegics. U. S. Armed Forces Med. J., 2: 707, 1951.
13. Guttman, P. H.: Addison's Disease. Arch. Path., 10: 742, 1930.
14. Heller, E. L., and Camarata, S. J.: Addison's Disease from Amyloidosis of Adrenal Glands. Arch. Path., 49: 601, 1950.
15. Soffer, L. J.: *Diseases of the Endocrine Glands.* Phil: Lea and Febiger, 1951.
16. Virchow, R. L. K.: *Cellular Pathology.* Transl. by F. Chance, New York, De Witt, 1860.
17. Golden, R.: Amyloidosis of the Small Intestine. Am. J. Roent., Rad. Ther., and Nuclear Med., 72: 401, 1954.
18. Randall, O. S.: Multiple Myeloma Complicated by Intestinal Obstruction Due to Amyloid Infiltration of the Small Intestine. Am. J. Cancer, 19: 838, 1933.
19. Golden, A.: Primary Systemic Amyloidosis of the Alimentary Tract. Arch. Int. Med., 75: 413, 1945.
20. Perloff, J. K.: Unusual Cutaneous, Cardiac and Gastrointestinal Manifestations of Systematized Amyloidosis Associated with Multiple Myeloma. J. Mt. Sinai Hosp., 21: 195, 1954.

ATHEROSCLEROSIS: A REVIEW OF THE PREDISPOSING FACTORS AND THE PROBLEMS OF TREATMENT

STANLEY R. ROBBIN, M.D. AND SIMON DACK, M.D.

Atherosclerosis is recognized today as the leading cause of death in the United States and in other countries with similar economic standards, diet and way of life. In the United States, for example, deaths from cardiovascular-renal diseases of atherosclerotic origin currently total 800,000, exceeding the yearly toll from all other causes combined by approximately 100,000 (1). In the last two decades the trend of the death rate from these diseases has shown a definite pattern, namely, a distinct rise in males in the 45 to 64 year age groups. This applies particularly to coronary atherosclerosis.

Recent experimental, pathological and chemical studies have drawn attention to certain factors which may predispose to the development of atherosclerosis. At the same time, considerable progress has been made in the understanding of the underlying pathological process. It is now generally agreed that it is not confined to old age and is not an inevitable accompaniment of aging. It also varies with sex, heredity, state of nutrition and dietary intake.

The present review of the current knowledge of atherosclerosis has two aims: 1. to discuss the various chemical, metabolic, anatomical, constitutional and dynamic factors which are known to affect the development and progression of this condition; 2. to present evidence that atherosclerosis is related to an altered lipid metabolism or transport and that it may be influenced by dietary fat intake. At present there is a definite change in our attitude of hopelessness toward the prevention of this disease. The information gained from several types of clinical and experimental research may ultimately lead to a new and effective approach to prevention and therapy of atherosclerosis and its complications.

Chemical Factors in Atherosclerosis

Recent studies have suggested that atherosclerosis is primarily the result of disordered lipid metabolism (2–6). There are several observations to support this contention:

1. Quantitative measurements of the lipid content of the atheromatous plaques have shown that cholesterol and its esters comprise the major lipid component, in addition to neutral fat and phospholipids. Chemical analyses of the lipids of an atherosclerotic aorta and early atheromatous plaques in the coronary vessels have revealed that the proportions in which these were present were similar to the proportions in the plasma but not in other tissues. This suggests that the cholesterol and other lipids in the atheromata are derived from the plasma.

2. There is further evidence to support the concept that abnormalities in

From the Department of Medicine and the Cardiographic Laboratory, The Mount Sinai Hospital, New York, N. Y.

plasma lipid content or in lipid transport are responsible for pathologic changes in the arterial wall. A definite increase in the incidence of atherosclerosis has been found in persons with such clinical entities as hypothyroidism, nephrosis, diabetes and essential hypercholesteremic xanthomatosis (7, 8). All these conditions are associated with increased plasma concentrations of cholesterol.

3. Individuals who have suffered myocardial infarction have, as a group, an average blood cholesterol level higher than that of normal individuals (9).

4. Man is the only mammal known to develop atherosclerosis spontaneously and among mammals man is distinguished by an unusually high plasma cholesterol concentration. Atherosclerosis can be produced in lower animals only when plasma cholesterol concentration is artificially increased by feeding cholesterol or by other means (6). The chicken, rabbit, guinea pig and hamster may become atherosclerotic when fed cholesterol alone. In the monkey cholesterol and a diet deficient in sulphur-containing amino acids will produce atherosclerosis. In the rat thiouracil and renal hypertension are required in addition to cholesterol.

Although hypercholesteremia is an important etiologic factor in the development of atherosclerosis there are many individuals who have plasma cholesterol concentration within normal limits and nevertheless show clinical signs of atherosclerosis. Two important physico-chemical studies have been carried out to elucidate further the importance of other blood lipids, rather than cholesterol itself. The studies of Gofman and Barr and their coworkers have suggested that certain combinations of lipids and proteins, the lipoproteins, are associated with the development of atherosclerosis (29). A much higher correlation was found between the concentration of certain types of lipoproteins and the presence and severity of atherosclerosis than between the cholesterol level and atherosclerosis.

Barr and his associates found that the lipoproteins can be divided into two large groups, the alpha and beta lipoproteins (9, 10). The beta lipoprotein has a higher molecular weight, carries more lipid and has a higher cholesterol-phospholipid ratio as compared to the alpha lipoprotein. In many diseases associated with hypercholesteremia and atherosclerosis the beta lipoprotein is increased while the alpha is either low or normal. In persons who have sustained a myocardial infarction approximately 88 per cent of the plasma cholesterol is in the form of beta lipoprotein. In extreme cases of familial hypercholesteremia the beta lipoproteins constitute almost 94 per cent of the total lipoproteins. These observations emphasize the importance of the beta lipoproteins in atherogenesis.

Gofman and his coworkers, using the technique of ultra-centrifugal flotation analysis, were able to show that large molecules of lipoproteins with flotation rates expressed in Svedberg units of S_f 12–20 and S_f 30–100 are present in experimental animals in which atherosclerosis was artificially produced and in humans with a history of myocardial infarction and familial hypercholesteremia (2, 11). A high concentration of this group of molecules was not present in young healthy men and women or in normal animals. Gofman believed that the S_f 12–20 and 30–100 molecules were atherogenic. They correspond to the beta lipoprotein of Barr.

All these studies indicate that there is a chemical defect in atherosclerosis

which many workers in this field consider to be primary. If one accepts this assumption, it follows that atherosclerosis may be preventable, provided some chemical measures may lower the plasma and cholesterol lipid levels to normal. Cholesterol concentration in the plasma is of two origins, exogenous from the diet and endogenous from synthesis in the body, mainly in the liver. Decreased plasma cholesterol concentration may be the result of either decreased rate of synthesis in the liver, increased excretion of cholesterol through the gastrointestinal and biliary tracts, or a combination of both these factors (12). Studies with radioactive isotopes have shown the steps which may occur in the synthesis of cholesterol (13). Acetoacetic acid, squalene and delta 7 cholestenol play an important role as intermediates in the biosynthesis of cholesterol. A hope can be expressed that perhaps in the near future it will be possible to prepare inhibitors of cholesterol synthesis and thereby reduce the rate of endogenous synthesis.

Diet and Atherosclerosis

There remains the second problem in cholesterol and lipid metabolism; namely, the problem of the relation of exogenous cholesterol and fat in the diet to atherosclerosis.

A few years ago, on the basis of studies in experimental atherosclerosis, it was thought that reduction in dietary cholesterol was the key approach to lowering plasma cholesterol levels and preventing atherosclerosis. Today, however, most workers agree that what holds true for certain species of animals, namely, that feeding large amounts of cholesterol results in experimental atherosclerosis, does not hold true for humans. It is now conceded that there is no direct relationship between plasma cholesterol and the cholesterol content of the diet.

During the past year a number of investigators suggested that the feeding of phytosterols, namely, soybean lipid which contains beta sitosterol, prevented absorption of cholesterol (14). Cholesteryl, structurally very close to cholesterol, is believed to increase fecal excretion of exogenous cholesterol, thus lowering plasma concentration of cholesterol. Also, adenosine 5-monophosphate, when given to chickens which were artificially made atherosclerotic, was able to elicit a fall in serum cholesterol. All these intensive studies directed toward lowering absorption and metabolism of exogenous cholesterol are still in the process of research and no practical application can be recommended at the present time.

We are left with the main practical approach to this problem, namely, the dietary management of atherosclerosis. There is definite evidence to suggest that the life-long dietary pattern plays an important role in the development of atherosclerosis. This would explain the situation which becomes obvious to one gathering statistical data throughout the world, that the most prosperous populations with the highest standards of living are seriously threatened by atherosclerotic coronary artery disease, whereas communities of less-developed countries seem to be relatively immune from this disease. We must realize, therefore,

that if this increased incidence of coronary artery disease represents the success of our society and its high standard of living, we may expect more coronary disease in the future. This challenging problem was widely discussed in a panel discussion and symposium on atherosclerosis during the recent Second World Congress of Cardiology in Washington, D. C. (15–19). There was almost complete agreement among the international group of experts that diet and especially the amount of ingested fat seem to bear an important relationship to the incidence of coronary heart disease.

Gunnar Biörk of Sweden, in his presentation of "Wartime Lessons from Northern Europe on Atherosclerotic Heart Disease", summarized the well-known facts observed during World War II. In Norway and Finland, during forced reduction in dietary fats, there was a decrease in the incidence of coronary heart disease (15, 20, 21). With the end of hostilities and the return to a diet richer in fat content, the incidence of coronary heart disease returned to prewar levels. Similar observations were made in Holland and Germany at the end of the war. In the United States, however, where there was no change in dietary fat during the war, these changes were not observed.

Noboru Kimura of Japan, in an "Analysis of 10,000 Postmortem Examinations in Japan", reemphasized anew the well-known fact of the low incidence of coronary heart disease in Japan, a country whose diet is low in fat content (11). The hearts of 10,000 patients from all walks of life were studied. From a comparison of his statistical data with those obtained from the United States, the author concluded that the incidence of coronary sclerosis in Japan is one-tenth that of the United States at all age levels. Only 75 deaths in this large series of 10,000 autopsies were attributed to myocardial infarction.

A low level of coronary disease was found among the Bantu tribesmen in South Africa, according to John Higginson, the third panelist in this symposium (17). The incidence of coronary deaths in 1,300 consecutive autopsies was 1.8 per cent in the 41 to 60 year age group, as compared to 12.8 per cent in the United States. The diet of the natives is known to be low in fat content.

Two very interesting studies which may be crucial to the understanding of this problem were done in Italy by Ancel Keys and Paul D. White, who reported to the Congress on "The Field Studies in Italy, 1954" and "Clinical Surveys in Italy, 1954", respectively (18, 19). The populations of two cities were studied —Naples and Bologna. The Neapolitans eat much less fat than the Bolognese. According to Keys, blo ɔd cholesterol concentrations are much higher in Bologna than in Naples. Protein levels, average body weight and thickness of subcutaneous fat layer are approximately the same in the two populations. However, the incidence of myocardial infarction and coronary heart disease is much higher in Bologna than in Naples. White compared the incidence of coronary heart disease among general ward admissions in Naples, Bologna, Massachusetts General Hospital and in Malmo, Sweden. The data are statistically significant. The percentages were 2.0, 6.4, 18.2 and 16, respectively. In the twin cities of Minneapolis and St. Paul the percentage is 26.2, which is ten times as high as in Italy.

Analysis of food balance data indicates that during the last forty years the American diet has been changing to a higher total fat content, from about 30 per cent of total calories in 1910 to more than 40 per cent at the present time (22, 23). Such data on diets assume great significance when it is realized that in the United States the mortality rate of men from 40 to 70 years of age from coronary heart disease is higher than that of men of the same age group in other countries.

It was a feeling among the experts studying the problem of atherosclerosis that in order to evaluate the effect of diet on coronary artery disease, a world census is needed. This would explore the reasons why different populations vary in their susceptibility to coronary artery disease. Clues for prevention and control might then be found by studying the differences in the way of life among groups which differ most markedly in susceptibility to fatal coronary artery disease.

Body Weight, Nutrition and Atherosclerosis

There is general agreement that overweight is associated with increased development of coronary artery disease but there is considerable controversy over the mechanism which brings this about. Life insurance statistics have indicated a possible relationship between obesity and the increased prevalence of atherosclerosis (24). A recent reappraisal of these figures has suggested that this relationship is particularly true in males below the age of fifty years (25). Also, autopsies have shown excessive coronary artery involvement in overweight persons as compared with those of normal weight (26). On the other hand, the study of Wilens showed that patients dying of chronic body-wasting diseases have less than the expected degree of coronary sclerosis as compared to other patients of comparable age and sex (27). These two types of evidence point to a definite relationship between coronary artery disease and excess bodyweight.

An important problem which is not answered as yet is the mechanism by which overweight predisposes to coronary atherosclerosis. Overweight is due to a diet which provides an excess of calories over that which is necessary to maintain an ideal body weight. The question arises whether a high calorie intake per se is the offending agent in elevating lipoprotein levels in the serum or whether the specific type of foods, namely carbohydrates, proteins or fats, is important. This is difficult to determine because a high calorie diet generally contains a relatively high fat content.

Several studies emphasize the close association between the caloric content of the diet and the levels of blood lipids and cholesterol. Gofman and Jones, studying 241 apparently normal males aged 41 to 50 years, found a definite relationship between the concentration of atherogenic lipoproteins S_f 12–20 and increase in weight above ideal levels (28, 29). Another study by Walker on 1000 individuals 30 to 60 years of age seems to confirm these findings (30). A more recent report of Walker and associates demonstrated that weight reduction may be associated with lowering of the blood lipids (31). Another important conclusion drawn from this study was that the cholesterol content of the diet has no influence on the changes in the serum lipids produced by reduction of weight.

This brings us to another very important point, namely, the problem of prophylaxis and therapy of coronary disease by weight reduction and restriction of dietary fat intake. Gofman stated that of every 100,000 deaths due to coronary disease 17,000 would be prevented, if the average weight were brought down to the ideal weight (32). These are considerations affecting the average populations. As for individuals there are two separate problems, according to Gofman. Firstly, in the apparently normal healthy young man below the age of 40 whose overweight was corrected, it can be expected that if he maintains his ideal weight, his life span is almost as good as the normal. Secondly, in the person with well-established coronary disease in whom advanced atherosclerotic changes have already taken place, weight reduction will not fully decrease the probability of recurrent coronary occlusion, although the new rate of accumulation of atherosclerosis is lower. A lower risk of developing a new coronary occlusion can be expected but not to the degree that could have been obtained by correcting the overweight at an early date before definite narrowing of the coronary arteries took place.

All these studies and observations have shown that restriction of dietary fat results in a lowering of lipoproteins in the serum. However, there is not sufficient knowledge accumulated to explain how this effect is accomplished. These facts should not be interpreted to mean that atherosclerosis is merely a problem of diet. However, there is no doubt that in the very complex anatomical, hemodynamic and constitutional factors responsible for atherosclerosis, disturbances of lipid metabolism and the diet may play a decisive role. It is probable that a diet rich in cholesterol and fat, ingested over a period of years, is a prerequisite to the development of significant atherosclerosis. Pick, Stamler and Katz reviewed this problem and came to the conclusion that "a diet rich in fat places a strain upon the body metabolism for which the organism regulatory functions are apparently not fully adequate (33). Eating such a diet over many years leads to atherosclerosis." This applies to the population as a group and not to the individual. Once atherosclerosis takes place individual anatomical differences, as determined by heredity and other factors, come into play, modifying the primary factor.

Anatomical and Dynamic Factors in Atherosclerosis

Dock found that the intima of the left coronary artery was 2.5 times thicker in males than in females and he believed that this would account for the greater incidence of coronary artery disease in males (34). The thicker the intima the more space there is for deposition of lipids.

Enos and his co-workers performed autopsies on 300 United States soldiers who were killed in action or died accidentally in Korea (35). Their average age was 22.1 years. They reported the interesting and surprising fact that 77 per cent of the hearts of these young men showed gross evidence of coronary atherosclerosis, which varied from fibrous thickening to atheromatous plaques, occluding completely one or more major coronary arteries. A common finding was that disease was present most frequently at the bifurcation of the left coronary

artery and in the proximal fourth of the anterior descending branch distal to the bifurcation. A second important observation was made, namely, that the angle formed by the left anterior descending branch and the left circumflex artery may play a decisive role in the plaque formation. An angle close to 80 degrees seemed to be a predisposing cause to the development of a plaque. From this careful study it was concluded that the sclerotic lesions are commonly located at or near points of bifurcation, and secondly, that the hemodynamics in the lumen of the vessel near the bifurcation plays an important role in the mechanism of atheromatous plaque formation. The authors maintain that "eddying about bifurcations of the coronary arteries occurring during diastolic recoil of the dilated coronary arteries is a dynamic factor in the mechanism of plaque formation." This eddying of blood predisposes to trauma of the intima, which may initiate the formation of the plaque.

Mechanical Factors in Atherosclerosis

In addition to the chemical factor, which is considered to be the primary factor in the pathogenesis of atherosclerosis, a mechanical factor, namely, a rise in intravascular pressure, may hasten the evolution of atherosclerosis. There are several facts to substantiate this contention: 1. Pulmonary arteriosclerosis usually develops when there is prolonged increase in pressure within the pulmonary artery and its branches, as in emphysema, mitral valve disease, and certain congenital heart lesions (36). 2. In coarctation of the aorta, which divides the aorta into a high pressure area proximally and a low pressure area distally, atheromatous plaques develop much faster and earlier in the high pressure area. 3. In animals, experimentally produced atherosclerosis develops more rapidly when hypertension is produced at the same time as compared to normotensive animals on the same regimen (37).

In a recent study Moschcowitz makes a definite distinction between arteriosclerosis and atherosclerosis (36). He considers arteriosclerosis a process characterized by hyperplasia of the intima and elastica whereas atherosclerosis is associated with deposition of lipid substances within the arterial walls. According to Moschcowitz arteriosclerosis is a resultant of two factors, increased intravascular pressure and time. He considers the hyperplastic lesions of arteriosclerosis to be primary whereas the atherosclerotic plaques are secondary lesions. The two processes may occur separately but usually in the adult they are associated.

The increased intravascular pressure is a decisive factor in the production of atherosclerosis and explains the advanced atheromatous lesions which may be encountered in hypertensive individuals with normal blood cholesterol levels. Hypertension is believed to cause an increase in the imbibition of lipids into the arterial wall. In his final analysis, Moschcowitz concludes that atherosclerosis is the "resultant of the interaction of numerous factors, the most important being the chemical and physical properties of the plasma lipid, changes in the ground substance, the intravascular pressure, and the dynamic effect of time."

Age and Atherosclerosis

A better knowledge of arteriosclerosis has resulted from the pathological examination of Lober of the coronary arteries of 536 hearts obtained from autopsies of persons of both sexes from birth to 89 years of age (39). The degree of arteriosclerosis was found to increase progressively with age from childhood through the seventh decade of life at a nearly uniform rate. Coronary sclerosis was found to be significantly more severe in males than in females of the same age group even in the first decade of life. The degree of coronary arteriosclerosis was found to be much greater in individuals with evidence of previous hypertension or diabetes than in non-hypertensive or non-diabetic persons of the same age and sex.

Sex and Atherosclerosis

At the present time there are two main concepts to explain the well-known difference in degree and rapidity of progression of atherosclerosis in women and men—one based on anatomical factors, and the other which states that hormonal factors, mainly ovarian, are responsible for delaying the development of atherosclerosis in women (39).

The anatomical observations of Schlesinger and Zoll confirmed the definite influence of sex differences upon the development of coronary arteriosclerosis (40). In every age group from 20 to 80 years, coronary occlusions were found to be more frequent in men. The greatest difference was found in the 40 to 59 year group, in which coronary occlusions were 6 times more frequent in men than in women. In another study Rabson and Helpern reported that only 6 per cent of 617 cases of sudden death due to coronary disease occurred in women (41).

Four other important comparative autopsy studies have been made, based on the same techniques and criteria, which throw light on the sex differences in atherosclerosis. From a study of 600 hearts, White and associates found that the degree of coronary atherosclerosis increases rapidly in men in the 30 to 50 year age group (42). Later, it remains at a constant level. On the other hand, Ackerman and his co-workers found that in women there was a fairly constant but low level of coronary atherosclerosis until the fifth decade of life, and a steady rise from the fifth until the eighth decade (26). They suggested that the lower incidence of atherosclerosis in women occurs during their period of greatest ovarian activity, whereas the increase in atherosclerosis is coincident with the time when ovarian activity begins to wane in the majority of women.

Wuest, Dry and Edwards, using the same techniques, compared the degree of coronary atherosclerosis in bilaterally oöphorectomized women to that of uncastrated women and men of comparable ages (43). They found that the degree of coronary sclerosis in bilaterally oöphorectomized women of all age groups was 10 to 45 per cent greater than in uncastrated women but less than in men. The increase in atherosclerosis was particularly higher in castrated women with hypertrophy of the heart as a result of hypertension. It did not vary with the nutritional state.

In the fourth comparative study to explain the remarkable sex difference in the incidence of atherosclerosis, an attempt was made to determine quantitatively the degree of coronary atherosclerosis in relation to the supply of estrogens (44). This study demonstrated a low incidence of coronary atherosclerosis in a group of males treated with large doses of estrogens. Small doses of estrogens produced no effect. There was an increase in coronary atherosclerosis in castrated women. Among the women with breast carcinoma which is usually accompanied by hyperestrogenism, the amount of coronary sclerosis was minimal, even less than that of normal females.

These autopsy findings tend to support the concept that the female sex hormones may play the key role in protecting women from an advanced form of atherosclerosis. Further experimental evidence for this concept was furnished by Katz and associates, who showed that estrogens administered to chickens not only are capable of protecting the coronary vessels against cholesterol-induced atherosclerosis but also of inducing a reversal of the arterial disease to normal (6, 45, 46). These experimental studies suggested that estrogens may be effective as a prophylactic as well as a therapeutic agent in atherosclerosis.

There have also been several clinical studies which have pointed to a possible application of estrogens to human atherosclerosis. The studies of Barr and associates demonstrated that administration of estrogens in large doses to men with myocardial infarction produced definite changes in blood lipids, namely, an increase in the percentage of cholesterol in the form of alpha lipoprotein and reduction in the percentage of cholesterol in beta lipoprotein, a marked fall in the cholesterol-phospholipid ratio, and a fall in the concentration of total cholesterol in the plasma (9). After discontinuation of medication there was a prompt return of the distribution and concentration of lipids to the pretreatment levels. This phase of the problem is still in the experimental stage and not ready for wide clinical application.

As mentioned previously, there is a distinct difference in the composition and concentration of plasma lipoproteins in men and women. Jones and Gofman have shown that the so-called atherogenic lipoproteins of the S_f 12–20 class have a higher concentration in the serum of young men than in women of the same age (2). In the sixth decade of life there is a significant levelling of these differences. Similar sex differences were found by Russ, Eder and Barr in the alpha and beta lipoproteins of the blood (10). They, too, pointed out that the sex-linked differences tended to disappear in older men and women. Lewis and Page, using the electrophoretic analysis of the serum, demonstrated a much higher concentration of the beta lipoprotein in men than in women, with corresponding low levels of alpha lipoprotein (47).

As one may see from these studies of the blood lipoproteins by three different methods, namely, ultracentrifugation, chemical fractionation and electrophoresis, there is little doubt that sex differences are very important factors in the distribution and concentration of the plasma lipids and consequently in the development of atherosclerosis.

Hereditary and Familial Factors in Atherosclerosis

The association of hypercholesteremia, xanthomatosis and coronary atherosclerosis in members of the same family, a fact known for many years, was studied by Adlersberg and co-workers (7, 8). The nature of this inborn inherited error of lipid metabolism is obscure. There is a very high incidence among Jewish families. Adlersberg postulated that a genetically determined chain of enzymatic reactions results in excessive accumulation of lipids in the blood and also in the tissues. It is inherited as an incomplete dominent trait and is characterized clinically by hypercholesteremia, premature arcus senilis, xanthoma tuberosum and tendinosum, xanthelasma, and a high incidence of coronary artery disease at a relatively young age in women as well as in men. In this association the immunity of premenopausal women to the development of coronary sclerosis has not been observed. Hyperuricemia without clinical evidence of gout is also a frequent finding.

In an excellent study by Gertler and White of young men below the age of forty who suffered myocardial infarction, it was found that a factor of heredity appeared to play an important role (48, 49). The hereditary factors in the coronary profile pattern consisted of the presence of coronary heart disease in one or both parents or in any sibling at an age below 40 to 45 years, a history of metabolic diseases such as xanthomatosis, diabetes and gout, and a history of hereditary hyperuricemia and hypercholesterolemia.

Body Build and Atheroselerosis

We have discussed the hereditary and familial factors in the young individuals most prone to develop coronary sclerosis. In addition to the so-called "chemotype", which is characterized by increased serum cholesterol and uric acid levels and increased cholesterol-phospholipid ratio, the studies of Gertler and White suggested that there may be a characteristic "somatotype" also (48, 49). These young males have a body build which was classified by Sheldon as a dominant mesomorphy (50). This is characterized by squareness of body, rugged massive muscles, transverse diameter exceeding anteroposterior diameter, thoracic volume exceeding abdominal volume and a powerful pelvis.

More recent autopsy studies of Spain and co-workers appear to confirm this concept of an increased incidence of coronary heart disease in individuals with predominant mesomorphy (51). In young males who died of accidental deaths the degree of coronary sclerosis was greater in those with a mesomorphic habitus as compared to those with other types of body build.

Diabetes Mellitus and Cardiovascular Disease

Until recent years, the following factors were suspected of influencing the development and progress of premature vascular degeneration in diabetes: 1. Age; 2. the control of glycosuria and hyperglycemia; 3. the use of insulin; 4. type of diet; 5. high cholesterol content of the diet supposedly leading to hypercholesteremia. Several studies and observations made during the past

five to ten years have shown that the only definite factor is the duration of the disease rather than the severity, method of treatment or type of diet. This point was summarized by Mirsky, who stated, "It makes little difference how the diabetic is treated, if he lives long enough he will develop one or another form of vascular disease" (52, 53). Similarly, Priscilla White admitted that "the incidence of degenerative complications in juvenile diabetes far exceeds expectation (54). Arteriosclerosis appears inevitable." Dolger in a study of a group of juvenile diabetic patients, found that the early lesions of retinopathy were noted in 100 per cent of patients within an average of thirteen years after the onset of the disease and at this time about 50 per cent had albuminuria and mild hypertension (55–57).

Two additional clinical observations appear to support this contention. In some instances the most advanced arteriosclerotic lesions are seen in patients with so-called "mild diabetes" who have very little glycosuria and require no insulin. Also, the majority of reported cases of the most severe form of renal arteriosclerosis, namely, Kimmelstiel-Wilson syndrome, have been reported in such "mild diabetics" (58). To summarize, the severity and progression of atherosclerosis in diabetes has no relation to the amount of insulin required or to the ability to control the diabetes. "Present day treatment of diabetes has failed to avert the accelerated vascular damage, which is an associated phenomenon of the disease and not a complication" (55).

Conclusions

Numerous clinical and experimental studies during the past decade have made definite progress in the attack on the ever-growing problem of atherosclerosis. Knowledge concerning the dietary, constitutional, metabolic and nutritional factors may become helpful in the management of the atherosclerotic or potentially atherosclerotic patient. Unequivocal answers to many questions concerning the role of these factors cannot be given as yet, but a note of optimism is now dominating the present approach to the prevention and therapy of atherosclerosis.

REFERENCES

1. Statistical Bulletin, Metropolitan Life Insurance Company, Vol. 35, Dec. 1954.
2. Jones, H. G., Gofman, J. W., Lindgren, F. T., Lyon, T. P., Graham, D. C., Strisower B. and Nichols, A. V.: Lipoproteins in Atherosclerosis. Am. J. Med., 11: 358, 1951.
3. Gould, R. G.: Lipid Metabolism and Atherosclerosis. Am. J. Med., 11: 209, 1951.
4. Duff, G. L. and McMillan, G. C.: Pathology of Atherosclerosis. Am. J. Med., 11: 209, 1951.
5. Kellner, A.: Lipid Metabolism and Atherosclerosis. Bull. N. Y. Acad. Med., 28: 11, 1952.
6. Katz, L. N. and Stamler, J.: Experimental Atherosclerosis. Springfield, Ill., C. C. Thomas, 1953.
7. Adlersberg, D.: Hypercholesteremia with Predisposition to Atherosclerosis. An Inborn Error of Lipid Metabolism. Am. J. Med., 11: 600, 1951.
8. Boas, E. P., Parets, A. D. and Adlersberg, D.: Hereditary Disturbance of Metabolism. A Factor in the Genesis of Atherosclerosis. Am. Heart J., 35: 611, 1948.

9. Barr, D. P.: Some Chemical Factors in the Pathogenesis of Atherosclerosis. Circulation, 8: 641, 1953.
10. Russ, F. M., Eder, M. A. and Barr, D. P.: Protein-Lipid Relationship in Human Plasma. Am. J. Med., 11: 468, 1951.
11. Gofman, J. W.: The Role of Lipids and Lipoproteins in Atherosclerosis. Science, 111: 166, 1950.
12. Gutman, A. B.: Present Status of Atherosclerosis as a Derangement of Lipid Metabolism. Am. J. Med., 14: 1, 1953.
13. (a) Siperstein, M. D., Nichols, C. W., Jr. and Chaikoff, I. L.: Prevention of Plasma Cholesterol Elevation and Atheromatosis in the Cholesterol-Fed Bird by the Administration of Dihydrocholesterol. Circulation, 7: 37, 1953. (b) Symposium on Fat Metabolism. Johns Hopkins Hospital, Feb. 5, 1954.
14. (a) Peterson, D. W.: Effect of Soybean Sterols in the Diet on Plasma and Liver Cholesterol in Chicks, Proc. Soc. Exp. Biol. & Med., 78: 143, 1951. (b) Best, M. M. and Others: Presented at the American Society for the Study of Arteriosclerosis, Eighth Annual Meeting, Chicago, Ill. Oct. 31 to Nov. 1, 1954.
15. Biörk, G.: Wartime Lessons from Northern Europe on Atherosclerotic Heart Disease, Symposium on Atherosclerosis, Second World Congress of Cardiology, Washington, D. C., Sept. 13, 1954.
16. Kimura, N.: Analysis of 10,000 Postmortem Examinations in Japan. Ibid.
17. Higgins, J.: Arteriosclerotic Heart Disease Among the Bantu of Johannesburg, South Africa, Ibid.
18. Keys, A.: Field Studies in Italy, 1954, Ibid.
19. White, P. D.: Clinical Surveys in Italy, 1954, Ibid.
20. Malmeros, H.: The Relation of Nutrition to Health. A Statistical Study of the Effect of the War-Time on Arteriosclerosis, Cardiosclerosis, Tuberculosis and Diabetes. Acta. Med. Scandinav. Suppl., 246: 137, 1950.
21. Dedichen, J. and Stern, A.: Death from Degenerative Cardiovascular Disease in Norway During the Last War. Acta. Med. Scandinav. Suppl., 239: 150, 1950.
22. Keys, A.: Atherosclerosis. J. Mt. Sinai Hosp., 20: 118, 1953.
23. Keys, A.: Clinical Aspects of the Atherosclerosis Problem. International Forum Vol. I No. 12, Dec. 1953.
24. Dublin, L. I. and Marks, H. H.: Mortality Among Insured Overweights in Recent Years. Read at 60th Annual Meeting of the Association of Life Insurance Medical Directors of America, October 1951, New York, N. Y.
25. Gubner, R.: The Prognosis of Heart Disease As Viewed from the Life Insurance Standpoint. Presented at Annual Meeting, American College of Cardiology, Chicago, Ill., May 28, 1954.
26. Ackerman, R. F., Dry, T. J. and Edwards, J. E.: Relationship of Various Factors to Degree of Coronary Atherosclerosis in Women. Circulation, 1: 1345, 1950.
27. Wilins, S. L.: The Resorption of Arterial Atheromatous Deposits in Wasting Disease. Am. J. Path., 23: 793, 1947.
28. Gofman, J. W. and Jones, H. B.: Obesity, Fat Metabolism and Cardiovascular Disease. Circulation, 5: 514, 1952.
29. Gofman, J. W., Jones, H. B., Lyon, T. P., Lundgren, B. S., Strisower, B., Colman, D., and Herring, V.: Blood Lipids and Human Atherosclerosis. Circulation, 5: 119, 1952.
30. Walker, W. J.: Obesity: A Challenge in Preventive Medicine. Ann. West. Med. & Surg., 6: 339, 1952.
31. Walker, W. J., Lawry, E. Y., Love, D. E., Mann, G. V., Levine, S. A. and Stare, F. J.: Effect of Weight Reduction and Caloric Balance on Serum Lipoprotein and Cholesterol Levels. Am. J. Med., 14: 654, 1953.
32. Gofman, J. W.: Relation of Fat and Calorie Intake to Atherosclerosis. J. Am. Dietetic Ass., 30: 322, 1954.

33. Pick, R., Stamler, J. and Katz, L. N.: Atherosclerosis, Modern Concepts Cardiovasc. Dis. Vol. 23: No. 9, Sept. 1954.
34. Dock, W.: Predilection of Atherosclerosis for the Coronary Arteries. J.A.M.A., 131: 875, 1946.
35. Enos, W. F., Holmes, R. H. and Berger, J.: Coronary Disease among United States Soldiers Killed in Action in Korea. J.A.M.A., 152: 1090, 1953.
36. Moschcowitz, E.: Pathogenesis of Arteriosclerosis. J. Mt. Sinai Hosp., 21: 53, 1954.
37. Wakerlin, G. E.: Recent Advances in the Pathogenesis and Treatment of Atherosclerosis. Ann. Int. Med., 37: 313, 1952.
38. Lober, P. H.: Pathogenesis of Coronary Sclerosis. Arch. Path., 55: 357, 1953.
39. Levy, H. and Boas, E. P.: Coronary Artery Disease in Women. J.A.M.A., 107: 97, July 1936.
40. Schlesinger, M. J. and Zoll, P. M.: Incidence and Localization of Coronary Artery Occlusions. Arch. Path., 32: 178, 1941.
41. Rabson, S. M. and Helpern, M.: Sudden and Unexpected Natural Death. II Coronary Artery Sclerosis. Am. Heart J., 35: 635, 1948.
42. White, N. K., Edwards, J. E. and Dry, T. J.: Relationship of Degree of Coronary Atherosclerosis with Age in Men. Circulation, 1: 645, 1950.
43. Wuest, J. H., Jr., Dry, T. J. and Edwards, J. E.: The Degree of Atherosclerosis in Bilaterally Oöphorectomized Women. Circulation, 7: 801, 1953.
44. River, A. V. and Dimitroff, S. P.: The Incidence and Severity of Atherosclerosis in Estrogen-treated Males and in Females with a Hypoestrogenic or a Hyperestrogenic State. Circulation, 9: 533, 1954.
45. Pick, R., Stamler, J., Rodbard, S., and Katz, L. N.: Inhibition of Coronary Atheromatosis in Cholesterol-Fed Chicks Receiving Estrogens. Circulation, 4: 468, 1951.
46. Pick, R., Stamler, J., Rodbard, S. and Katz, L. N.: Estrogen-Induced Regression of Coronary Atherosclerosis in Cholesterol-Fed Chicks. Circulation, 6: 858, 1952.
47. Lewis, L. A. and Page, I. H.: Electrophoretic and Ultracentrifugal Analysis of Serum Liproproteins of Normal, Nephrotic and Hypertensive Persons. Circulation, 7: 707, 1953.
48. Gertler, M. M., Garn, S. J. and White, P. D.: Young Candidates for Coronary Heart Disease. J.A.M.A., 147: 621, 1951.
49. Gertler, M. M., White, P. D., and Others: Coronary Heart Disease in Young Adults. Commonwealth Fund, Cambridge, Mass., 1954.
50. Sheldon, W. H.: The Varieties of Human Physique. Harper Bros., New York, 1940.
51. Spain, D. M., Bradess, V. A. and Huss, G.: Observations on Atherosclerosis of the Coronary Arteries in Males under the Age of 46: A Necropsy Study with Special Reference to Somatotypes. Ann. Int. Med., 38: 254, 1953.
52. Mirsky, I. A.: Our Challenge for the Future. Diabetes Abst., 5: 71, 1946.
53. Mirsky, I. A.: Some Considerations of the Etiology of Diabetes Mellitus in Man. Proc. Am. Diabetes Ass., 5: 119, 1945.
54. White, P.: Diabetes in Youth. New England J. Med., 224, 586, 1941.
55. Dolger, H.: Factors Influencing Premature Cardiovascular Degeneration in Diabetes Mellitus. Progress in Clinical Endocrinology, Jan. 1950.
56. Dolger, H.: Clinical Evaluation of Vascular Damage in Diabetes Mellitus. J.A.M.A., 134: 1289, 1947.
57. Dolger, H.: The Clinical Evolution of Vascular Damage in Diabetes Mellitus. Bull., N. Y. Acad. Med., 22: 482, 1946.
58. Kimmelstiel, P. and Wilson, C.: Intercapillary Lesions in the Glomeruli of the Kidney Am. J. Path., 12: 83, 1936.

RUPTURED JEJUNAL INTUSSUSCEPTION WITH PROLAPSE OF INTUSSUSCEPTUM

Some Notes on the Natural History of Intussusception

EDWARD E JEMERIN, M.D.* and ALBERT CORNELL, M.D.**

New York, N. Y.

Advanced stages of acute intussusception are seen rarely nowadays. Even though the definitive diagnosis may not be made, the existence of an obstructing lesion or an acute abdomen is almost invariably recognized and surgical intervention is reasonably prompt. Thus, death from untreated intussusception is practically unknown and the natural history and variations in pathology of the advanced or untreated disease no longer form part of our normal understanding of the entity. Having encountered a variant unprecedent in our experience, a lesion obviously more advanced pathologically than those ordinarily seen, speculation naturally followed as to whether such a lesion were unique or whether such variations were part of the normal experience when surgery was undertaken with relative reluctance or even not at all. Naturally the chief interest in such speculation is historical, but both the case itself and the picture of the natural history of intussusception to which it led are unusually interesting and dramatic.

CASE REPORT

Mrs. E. S., aged 55, Hospital # 1270, was admitted to Flower-Fifth Avenue Hospital on February 5, 1951 complaining of severe generalized abdominal pain which had begun suddenly 36 hours before admission and had become progressively more severe. The patient vomited several times and passed a pinkish stool. Fever and abdominal distention, and tightness had supervened. For several months before admission there had been recurrent episodes of crampy epigastric pain relieved in about 15 minutes by lying down, and an occasional pinkish stool. Roentgen studies of the gastro-intestinal tract and gall bladder which had been made during this period were negative except for some spasticity and irritability of the duodenal bulb and slight spasticity of the colon.

There was a previous history of supracervical hysterectomy for fibroids, routine appendectomy and repair of a ventral hernia in November 1941 followed by prolonged drainage from the wound for approximately 9 months. Right sided abdominal pain usually following prolonged standing, had been experienced not uncommonly since this operation. In 1948 a right nephrectomy was performed for renal calculi with hydronephrosis and in 1949 a vaginoplasty was done because of urinary incontinence.

Examination on admission showed an acutely ill, restless, obese woman complaining of severe abdominal pain. The temperature was 101.6 degrees, the pulse 108 per minute. Blood pressure of 146/80 probably indicated some degree of

* Assistant Attending Surgeon, The Mount Sinai Hospital.

** Senior Clin. Asst. G.I.-O.P.D., The Mount Sinai Hospital.

shock for in 1950 it had been 240/100. The abdomen was diffusely distended and rigid with marked tenderness and rebound tenderness throughout. The rigidity and tenderness were maximal in the lower abdomen. Pelvic and rectal examinations were unsatisfactory although there was a sense of mass on bimanual palpation. The hemoglobin was 94 per cent, the white blood count 15,200 per cu. mm. with 53 per cent segmented and 29 per cent non-segmented polymorphonuclear leukocytes. An abdominal puncture in the left lower quadrant yielded bloody fluid.

Laparotomy was performed on the evening of admission through a paraumbilical left rectus muscle-splitting incision. On opening the abdomen the characteristic odor of gangrenous bowel was encountered. A large amount of foul bloody fluid was present in the peritoneal cavity and there was an intense generalized peritonitis. The underlying pathology was found in the mid-jejunum where what seemed on initial inspection to be a huge gangrenous diverticulum about 10 inches in length by 2 inches in diameter was seen. It was only after careful examination that the true nature of the lesion was revealed to be an intussusception in which both the intussusceptum and the base of the intussuscipiens were gangrenous. About 3 feet of mid-jejunum were involved. The gangrenous portion of the intussuscipiens had ruptured and through the perforation the gangrenous intussusceptum projected. It was this herniated gangrenous intussusceptum, its landmarks obscured by inflammatory exudate, that gave the appearance of a huge diverticulum (Figure 1). Resection of the involved jejunum with isoperistaltic side-to-side anastamosis was performed. The peritoneal cavity was aspirated of its sanguino-purulent contents. The abdomen was closed with figure-of-eight wire sutures through fascia and peritoneum, the skin edges loosely approximated, and the subcutaneous tissue drained between the skin sutures. On opening the specimen the probable focal point of the intussusception was seen to be a submucous lipoma about 1 inch in diameter at the base of the intussusceptum.

The patient was treated post-operatively with penicillin, dihydrostreptomycin and intravenous terramycin. An indwelling Levin tube was connected to Wangensteen suction and electrolyte containing fluids and blood were given parenterally. Her response was highly satisfactory. The fever subsided by the fourth post-operative day and the signs of peritonitis receded correspondingly. There was a spontaneous bowel movement on the fourth post-operative day and at this time the abdomen was soft. The indwelling Levin tube was removed and alimentation begun. The course was complicated by a bout of melena and chest pain without hemoptysis on the eighth day after operation. Chest films at this time showed findings at the right base indicative of atelectasis rather than of pulmonary embolus. The melena was attributed to a slough at the anastamosis site. It responded promptly to a bland diet, Banthine, Amphojel and transfusion. The patient's condition rapidly improved after this episode and on February 27, 1951, 22 days after operation, she was considered ready for discharge. On this date her general condition was good; she was taking nourishment well and her bowels were moving normally. Slight dullness and a few râles could still be elicited at the

right base where some residual atelectatic plaques were still demonstrable by x-ray. The abdomen was soft and non-tender. The wound had healed by delayed primary union after removal of the subcutaneous packings. The pathological report confirmed the operative findings of gangrenous intussuscepted bowel with a small fatty tumor mass near the end of the gangrenous area.

The patient has been followed and has been entirely asymptomatic to date. The abdominal wall is solid with no evidence of herniation or weakness.

DISCUSSION

In brief, the pathology found at operation consisted of a jejunal intussusception for which a submucous lipoma served as the focus. Both the intussusceptum and the base of the intussuscipiens were gangrenous, and there had been a rupture or perforation of the gangrenous sheath with herniation of the intus-

FIG. 1. Jejunal intussusception with perforation of intussuscipiens and prolapse of intussusceptum reconstructed from autopsy material. Arrows point to rupture site.

susceptum through this site. There was copious foul bloody fluid in the peritoneal cavity, and a full-blown peritonitis was present. The patient recovered following resection. The true nature of the pathology encountered was not apparent immediately. The protruding gangrenous intussusceptum was edematous and covered with exudate obliterating the normal markings so that mucosa could not be distinguished from serosa. The orifice through which the prolapse occurred was also obscured by overlying exudate. As a result, the protruding intussusceptum resembled at first sight a huge gangrenous diverticulum and the true nature of the pathology was revealed only after careful inspection. The photograph (Fig. 1) shows the diverticulum-like appearance of the herniated intussusceptum. The original specimen could not be used for the picture as it had been reduced and fixed but an almost identical substitute was reconstructed for the purpose from autopsy material.

A search of the literature was made to determine whether any similar cases had been reported and whether the natural evolution of the disease would make such a complication likely. The entire literature, which is enormous, was not reviewed, but most key articles and collective reviews were, as well as any report that seemed as though it might contain relevant material. Of these, only articles pertinent to the discussion are included in the bibliography.

Most articles since the turn of the century deal with cases whose natural courses were interrupted surgically and are concerned primarily with anatomical varieties, etiology, diagnosis and treatment in an effort to reduce to acceptable levels the appalling mortality of approximately 70% in 1906 (1). It was only by referring to the literature prior to 1900, when laparotomy was undertaken with great reluctance, if at all, that a rounded picture of the course without surgical intervention could be obtained.

Invagination per se need not lead to strangulation or even obstruction, and chronic forms have been reported where patients have lived for months showing only abdominal disturbances of varying degree. However, acute intussusception, if unrelieved, usually kills rapidly through the toxemia, shock, and fluid and electrolyte alteration resulting from obstruction and strangulation. Death occurs in 6 to 7 days (2) and is more rapid in children than adults (3). Naturally, courses between these two extremes are not infrequent. Obstruction is produced by the filling of the intussuscipiens with the invaginated bowel which becomes swollen, thickened, and engorged with blood resulting in marked narrowing or obliteration of the lumen. Obstruction of the sheath is also brought about by bending or curving of the intussusceptum on the mesentery of the bowel. Lastly, the markedly narrowed lumen may be plugged by a food bolus to complete a partial obstruction. Irreducibility may be due to a peritoneal reaction in the inner and middle layers gluing their serous coats together while additional adhesions involving the external coat may occur at the neck of the lesion. Other factors producing irreducibility may be the ileo-cecal valve itself, marked swelling, twisting, or curving of the intussusceptum, or a tumor at the apex.

Strangulation is produced by compression and angulation of the mesentery of the invaginated bowel in a fashion comparable to that occurring in strangulated

hernia (4). The resulting gangrene of the intussusceptum is not uncommon even now and in the past served as the basis for a remarkably dramatic and salutory sequence of events. In instances in which the course had been somewhat protracted spontaneous cure sometimes resulted through the sloughing off and elimination by rectum of the gangrenous intussusceptum. Because of prompt surgical intervention this phenomenon is no longer seen, and even in a series of 400 consecutive cases from London Hospital from 1903 to 1920 (2) there was not one example of spontaneous elimination. However, the earlier literature contained numerous examples of this occurrence which of course was more common in adults than in children who ran more fulminating courses. Elliot & Corscaden (3) in 1911 published a study based upon 300 collected cases, 43 of which had undergone spontaneous discharge of the necrotic intussusceptum. Only 3 of these patients were less than 4 years of age. Leichtenstern (5, 6) in 1873 collected 593 cases from the literature. Forty-two percent of these had sloughed out the gangrenous invaginated bowel. This of course did not represent the true incidence as his material was compiled from individual reports dealing for the most part with unusual and abnormal cases. One amusing instance which indicates the low esteem in which surgery was held at the time was included in a report by Marnoch (7) in 1906. A case of intussusception in a 3 year old boy was presented to the oldest practitioner in the community for advice as to management. He said he had never seen a case survive surgery while an occasional one recovered without. Accordingly, the boy was treated expectantly. He discharged the intussusceptum spontaneously and recovered fully.

Despite the last example, waiting for a gangrenous intussusceptum to separate and be eliminated was obviously not to be recommended even in the 1920's when the mortality with surgical intervention had already been reduced to 34.75 per cent (2). Not only was it extremely unlikely that the patient would survive until such time as the sloughing occurred but it is not to be supposed that when spontaneous elimination did take place that cure necessarily followed. According to Treves (4), over 40 per cent of patients who underwent spontaneous elimination died from effects related to the intestinal lesion or to the elimination process itself. A premature separation might result in perforation or rupture at the neck with peritonitis, ulceration might persist at the line of slough with death from perforation or hemorrhage, part of the intussusceptum might remain, producing further invagination, or elimination might occur too late to save life. Lastly secondary stricture formation with obstruction from cicatrization at the line of slough was a not uncommon sequel occurring anywhere from 2 to 18 months later.

Rarely, recovery without surgery also took place by spontaneous reduction, by fistula formation proximal to the site of intussusception, or by a rent forming through an area of limited gangrene in the inner and middle layers of an invaginated segment.

In contrast to the relative frequency of gangrene of the intussusceptum, the intussuscipiens or sheath seldom showed any marked change even in untreated cases. Usually, at most, there was some distention from the invaginated bowel,

some congestion and thickening, and moderate serosal reaction. Gangrene of the intussuscipiens was rare, and then usually localized. Gangrene of the entire intussuscipiens would depend upon unusual events such as progressive thrombosis extending from the strangulated vessels of the intussusceptum to those of the sheath, or to a superimposed volvulus. Ulceration of the mucous membrane occurred, occasionally leading to perforation. When local gangrene developed it was often due to the pressure of a greatly curved intussusceptum and might also lead to perforation.

The only reference in the 20th century literature to gangrene of the intussuscipiens was in 1911 in Elliot & Corscaden's (3) series of collected cases. They referred to its occurrence in their discussion and reported one case showing incipient gangrene of the sheath. In the earlier literature, as might be expected, advanced changes in the sheath, including perforation and gangrene were less uncommonly seen. Leichtenstern (6), in 1874 reported on 593 collected cases. Among 175 of these that were autopsied, there were 28 examples of perforation. Morris (8), in 1877 reported an instance of ileo-ileal intussusception with the sheath gangrenous and a postage stamp size perforation at the lower end. Rafinesque (9) in 1878 described frank gangrene of the intussuscipiens occurring 8 times, and incipient gangrene 3 times, in 53 cases. Of those with frank gangrene, 7 showed one or more perforations and in one instance the intussuscipiens was completely divided. Of even greater interest is the fact that in 4 of these cases the intussusceptum protruded through the perforated sheath as in our case. Treves (4) also notes one example of protrusion of the intussusceptum through a gangrenous perforation in the intussuscipiens and has an excellent illustration of the lesion.

In all, then, it was possible to cull from the literature five cases, all before 1884, of lesions similar to the one reported here. The rarity of the lesion is of course due to the interruption of the natural course of the condition by increasingly prompt diagnosis and surgical intervention. The recovery of our patient following such a massive peritoneal insult would have been extremely unlikely just a few years ago. With modern intensive antibotic therapy, fluid and electrolyte control and blood replacement great comfort can be taken from the fact that such recoveries are no longer rarities.

SUMMARY

1. An unusual case of intussusception with perforation of a gangrenous intussuscipiens and herniation of the intussusceptum through this perforation is presented.

2. The natural history of advanced or untreated intussusception is discussed.

BIBLIOGRAPHY

1. M'Gregor, A. N.: Intussusception Statistics and Their Story. Scot. Med. and Surg. J., 19: 151, 1906.

2. Perrin, W. S., and Lindsay, E. C.: Intussusception: A Monograph Based on 400 Cases. Brit. J. Surg., 9: 46, 1921.

3. Eliot, E., Jr., and Corscaden, J. G.: Intussusception with Special Reference to Adults. Ann. Surg., 53: 169, 1911.
4. Treves, F.: Intestinal Obstruction: Its Varieties and Their Pathology, Diagnosis and Treatment. Cassell and Co., Ltd., London, 1884.
5. Leichtenstern, O.: Cyclopaedia of Practice of Medicine (Edited by von Ziemssen, H. W.) N. Y. Wood, 1876, 7: 477.
6. Leichtenstern, O.: Ueber Darm-Invagination. Vierteljahrschrift für die Proktische Heilkunde, 1874, p. 17.
7. Marnoch, J.: Cases of Intussusception. Scot. Med. and Surg. J., 19: 176, 1906.
8. Morris, H.: Intussusception of Ileum. Trans. of Path., Soc. of London, 28: 131, 1877.
9. Rafinesque, F. G.: Étude sur les Invaginations Intestinales Chroniques. Paris, J. B. Baillière et Fils, 1878.

CONGENITAL RETINAL DETACHMENT IN MICROPHTHALMIA ASSOCIATED WITH INTERNAL HYDROCEPHALUS

JOSEPH LAVAL, M.D. AND ALBERT CHATZINOFF, M.D.*

New York, N. Y.

Congenital retinal detachment is a rare occurrence. However, it has been seen fairly commonly in microphthalmic eyes. The normal infant's eye has a Lange's fold of retina near the ora serrata and in cases of microphthalmia where there is lack of development of the sclera combined with a normally developed retina, it is conceivable that the retina could be pushed away from its normal position against the choroid. Should the lower portion of Lange's fold tear loose from its attachment, then a disinsertion develops below and the retina can curl up and bare the choroid. Such a case, associated with internal hydrocephalus, was seen recently at this hospital.

CASE HISTORY

Present Illness: This was the first admission of a 7 month old infant girl (M.S.), who entered on Feb. 3, 1954 because the mother noted the patient's right eye to be small and her head to be large. Since birth, the infant's right eye was noted to be smaller than the left, and it often turned inward. The mother noted that the infant had a large head but was not concerned about this because a normally developing sibling had a similarly large head. The infant had developed normally to the date of admission and showed a good weight gain, was alert, active and interested in her environment.

Past History: The infant was born after seven months' gestation (parent's calculation) and the birth weight was 1975 grams. Labor was uneventful and the delivery was spontaneous. Because of her small size, the infant was placed in oxygen for 1 day and remained in an incubator for 2 subsequent days. She then progressed normally in a bassinet and was discharged after 3 weeks weighing 2325 grams. Physical examination at that time revealed a small right eye but no other suggestion of a congenital abnormality.

Physical Examination: General examination revealed no abnormality of the ear, nose, throat, heart, lungs, abdomen or extremities. The head of the infant measured 18¼ inches whereas six weeks prior to admission it measured 16½ inches. The anterior fontanel was open and measured 2 by 2 inches but was not tense and fell away when the patient was placed in a sitting position. The sagittal suture was slightly open. Neurological examination was entirely negative. Eye examination: Vision in the right eye was markedly diminished or possibly absent. The eye was noted to wander. It did not follow light and the child resisted strongly when the left eye was covered. The left eye followed light readily and seemed to have no noticeable loss of visual acuity. Tension in both eyes was normal to palpation. Transillumination of both eyes was negative. External

From the Department of Ophthalmology, The Mount Sinai Hospital, New York City.
* Trainee, National Institute of Neurological Diseases and Blindness.

Fig. 1: M. S. age 7 months, congenital retinal detachment with exposure of choroid and pigment epithelium below.

examination: The right eye was noticeably smaller than the left and the cornea was measured at about 7 to 8 mm. The pupil of the right eye reacted consensually but not directly to light. The left eye showed no external abnormality. Media: The lens and vitreous in both eyes were negative. The ciliary processes in the right eye were not visible. Fundi: The right eye revealed a detached retina which was torn completely free below and was curled up on itself to lie as a whitish-grey mass in the supero-temporal portion of the fundus. The curled retina covered the optic disc and exposed the choroid and pigment epithelium infero-nasally (Fig. 1). The drawing does not show a poorly pigmented area of choroid which could be seen at times just at the lower margin of the detached retina. The fundus of the left eye was normal.

X-ray: Skull films showed the cranial vault to be slightly larger than usual for the age of the infant. Ventriculography revealed severely dilated lateral ventricles with no filling of the fourth ventricle and doubtful filling of the third ventricle. It was the opinion of the neurosurgical consultant that the infant had an obstructive hydrocephalus. A unilateral ventriculo-cysternostomy was suggested.

DISCUSSION

This case presents an unusual picture of congenital retinal detachment in a microphthalmic eye. This picture should in no way be confused with the terminal stage of retrolental fibroplasia in which complete retinal detachment occurs with rolling up of the detached retina resulting in exposure of the choroid and pigment epithelium below (Fig. 2). The birth weight of 1975 grams in this child, the normalcy of the other eye and the limited use of oxygen in this case are strong factors which make such a diagnosis untenable.

The embryological explanation for development of congenital retinal folds has been thoroughly presented by Ida Mann (1) who states: "Since the coaptation of the inner and outer layers of the optic cup is never, even in the adult, an anatomical continuity but merely a superposition, it is to be expected that for a large part of intra-uterine life the connection will be very indefinite indeed. For one thing, so long as the eye is increasing in size and altering its shape, the

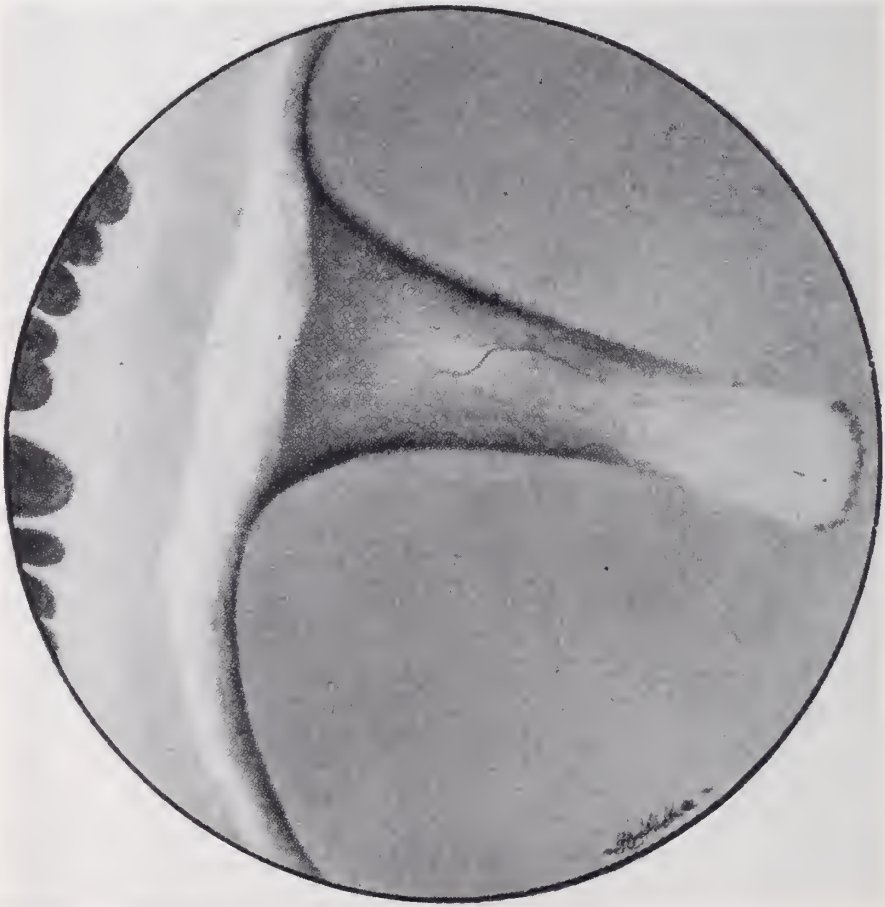

Fig. 2: Retro-lental fibroplasia showing the scalloped edge of ciliary body and complete retinal detachment with exposure of choroid and pigment epithelium.

growth rate of the inner layer must differ both in various regions and in relation to that of the outer layer. Although finally the exact surface area of the inner side of the retina must be mathematically slightly smaller than that of the pigment epithelium, yet during much of the growth period it is appreciably greater. Much of the neural ectoderm of the marginal region of the cup (anterior of the ora serrata) is found formed by the forward growth and continued eversion of the inner layer and this has always the appearance of being in an active state of alteration. Even towards the end of development the persistence of the marginal sinus until the final completion of the iris shows that this growth and turning outwards is always occurring. Only towards the end of foetal life does the pigmentary change characteristic of cells of the outer layer of the cup involve the iris epithelium. Therefore we shall not be surprised to see that complete or partial persistence of the cavity of the primary optic vesicle (which is another way of stating that the retina is detached, both developmentally and clinically) is normal in the developing eye. At first the appearance was thought to be an artefact (separation of layers by shrinkage during fixation) but Seefelder (2) and other embryologists have shown conclusively that this is not so. During the early growth periods up to the 3rd month the separation is great. After that the layers often appear in apposition, but separation occurs very easily, especially in the less differentiated anterior parts (with the exception of the ciliary epithelium where the adhesion of the two layers to each other is always very strong).

"Congenital detachment, partial or complete, is common in microphthalmic eyes. It differs from the acquired detachment in that there is no hole in the retina and the detached area often appears tightly stretched between its points of attachment. The detachment may be due either to failure of the growth of the inner layer of the cup to keep up with the outer layer and the sclera, or to the exact opposite, a redundancy of the inner layer so that it cannot of necessity be in perfect apposition everywhere. The redundancy may itself be due to primary overgrowth, or to stretching and traction from abnormal growth of neighbouring structures. Congenital detachment without other abnormalities is rare. The eyes are almost always microphthalmic and often show other abnormalities such as persistent hyaloid."

Two cases in adults have been seen by one of the authors (J. L.) wherein the retina was disinserted below and then rolled up on itself exposing the choroid below. A view of the outer surface of the retina which normally is in contact with the pigment epithelium layer could then be seen. Surgically these cases did poorly, but the development of the techniques of scleral resection and injection of air into the vitreous which are performed today would perhaps offer these patients a better prognosis.

In cases of congenital retinal detachment, surgery has been found to be uniformly unsuccessful.

BIBLIOGRAPHY

1. Mann, I. C.: Developmental Abnormalities of the Eye. 1928, Cambridge U. Press, London, p. 206.
2. Seefelder, R.: Weitere Beispiele von Netzhautanomalien in sonst normalen fotalen menschlichen Augen. Arch. F. Ophth., 71: 89, 1909.

ENTEROLITHIASIS IN THE NEWBORN

MANSHO T. KHILNANI, M.B.,* BERNARD S. WOLF, M.D.
AND ERNEST E. ARNHEIM, M.D.

New York, N. Y.

While enteroliths are uncommon, their occurrence in the newborn period is of special interest. The earliest reference to a fecolith in a newborn is by Foumier in 1813 (as quoted by Walker (1)), who described an instance of imperforate anus with a fecolith appearing through a recto-vaginal fistula. In adults, most of the enteroliths that have been reported have been associated with diverticula, particularly Meckel's diverticulum, and with the appendix. Enteroliths with sufficient calcium to be demonstrable by roentgenography form only a small fraction of the total number. The presence of calcium deposits in an enterolith apparently is not related to any systemic disturbance in calcium metabolism or directly to the length of time that an enterolith exists in the intestinal tract. In the newborn and the adult with a demonstrable enterolith, the problem of its clinical significance, if any, arises. It is therefore considered desirable to report the following case which, in some respects, appears to be unique in published literature.

CASE REPORT

T. L. was the product of an uncomplicated full-term pregnancy. The mother's first pregnancy was complicated by pyelitis and resulted in a stillborn. At birth, this second child weighed six pounds, thirteen ounces. An imperforate anus and deformity of the right ear were noted. No history of passage of meconium per urethra could be obtained. Physical examination showed normal vital signs. There was no remarkable abdominal distention; no abdominal masses could be felt. A transmitted impulse to the finger at the anal dimple could be obtained. A deformity of the right auricle with occlusion of the external auditory canal was seen. Laboratory findings: Hemoglobin 20.8 grams, R.B.C. 5.7 million. Urine examination appeared normal on chemical analysis, but showed fine granular casts and rare white cell microscopically. The blood calcium (done after operation) was within the normal range. Blood calcium of the mother was normal. X-Ray examination done to ascertain the length of the atretic rectal segment revealed multiple calcific densities scattered throughout the abdomen which on careful scrutiny appeared to be 2–3 mm. in diameter, ring-shaped and located essentially in the flanks and in the course of the transverse colon. Distended loops of bowel with fluid levels were seen which, from their position in the abdomen and their appearance, were presumed to be colon. Slightly distended small bowel loops in the center of the abdomen were also vis-

From the Departments of Radiology and Surgery, The Mount Sinai Hospital, N. Y., N. Y.

* George Blumenthal Jr. Fellow in Radiology.

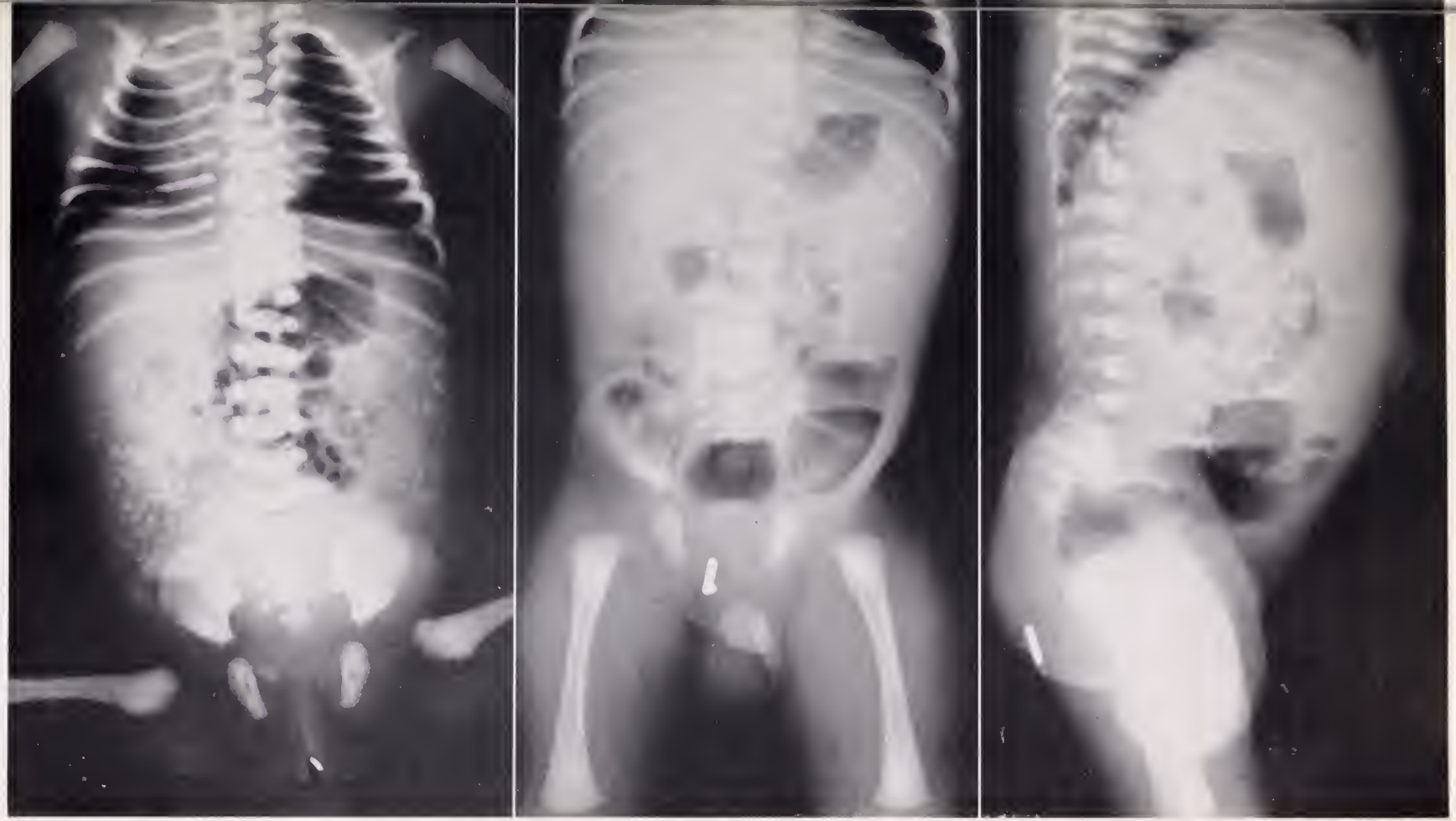

Fig. 1a (left). T. L. A.P. recumbent film of abdomen shows innumerable calcific densities 2–3 mm. in diameter. Calcific densities overlying sacrum are believed to be in the ileum. Marker on anal dimple. Note the vertebral deformities.

Fig. 1b (center). Same case. A.P. film of abdomen *with head down* shows fluid levels in colon and stomach. The calcific densities appear to lie in the course of the distended colon. Gas in rectum reaches to a point about an inch from marker.

Fig. 1c (right). Same case. Lateral film in *head down* position shows that the calcific densities extend from front to back of abdominal cavity. No concretions seen in region of liver. Several loops of air-containing small bowel in mid abdomen do not appear remarkably distended.

ualized. The distended large bowel extended to a point about an inch from the marker at the anal dimple. Congenital anomalies of the 11th and 12th dorsal vertebrae were seen (Fig. 1a, b, c).

The appearance and the position of the calcified nodular densities were not of the type usually seen in meconium peritonitis, in which the calcification is in the nature of faint flakes or plaques located in the lower quadrants. Clinical and roentgen evidence of small bowel obstruction was also lacking. Peculiar mottled shadows within loops of small bowel due to inspissated meconium as seen in meconium peritonitis, also were not noted.

The child was operated on 24 hours after birth and the blind loop of the rectum which was adherent anteriorly to the posterior wall of the urethra, was freed and brought down to the perineum. A recto-urethral fistula was repaired and cystostomy performed. Meconium was passed at the time of operation and the surgeon's note states: "The rectum was filled with a material which in no way resembled meconium, being composed of small pellets of light tan material".

Post-operatively, the child did well. He had three bowel movements the day after surgery, which were light brown in color and also contained a large number of hard small pellets, all almost of equal size. The meconium specimens on both occasions were unfortunately discarded. As a result, chemical analysis of the pellets and detailed studies of the meconium are not available. A film of the abdomen on the fourth post-operative day showed no evidence of calcific densities. An additional anomaly noted post-operatively on intravenous pyelography was an ectopic right kidney. Normal, well-formed, yellow stools were passed for the first time on the fifth post-operative day.

DISCUSSION

The only published case that could be found which resembles the one described above is by Camp and Roberts (2). A film of the abdomen in their case indicates that the number and size of the concretions were similar to those in the present case. However, in Camp's case, an ileal stenosis of marked degree was present with small bowel obstruction and the bulk, if not all, of the concretions were in dilated small bowel. Because of this published case and the present one, it seems reasonable to suggest that the presence of concretions such as those described above, is an additional sign of mechanical intestinal obstruction—either in the small or large bowel.

The fact that all of the concretions were of fairly uniform size and widely distributed suggests that they were formed at approximately the same time. This form of enterolithiasis appears to be associated with the newborn period. Presumably, it is related to the fact that certain special circumstances exist in the intestinal tract of the fetus which are rarely duplicated in later life. In one sense, the gastro-intestinal contents in the fetus are "static" since no material is expelled per rectum. This apparently results normally in the formation of a rectal mucus plug (which in one case reported by Trump (3) was demonstrated to contain calcium). However, stasis within the gastro-intestinal tract is actually not present after the fifth month of fetal life at which time active peristalsis is said to

appear. A large fraction of the intestinal contents in the fetus must be completely absorbed in order to prevent progressive dilatation of the intestinal tract. The presence of a mechanically obstructive lesion in utero, even an anal atresia as in the present case, apparently interferes with normal absorptive and motor processes and permits true stasis and lithiasis to occur. One of the many special circumstances in the fetal gastro-intestinal tract is the presence of swallowed vernix caseosa which, with its high fat content, may play a rôle in the production of insoluble calcium soaps. Swallowed squamous epithelial cells have been found within calcified enteroliths in the newborn. The lucent centers of the concretions may represent such non-opaque cores of epithelial cells or inspissated meconium. However, neither vernix caseosa nor desquamated squamous epithelium appear to be necessary in order that intraluminal calcification may occur since such calcification has been seen distal to a duodenal atresia within strangulated bowel (reported by Neuhauser (4)). Moreover, ring-shaped concretions have been reported by Harland (5) proximal to a post-operative sigmoid stricture in an adult of 42.

From a review of the published cases of enterolithiasis therefore, it is believed that the presence of demonstrable enterolithiasis in the newborn is indicative either of mechanical intestinal obstruction or of gangrenous bowel with stasis of intestinal contents within it.

REFERENCES

1. Walker, A. J.: Cecal Fecolith. Brit. J. Surg., 36: 55, 1948.
2. Camp, R., Roberts, M. H.: Multiple Calcareous Deposits in Intestinal Tract of Newborn. Am. J. Dis. Child., 78: 393, 1941.
3. Trump: Rectaler Schleimepithelpfropf und Darmstenosen bein Neugeborenen. Jahrb. F. Kindesheilk., 76: 678, 1912.
4. Neuhauser, E. B. D.: Roentgen diagnosis of Fetal Meconium Peritonitis. Am. J. Roent., 51: 421, 1944.
5. Harland, D.: A Case of Multiple Calculi in Large Intestine with Review of Subject of Intestinal Calculi. Brit. J. Surg., 41: 209, 1953.

INTRAVENOUS CEREBRAL ANGIOGRAPHY: A TECHNICAL NOTE[1]

BERNARD S. WOLF, M.D., MORRIS B. BENDER, M.D., AND
SIGMUND A. BRAHMS, M.D.

Visualization of the cerebral circulation by injection of aqueous opaque media into the carotid and vertebral arteries has become an accepted and a highly useful diagnostic procedure (1, 2). The possibility of visualizing the cerebral vessels by injection of an opaque medium into a peripheral vein has doubtlessly occurred to many investigators but efforts in this direction have not been publicized. Recent preliminary notes by a group of investigators in Algiers (3) suggested that further exploration of the possibility was indicated.

The technique of injection is identical to that used for angiocardiography. In addition, tourniquets are applied to the 3 other extremities so as to occlude the arterial circulation during the period of injection and filming. An antecubital vein is exposed through a small incision under local anesthesia and a Robb-Steinberg cannula introduced. The hub of the cannula, the attached stop-cock as well as the 50 cc syringe were bored to #12 gauge. The opaque material injected was 70 per cent Urokon. After an intravenous test for sensitivity, 50 cc is injected manually within one second. Serial filming of the head is begun 3 to 4 seconds after the end of the injection. A preliminary determination of the arm to tongue decholin time is made to exclude abnormalities in circulation time.

The results in a small group of cases indicate that intravenous cerebral angiography is a feasible technique (Figs. 1, 2). Injection of more than 50 cc or simultaneous injection into both upper extremities would doubtlessly produce greater opacification but probably with greater risk. The degree of opacification obtained with the technique described is less than with direct arterial injection but appears to be sufficient for many diagnostic purposes.

The anticipated advantages of intravenous versus intraarterial injection include: 1) Simultaneous visualization of all cerebral vessels; 2) Absence of complications due to extravasation into the neck or to manipulation of the carotid or vertebral arteries. Hemiplegia, hemianopsia, aphasia or convulsions have not been seen by us after intravenous injection for angiocardiography; 3) Absence of complications due to accidental injection of air or thrombotic material into the arteries; 4) Visualization of the entire cerebral circulation under more physiological conditions; 5) Greater ease in positioning the head; 6) Less radiation exposure to the operator.

The disadvantages of intravenous injection include: 1) Poorer opacification of the cerebral vessels; 2) The use of larger quantities of opaque material, increasing the incidence of systemic reactions; 3) Greater need for precision timing of exposures; 4) Superimposition of the vasculature of the two sides in the lateral projection. It should be noted that the systemic reactions to 50 cc of Urokon injected as rapidly as possible have been minimal. It is also possible to develop

[1] From the Departments of Radiology and Neurology, The Mount Sinai Hospital, New York, N. Y.

FIG. 1A. Case L. G. AP view taken 7 seconds after end of injection into the left antecubital vein. Left middle and anterior and both posterior cerebral arteries are visualized. Small aneurysm (arrow) along course of left middle cerebral artery. The right common carotid artery was previously ligated.

FIG. 1B. Case L. G. Lateral view taken six seconds after end of injection into left antecubital vein. Left middle cerebral, basilar and both posterior cerebral arteries and left anterior cerebral artery with large pericallosal branch are visualized. Arrow points to aneurysm. Both vertebral arteries and one internal maxillary artery are also demonstrated. The bone defects are due to a burr hole and subtemporal decompression.

FIG. 1C. Case L. G. Lateral view taken 10 seconds after end of injection. Deep and superficial veins are visualized. Aneurysm (arrow) remains filled.

FIG. 2A. Case L. K. AP view taken about 7 seconds after end of injection into the right antecubital vein. Large arterio-venous anomaly deep in the right cerebral hemisphere well demonstrated. The right common carotid artery was previously ligated. Basilar artery, both posterior cerebral arteries, left carotid syphon, and left anterior and middle cerebral arteries filled.

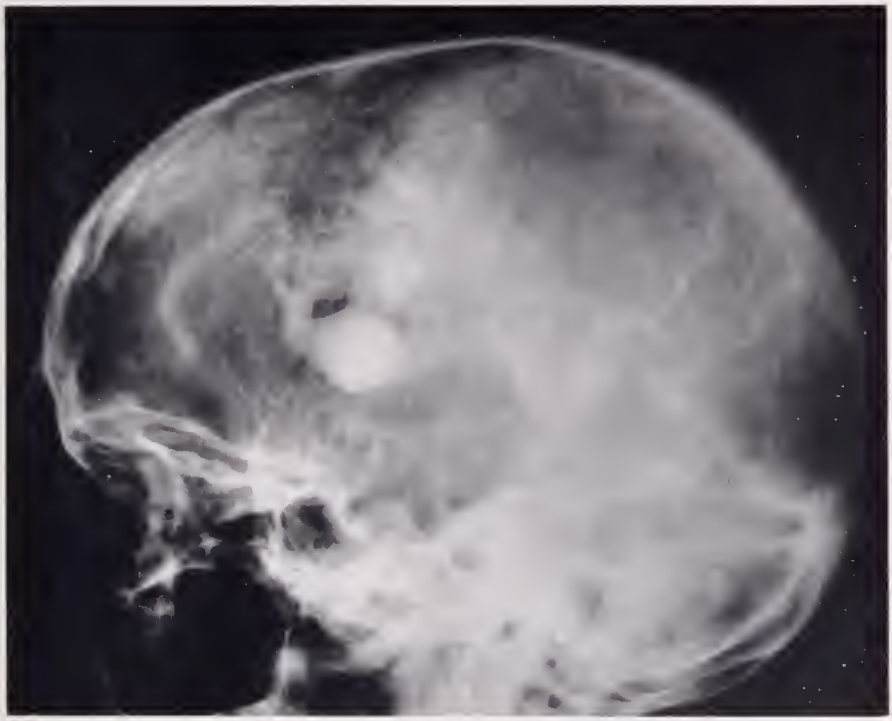

FIG. 2B. Case L. K. Lateral view taken about 9 seconds after end of injection. Anomaly is well demonstrated. Hugely dilated internal cerebral vein, posterior collateral veins to superior longitudinal sinus and dilated anterior portion of inferior longitudinal sinus visualized. The carotid syphon, basilar, posterior communicating and posterior cerebral arteries are simultaneously filled.

automatic timing by triggering serial filming with radioactive isotopes. With a satisfactory AP view, interpretation of the lateral projection should not be difficult. Stereoscopic lateral views may be obtained with suitable equipment or multiple injections. Moreover, there is frequently sufficient difference in the position of the head in serial films to produce some stereoscopic effect.

It is not presently anticipated that intravenous cerebral angiography will replace percutaneous arterial injection. It does however furnish an additional method which may be preferable in some cases such as: 1) In children; 2) In patients with one carotid artery previously ligated or thrombosed; 3) In patients who require vertebral angiography; 4) In studies of disturbances of the cerebral circulation, e.g., cerebrosvascular accidents and after ligations for cerebral aneurysm.

BIBLIOGRAPHY

1. Egas Moniz, A. L'Angiographie Cérébrale: ses Applications et Resultats en Anatomie Physiologie et Clinique. Paris, 6 ed., Masson & Cie, 1934.
2. Ecker, A. The Normal Cerebral Angiogram. Springfield, Charles C. Thomas, 1951.
3. Viallet, M., Viallet, P., Chevrot, L., Sendra, L., Combe, P., Aubaniac, R., Aubry, P., Sarrouy, J., and Keller, T. Nouvelle Methode d'Angiographie. *Algérie Médicale, 59:* No. 2, February 1955.

In Memoriam

ERNST PHILIP BOAS, M.D.

1891–1955

The death of Ernst Philip Boas on March 9, 1955 prematurely deprived mankind of a devoted servant. Born on February 4, 1891, of an illustrious father, he refused to bask in the warmth of reflected glory and shunned reference to this happy circumstance with an intensity equalled only by his love for, and devotion to, the ideals of his father, Franz Boas. This independent spirit with which Ernst Boas made no compromise throughout his years, was one of the cornerstones of his life's structure—a structure built carefully and thoughtfully as he matured. He was motivated by a continuous searching for the truth and wherever his purpose led him, in his medical and social endeavors alike, he was guided intuitively by this basic sense of truth, as also by an uncompromising, intellectual integrity, and by a reverence for tradition. Neither a blind follower nor a revolutionary dispossessor of the past, he respected and borrowed from the past what was sound and useful.

At Columbia's College of Physicians and Surgeons, where he was graduated in 1914, his ability was clearly recognized. After serving his interneship on the wards of the Mount Sinai Hospital he entered the Medical Corps of the Army and served during the years 1917–1918 as a heart specialist. His interest in diseases of the heart was already manifest at this early stage of his development. In 1920 he became Medical Director of the Montefiore Hospital for Chronic Diseases and served until 1929. During this period he made many scientific and clinical studies in the field of heart diseases, and became interested in the need for better community planning for the care of the chronically ill. He published much and gave many addresses throughout the country on this subject. As Chairman of the Committee on Chronic Illness of the Welfare Council of the City of New York he continued the progress made in the public education concerning the needs of the chronic sick. Largely through the efforts and pressures of this committee the Municipal Hospital for Chronic Diseases, on Welfare Island, now known as the Goldwater Memorial Hospital, was constructed. In 1929 he joined the Mount Sinai Hospital staff as Associate Physician, and the teaching staff of the College of Physicians and Surgeons, and served with diligence and esteem in these capacities for 22 years. His retirement from active hospital service in 1951 saw no relaxation in this man's pursuit for medical truth. He immediately plunged, with consummate energy, into the job of directing a large research program, launched by the Sidney Hillman Health Center, and he worked actively and fruitfully with this group to his last days, publishing reports on clinical studies of atherosclerosis. Throughout the period from 1929 to his death he devoted himself largely to a very active private practice in the treatment of cardiac diseases and continued to publish clinical reports and books dealing with heart diseases and

Ernst Philip Boas, M.D.
1891–1955

the care of the chronic sick. An important segment of his life was devoted to the creation, in 1939, and the subsequent development, of the Physicians Forum for the study of medical care, an organ devoted to the improvement of medical care and the adaptation of medicine to social needs and uses. His tireless efforts with the National Committee for Resettlement of Foreign Puysicians helped many victims of Hitlerian brutalitarianism find personal and scientific refuge in a receptive soil. Although secure in his position as an eminent cardiologist and internist, he was driven by an impelling sense of social consciousness to better the welfare of mankind. This took him into many fields; differing facets of his life's work and devotion. In all of these, the qualities and virtues which endeared him to his friends, associates and colleagues were always apparent; his boundless energy and indomitable courage in the fight for just cause, regardless of its popularity; his remarkable selflessness which directed his thoughts and efforts always to others; his warmth of human understanding; his quiet modesty; his deep compassion for the suffering; his regard and respect for the opinions of others.

Throughout the fabric of his medical life runs the thread of his desire and great capacity for teaching. His sound medical judgement, his penetrating analysis of problems of illness, and his fatherly concern with the development of the young physician have endeared him to all his students. A few of them who chose to maintain a close medical relationship with Ernst Boas were the fortunate recipients of this constant source of teaching and inspiration.

Hyman Levy, M.D.

Joseph F. Cullman, Jr.
1883–1955

In Memoriam

JOSEPH F. CULLMAN, JR.

1883–1955

Fifty-eight consecutive years of family service as Trustee of The Mount Sinai Hospital were interrupted by the death of Joseph Cullman, Jr. on March 18, 1955. The tradition that only one member of a family be a member of the Board of Trustees at a time, and the long, fruitful life of his father, Joseph F. Cullman, made his own succession late. This, and his demise at the peak of his powers at seventy-two, cut his tenure relatively short; albeit he served as Trustee some seventeen important years, and as Treasurer of the Hospital for twelve years. The welfare of the Hospital was his heritage, and his interest in the Hospital and service to it long antedated his appointment as Trustee.

It was fitting that he continue the peculiar interest of Joseph Cullman in Medical Education-work which was pathfinding for its time. It was right that he succeed to the Chairmanship of the Committee on Medical Education. The eleven physicians constituting the House Staff in 1897 had mushroomed to almost one hundred (now to two hundred); the small but seminal institution on Sixty-seventh Street had grown to the spreading giant at One Hundredth Street. Lectures, courses, teaching programs had multiplied many times. Formal and informal instruction were now recognized as necessary parts of the training of the doctor. Into every detail of this once visionary but now universally recognized as essential program Joseph Cullman, Jr. threw himself with the lusty vigor and incisive intelligence which characterized his living. A patron of this Journal, who fought almost single-handedly for its survival when the death of its founding editor and his successor within a few months of each other left it tottering, it is proper that we memorialize his passing.

His zest, his joyousness, his strength long will be missed and long remembered.

LESTER R. TUCHMAN, M.D.

CLINICAL EXPERIENCES WITH THE L.E. CELL TEST*

STANLEY L. LEE, M.D.

New York, N. Y.

The L.E. cell test was described in 1948 by Hargraves, Richmond and Morton (1) who reported that L.E. cells had been found in over 25 cases of acute lupus erythematosus. Since that time it has come into wide general use as a diagnostic test for that disease. Although most writers agree that the test is a valuable one, there is considerable disagreement as to the precise degree of reliance which can be placed on it.

Experience at The Mount Sinai Hospital has shown the test to be both sensitive and highly specific. The purpose of this report is to summarize that experience.

MATERIALS AND METHODS

Patients included in this series have been observed in the wards, the outpatient department and the private pavilion of the Mount Sinai Hospital. Data have been collected from June, 1949 (when L.E. cell tests were first done with any regularity in this hospital) through September, 1954; a period of over five years.

From June, 1949 through August, 1950, L.E. cells were routinely searched for in smears prepared from the buffy coat of heparinized peripheral blood (2). Since then clotted blood has been used as a source of L.E. cells. The method, which has been reported previously (3), recently has been modified as follows:

1. 1 to 5 cc of blood is collected in a clean dry test tube, allowed to clot, and incubated in a 37°C. water bath for 2–4 hours.
2. The tube is centrifuged at 1500 rpm for 5 minutes to separate the serum which is then discarded.
3. The clot is broken up with an applicator stick.
4. A small drop of liquid extracted from the clot is spread thinly on a clean glass slide, and stained by the Jenner-Giemsa method.

When the clot test for L.E. cells is doubtful, an indirect method has been employed using washed normal leukocytes (and platelets) incubated with serum from the patient (4). This latter test is useful in any of the following circumstances:

(1) if the clot test gives doubtful results.
(2) if the patient has severe thrombocytopenia.
(3) if the patient has a natural circulating anticoagulant.

RESULTS

Since June 1949, when examinations for L.E. cells were first performed in the Hematology Laboratory, approximately 4200 tests have been carried out on about 1500 patients. Positive tests have been obtained in 72 patients (Table I).

From the Department of Hematology, The Mount Sinai Hospital, New York, N. Y.

* This investigation was supported by a research grant (A-221) from the National Institute of Arthritis and Metabolic Diseases, of the National Institutes of Health, U. S. Public Health Service, and by the A. A. List Fund.

TABLE I

Clinical and Pathological Diagnosis	L.E. Cell Test	
	Positive	Negative
Systemic L.E.	66	1
? Systemic L.E.	6	3
Other diagnosis	0	ca. 1500

Cases of Systemic Lupus Erythematosus

During the same period, the diagnosis of systemic lupus erythematosus has been made 67 times, in as many patients. This diagnosis has been made on the basis of the usual clinical and laboratory evidence. Post-mortem examination has been performed in 20 of the 67 cases, and each time has confirmed the clinical diagnosis.

In 66 of the 67 patients, tests for L.E. cells have been positive (Table I). The test has not been positive in every case every time it has been performed. However, in 64 of the 66 cases, a positive test has been obtained at the time of the initial hospitalization. Many of the patients have continued to have positive L.E. cell tests whenever they have been reexamined. In a few cases the test has been temporarily negative at one time during the course of the disease, but became positive later. Fluctuations in the degree of positivity of the L.E. cell test have followed the clinical course in most cases—when the disease is most active, the test is more markedly positive—but there have been enough exceptions to this type of correlation to render the test of little value as an indicator of activity in an individual case.

Two patients in this series had negative tests during their initial hospitalization periods. In neither of these cases was the indirect test, using normal buffy coat and the patient's serum, performed. One of these patients, (S.S.), a 31-yr. old woman, at the time of her first admission had severe thrombocytopenia which was accompanied by purpura and severe menorrhagia. A splenectomy was performed, her platelets rose to normal, and she was discharged. She returned four months later, still with normal platelets, but complaining of joint pains and fever. The L.E. cell test was then positive.

The second patient, (B.V.) a 28-yr. old woman, entered because of two years of intermittent fever, migratory arthralgias, and weakness. She had albuminuria, microscopic hematuria, anemia, leukopenia, moderate thrombocytopenia, a weakly positive Coombs test, and a biological false positive serologic test for syphilis. Numerous L.E. cell tests were negative. At about this time studies of the relationship of blood clotting to the L.E. cell phenomenon (5) had shown that platelets and thromboplastin were necessary to the phenomenon. A circulating anticoagulant interfering with the action of thromboplastin had been found in two cases of systemic lupus erythematosus (6). It was reasoned that thrombocytopenia in combination with a circulating anti-coagulant of this type might well interfere with the demonstration of L.E. cells even when the L.E. cell factor was actually present. Clotting studies were carried out in this patient and showed

the presence of a circulating anticoagulant which had not caused clinical manifestations. These studies have been reported elsewhere (7). When the indirect L.E. cell test was carried out, with rabbit-brain thromboplastin (Difco) added to the tube, L.E. cells were found. Subsequently the test was repeated without thromboplastin, but with buffy coat from a patient with a very high platelet count, and again it was positive.

Failure to demonstrate L.E. cells in these two patients during their initial hospitalization periods probably represents a failure of technique. Had the relationship between blood clotting and the L.E. cell phenomenon been better understood, and had the indirect test been performed, it is possible that positive tests would have been obtained more rapidly. In one case severe thrombocytopenia, and in the other the combination of thrombocytopenia and anticoagulant, invalidated the simple clot test.

One patient with systemic lupus erythematosus has had negative L.E. cell tests on numerous occasions, and has never been found to have a positive one (Table I).

This patient, E. O., a 16 year old girl, was first seen at the Mount Sinai Hospital in March of 1948 because of fever, joint pains and a facial rash. There was not at that time, nor at any subsequent time during the following 6½ years, anemia, leukopenia, increased erythrocyte sedimentation rate or urinary abnormality. The rash was considered typical of lupus erythematosus by the dermatologists, and a diagnosis of sytemic lupus erythematosus was made. In 1951 she returned to the hospital because of purpura and a petechial eruption of two years duration. Her rash, fever and joint pains had waxed and waned in the interval. She was found to have marked thrombocytopenia, increased bleeding time, absent clot retraction and impaired prothrombin consumption. Blood studies were otherwise normal. Bone marrow aspiration was attempted unsuccessfully; surgical bone marrow biopsy, however, revealed a richly cellular marrow showing no abnormality other than an increase in the number of megakaryocytes and decreased platelet formation. After splenectomy was performed, there occurred a prompt rise in platelet count to normal levels, and concomitant cessation of bleeding.

Her course since splenectomy has been marked by the same intermittent joint pains, fever and recrudescence and remission of her rash, as during the early stages of her disease. Her platelet count has continued to be normal, and all laboratory investigations have shown no abnormality.

Histology of the spleen removed at operation was typical of systemic lupus erythematosus. There was very marked "onion skin" peri-arterial fibrosis. No hematoxylin-staining bodies were seen however.

The test for L.E. cells was first attempted on this patient in April, 1948, using bone marrow as in Hargraves' original report. No L.E. cells were found then. On at least eight subsequent occasions the test has been performed by all three of our methods, always with negative results.

Doubtful Cases

There have been, during the period of this study, three additional patients in whom the diagnosis of systemic lupus erythematosus has been strongly suspected, and in whom the test foe L.E. cells has been consistently negative (Table I). In patient E. O., cited above, there was histologic proof of the diagnosis. In the other three no such proof is available.

Six other patients, in the opinion of most clinical observers, did not have systemic lupus erythematosus, but showed positive L.E. cell tests at one time or another (Table I). Each one of these cases had one or more features known to be associated with systemic lupus: I. S., a man of 47, had acquired hemolytic anemia and a positive Wassermann test. F. S., a woman of 48, had an unusual hemolytic anemia, arthralgias, fever and a biologic false positive serologic test for syphilis. C. C., a man of 45, has crippling rheumatoid arthritis. M. M., a woman of 47, has anemia, leukopenia, and thrombocytopenia, a circulating anticoagulant, a facial rash and epilepsy. B. R., a woman of 40 with a proved diagnosis of interstitial pulmonary fibrosis (Hamman-Rich disease) has recently developed arthralgias, fever, and a butterfly facial rash. M. S., a 60 yr. old man with epileptiform convulsions, leukopenia, and monocytosis was thought to have systemic lupus over a period of a year, but has recently developed a frank myeloblastic leukemia.

Cases with Positive L.E. Cell Tests and Diagnosis Other than Systemic Lupus Erythematosus

In the entire series of about 4200 tests, positive tests were not obtained in any patients with diagnoses other than systemic lupus, except for the six doubtful cases discussed above (Table I).

Special efforts were made to perform L.E. cell tests on patients with penicillin hypersensitivity, multiple myeloma, pernicious anemia in relapse, miliary tuberculosis and apresoline-treated hypertension (only a few patients of this last category have so far been tested, however).

DISCUSSION

In an attempt at evaluation of the L.E. cell test, it is difficult to avoid circular reasoning. The prestige of the test is great, and there is a tendency on the part of internists to accept it as a pathognomonic sign. Diagnoses based entirely or largely on this test in the absence of other criteria for systemic lupus, ought not to be used as evidence for the diagnostic value of the L.E. cell. The attempt has been made, in the present series, to obviate this difficulty by rigid exclusion of those cases in which evidence of lupus other than the L.E. cell was unconvincing. Such cases were placed in the "doubtful" category. Of the remaining 67 cases of systemic lupus erythematosus, 66 have had positive tests. In several of these, the diagnosis was made on the basis of this test, and confirmed by subsequent events. Admission diagnoses in some of these cases have included subacute bacterial endocarditis, nephrotic stage of chronic glomerular nephritis, acute glomerular nephritis, acute thrombocytopenic purpura, acquired hemolytic anemia, pleurisy with effusion, chronic encephalitis, Hodgkin's disease and rheumatoid arthritis. In every case, however, subsequent events clarified the diagnosis and established it as systemic lupus erythematosus.

Although, in our experience so far, no positive L.E. cell tests have been obtained in patients proved not to have systemic lupus erythematosus, the test should not be used as pathognomonic evidence of the disease. No relationship

other than an empiric one has yet been established between the L.E. cell phenomenon and other manifestations of systemic lupus. Until such time as the relationship of the L.E. cell phenomenon to the pathologic process in lupus is defined, the test must be used as, for instance, the Wassermann test is used in the diagnosis of syphilis; as an important aid, but not the *sine qua non* in diagnosis.

SUMMARY

Experience with the L.E. cell phenomenon at The Mount Sinai Hospital has been summarized. In a total of about 4200 tests, positive findings have been shown in 72, 66 of which had systemic lupus erythematosus. Evidence in the remaining six cases was suggestive, but not diagnostic of systemic lupus. In none of the six was another diagnosis apparent which would satisfactorily explain all the findings. No proved "false positive" L.E. cell tests have been encountered. One case of proved systemic lupus has had consistently negative tests.

BIBLIOGRAPHY

Hargraves, M. M., Richmond, H., and Morton, R. J.: Presentation of Two Bone Marrow Elements: the "Tart" Cell and the "L.E." Cell. Proc. Staff Meet. Mayo Clin., 23: 25, 1948.

Lee, S. L., Michael, S. R., and Vural, I. L.: The L.E. (Lupus Erythematosus) Cell: Clinical and Chemical Studies. Am. J. Med., 10: 446, 1951.

Lee, S. L.: A simple Test for L. E. Cells. Am. J. Clin. Path., 21: 492, 1951.

Kurnick, N. B., Schwartz, L. I., Pariser, S., and Lee, S. L.: A Specific Inhibitor for Human Desoxyribonuclease and an Inhibitor of the Lupus Erythematosus Cell Phenomenon from Leucocytes. J. Clin. Invest., 32: 193, 1953.

Lee, S. L., Schwartz, L. I., and Pariser, S.: Blood Coagulation and the L.E. Cell Phenomenon. Blood, 9: 965, 1954.

Conley, C. L., and Hartman, R. C.: A Hemorrhagic Disorder Caused by Circulating Anticoagulant in Patients with Disseminated Lupus Erythematosus. J. Clin. Invest., 31: 621, 1952 (abst.).

Lee, S. L., and Sanders, M.: A Disorder of Blood Coagulation in Systemic Lupus Erythematosus. Clin. Res. Proc., 2: 33, 1954.

GENERALIZED HERPES ZOSTER INITIATING A MINOR EPIDEMIC OF CHICKENPOX

HOWARD L. MOSCOVITZ, M.D.

New York, N. Y.

The peculiar relationship between herpes zoster and varicella has been repeatedly pointed out since von Bokay (1) in 1888 first suggested the etiologic similarity between the two diseases. Since that time a large number of observations in epidemiologic, immunologic and morphologic fields have served to focus attention on the problem, but have not completely clarified it.

In the epidemiologic sphere, there are numerous examples of varicella rising from contact with cases of herpes zoster (2–7). The reverse situation, namely, herpes zoster contracted from varicella is more unusual, but such reports have appeared (2, 4, 7, 8, 9). Small epidemics of zoster occasionally occur (10, 11). Von Bokay in analyzing the incidence of this disease over a ten year period in Budapest found a regularly occurring zoster peak one month before the varicella peak. Rivers and Eldridge (12) in New York, disagree with these findings. Studies of the incidence of herpes zoster in isolated communities appear to cast doubt upon the identity of the two viruses. Cantor (13) reported that zoster is quite common on Christmas Island, while varicella is unknown. Wooley (14) found, on the island of Tristan da Cunha, that cases of zoster failed to give rise to any varicella although the population must have been susceptible to chickenpox, since it had never been seen there. On the other hand, Peterson and Black (15) describe varicella apparently due to exposure to zoster in an isolated community on Shetland Island where it was unlikely that other sources of varicella could have been overlooked. Twenty outbreaks of chickenpox which could be traced to cases of zoster, were studied by the British School Board (7). The attack rate was found to be only 0.97% in such cases, while a varicella initiated outbreak showed an attack rate of 3.86%. No significant statistical difference could be detected with reference to a past history of chickenpox when a group of children with herpes zoster were compared with a group of control children. This may be taken as evidence that zoster is not merely an altered clinical manifestation of the same virus in a patient who has previously had chickenpox, and that chickenpox does not immunize against zoster. It appears, however, that varicella in children is more often responsible for zoster in exposed adults, than in exposed children (16).

Experimental inoculation studies, both human and animal, are widely quoted to emphasize the identity of the viruses of chickenpox and herpes zoster. Kundratitz (17) inoculated 28 normal children with the fluid taken from the vesicles of cases of zoster. Seventeen of the children developed local papules and vesicles, 9 to 12 days later, while three children came down with typical varicella. Inoculation of children with a past history of chickenpox failed to produce lesions.

From the Department of Medicine, The Mount Sinai Hospital, New York, N. Y.

Kundratitz reported that the children thus inoculated with zoster fluid were later immune to injections of varicella fluid. Abramson (18) reports a similar experience, however, Landa and Stöhr (19) could not reproduce these results. Bruusgaard (20) produced varicella-like vesicles at the site of inoculation of zoster fluid into one child, and then was able to produce a generalized varicelliform eruption 14 days later in a second subject. This latter child's brother developed typical varicella 14 days later. In contrast, it appears that adults are not susceptible to skin inoculation with zoster fluid (21). Animal experiments have been less definitive (22–24). Stokes (16), after reviewing the evidence, feels that there is no conclusive evidence that any animal host outside of man is clearly susceptible to either of the infectious agents.

Immunologic studies appear to have demonstrated a definite similarity between zoster and chickenpox although their antigenic identity is by no means accepted as proven (12). Using zoster vesicle fluid or varicella crusts as an antigen, equally good complement fixation was obtained in the presence of either zoster or varicella convalescent serum (3, 25, 26). Zoster and varicella fluid both agglutinate zoster elementary bodies, but zoster serum agglutinated varicella elementary bodies to a somewhat lower titre than zoster elementary bodies. One postulated explanation for this phenomenon is that the viruses may elaborate soluble antigens detectable by the methods of complement fixation, but which are not recognizable by the technique of agglutination.

Morphologically, the vesicles in the two diseases appear identical on microscopic section, as do the inclusion bodies (27, 22). These elementary bodies of varicella, as seen under the electron microscope, first described by Ruska (28) in 1943 and independently by Nagler and Rake (29, 30), are indistinguishable in size and shape from herpes zoster bodies.

The following case report describes a minor epidemic of classical chickenpox, involving a group of 14 adults, initiated by a case of generalized herpes zoster. The sole secondary case of herpes zoster which may have been contracted from exposure to the original source case was the only individual in the entire group studied who had previously had chickenpox.

CASE REPORT

S. M., a 67 year old white housewife, first became ill with severe, generalized pruritus two years before her final admission to Mount Sinai Hospital. At the onset of her illness, her skin apparently had been normal, but within a few months diffuse erythema and induration involving the skin of the anterior chest wall and upper extremities appeared. Six months later, a skin biopsy was performed at another hospital and this was reported to show mycosis fungoides. At that time the peripheral blood count was normal. She was given small doses of radiotherapy to the involved areas of skin over a period of four months, without relief. She was first admitted to Mount Sinai Hospital in March of 1952, a chronically ill patient with severe and intractable generalized pruritus. There was diffuse lymphadenopathy; the nodes were firm and measured about 1–2 cm. in diameter. The liver was moderately enlarged but the spleen could not be felt. The skin was erythematous, thickened and indurated and was covered with excoriations. The cutis was universally involved except for the face, lower legs and sub-mammary areas.

Laboratory examination at that time, revealed a hemoglobin of 10 Gm.% and a leukocyte

count of 137,000 per cu. mm. The differential white count showed that 90% of the cells were of the lymphocytic series and blast forms ranged from 4 to 34% on several occasions. The platelets were depressed to 70,000 per cu. mm. The bone marrow was infiltrated with 78% lymphocytes and 6% blasts. A lymph node biopsy at that time was reported as compatible with the diagnosis of chronic lymphatic leukemia.

Therapy was begun with nitrogen mustard. A total dose of 0.4 mgm per kilogram was administered intravenously. There was no appreciable change in her clinical or hematologic status and the white count remained elevated at 60,000 per cu. mm. The patient was placed on a maintenance dose of 100 mgms of oral cortisone daily and discharged to the out-patient department, not significantly improved. In the subsequent five months she received six blood transfusions. One week before her second and last admission to the hospital in Nov. 1952, there developed a burning skin eruption over the right side of the forehead, scalp and right eye which resulted in complete closure of the eye. For this reason she sought re-admission to the hospital.

Physical examination revealed a temperature of 100°, Resp. 20/min., P.R. 88/min. B. Pr. 150/90 mm. Hg. There was marked evidence of weight loss. A vesicular, partially necrotic, crusted and weeping skin lesion typical of herpes zoster was noted in the distribution of the first division of the right trigeminal nerve. Both lids of the right eye were edematous and completely occluded the palpebral fissure. No corneal ulceration was seen. The nose was uninvolved. There was a moderate generalized lymphadenopathy. Heart and lungs were

FIG. 1. The appearance of the patient after generalization of the herpes zoster ophthalmicus had taken place. Note the universal distribution and the hemorrhagic character of the rash.

FIG. 2. Close-up view of the disseminated vesicular lesions on the forearm. The vesicles appear uniform in size and age and a central umbilication can be seen.

FIG. 3. Appearance of the patient's face demonstrating the necrotic change in the herpes zoster lesion over the distribution of the first branch of the right trigeminal nerve.

normal. The liver was large and firm and extended six fingers below the right costal margin. The spleen could not be felt. The skin revealed the same diffuse, chronically lichenified condition which had been noted on the previous hospital admission. No satellite or disseminated vesicular lesions were noted apart from the previously described herpes zoster ophthalmicus.

Laboratory examination showed a hemoglobin of 6.3 Gm.% and a white blood count of 160,000 per cu. mm, with 97% lymphocytes and one blast. Platelet count was 20,000 per cu. mm.

Two days after admission to the hospital, the first satellite vesicular lesion was seen on the anterior chest. Within the course of 24 hours, the skin became covered with innumerable umbilicated, purplish-red, tense vesicles and small bullae. No area was spared, including the



A

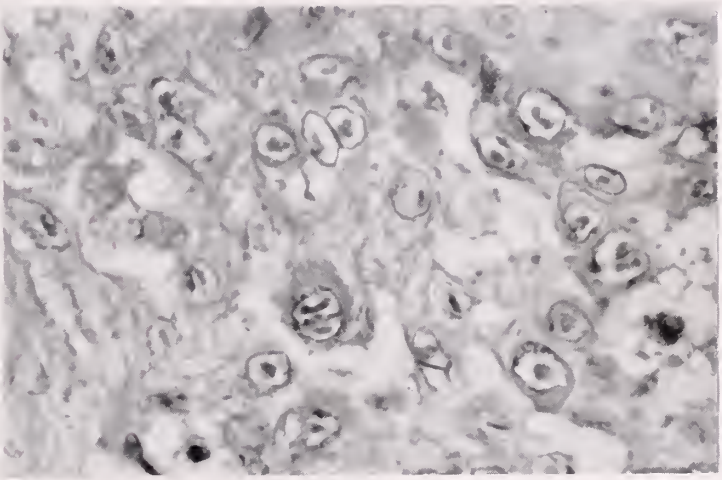

B

Fig. 4. Histologic sections of the skin lesion. a. Low power view of a typical vesicle. b. High power view demonstrating the marked ballooning of the cells and the characteristic inclusion bodies.

palms and soles (Fig. 1 and 2). The area of the original herpes zoster ophthalmicus had now become completely blackened, crusted and necrotic (Fig. 3). Aspiration of the larger bullae yielded sero-sanguinous fluid which on stained smear revealed balooned-out epithelial cells containing eosinophilic inclusion bodies.

It appeared that the patient had developed generalized herpes zoster in the course of chronic lymphatic leukemia. The degree to which maintenance cortisone therapy had altered the clinical picture was difficult to evaluate. At the time alternate diagnoses of hemorrhagic smallpox and hemorrhagic leukemia cutis were seriously considered. The patient was treated with large doses of penicillin and aureomycin and was given several blood transfusions. Her temperature rose to 104°, she became severely toxic and died one week after the appearance of the disseminated eruption.

Post-mortem examination revealed findings of chronic lymphatic leukemia with involvement of lymph nodes, bone marrow, liver, kidney and spleen. The skin showed areas of vesicle formation well-demarcated in the epidermis containing serosanguinous fluid with many ghost cells (Fig. 4). The prevesicle stage, microscopically, showed epidermal cells which were distorted and swollen with eosinophilic nuclear inclusions and occasional multinucleated cells. No leukemic infiltration was seen in the skin, nor in the nerve roots or ganglia that were studied.

THE OUTBREAK

Much of the mystery concerning the diagnosis was dispelled when a series of undoubted and classical cases of chickenpox appeared among the patient's contacts. Three days after her death and 10 days after the appearance of the disseminated eruption, a grandchild of the patient developed chickenpox. Two days later, the admitting interne on the patient's ward developed chickenpox as did the interne in the admitting room. No other cases of chickenpox had been recognized in the admitting room during that time. One day later, the resident on the patient's ward and one interne on the ward below developed varicella. Fluid was aspirated from this resident's vesicles and sent to the virology laboratory for study. On that same day, a dietician who visited the patient's ward daily developed chickenpox. Two days later, a patient from another ward, who frequently visited the source case's ward came down with mild chickenpox, as did two messenger boys. Two nurses, one in the diet kitchen and one in the cystoscopy department developed chicken-pox 2 days later. A virology technician who received vesicle fluid taken from the patient's resident developed chickenpox 14 days after receipt of the fluid. On this same day, a patient with myasthenia gravis on the ward one floor above developed herpes zoster in the distribution of the six right intercostal nerve. This latter patient definitely recalled having had childhood chickenpox. Two additional cases of chickenpox occurred in patients on the original patient's ward, 22 and 33 days after the appearance of her disseminated, hemorrhagic rash. These latter two cases were probably secondarily exposed via members of the staff, rather than directly to the source case. Close questioning of all of the cases in the outbreak revealed no prior history of chickenpox in any of them, with the sole exception of the patient with myasthenia gravis who developed herpes zoster. The outbreak is shown diagrammatically in Fig. 5.

The vesicle fluid obtained from the patient's resident physician was inoculated on rabbit cornea. No lesions were produced, minimizing the possibility of small-

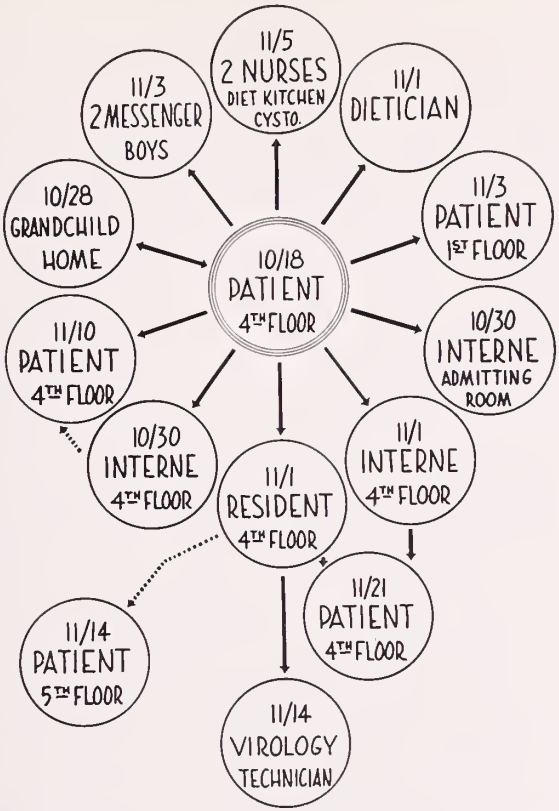

FIG. 5. Diagramatic summary of the outbreak. See text for explanatory remarks.

pox. The fluid was injected into the chorio-allantoic sac of chick embryo and into mouse brain, but no recognizable virus growth was detected. Examination of the fluid with the aid of the electron microscope demonstrated no elementary bodies, although the routine stained smear of the vesicle fluid revealed characteristic inclusion bodies. While the laboratory studies did not identify the infectious agent they appeared to have ruled out smallpox, vaccinia and herpes simplex. It has been pointed out that neither the infectious agent of herpes zoster nor chickenpox has been regularly cultivated in the laboratory, as yet (16).

COMMENT

The prevailing concept of "generalized herpes zoster" is that this disease entity occurs following the widespread dissemination of vesicles in a patient with the usual type of localized herpes zoster. It may result from infection with a strain of zoster virus possessing marked dermotropic properties (21). The possibility exists that this syndrome may, at times represent a double infection of concurrent zoster and varicella, in a single individual (31, 32, 8). This appears to be unlikely, as a general rule, because of the decided tendency of herpes zoster to

become generalized in a particular type of disease state. An unusually high percentage of the reported cases of generalized herpes zoster have occurred in patients with chronic lymphatic leukemia (33–38), and to a lesser extent in the other lymphomata. Ferreira (34) collected 42 cases of herpes zoster associated with leukemia; in 23 of these, herpes zoster was generalized. In Bafverstedt's experience, where herpes zoster and leukemia occurred together, 58% were of the generalized type of herpes zoster (36). Craver and Haagenson (33) studied a group of cases of herpes zoster in patients with Hodgkins disease, lymphosarcoma and leukemia and found that 50% were generalized. Wile and Holman (37) reviewed the literature and found that where a definite type of leukemia was specified as the underlying disease in association with generalized herpes zoster, lymphatic leukemia constituted 93% of the group. It is far from clear why herpes zoster tends to disseminate in patients with leukemia, especially of the chronic lymphatic type. It has been postulated that leukemic infiltration of the dorsal root ganglia or localization of the zoster virus within the skin leukemids are responsible for the generalization, but pathologic proof of such mechanisms is rare. In the occasional case where leukemic infiltration is found in the zosteriform lesion (38), it is possible that the herpetic lesion merely serves as the traumatic stimulus allowing a secondary infiltration of leukemic cells into the affected site.

The pathologic study of the skin lesions in this case revealed no evidence of leukemic infiltration of the skin, including the areas of the generalized vesicular lesions. No infiltration of the dorsal root ganglia was detected in this case. Eisenbud (39) reviewed the literature, and added a case of chickenpox in which visceral involvement with typical intranuclear inclusion bodies was found. None were seen in the case reported here.

Study of the epidemiologic chart of the outbreak of chickenpox (Fig. 5) leads to some definite conclusions concerning the incubation period. The average time between exposure and the appearance of the skin rash, both in the cases of varicella which developed after direct contact with the patient with generalized herpes zoster, and in the secondarily exposed patients was 12 to 13 days. Perhaps the best index of the incubation period was the time interval between Nov. 1 and Nov. 14. This was the period that elapsed between the delivery of the vesicle fluid, taken from the resident who developed varicella, to the virology technician and the appearance of this technician's rash. The virology laboratory is in an entirely different building of the hospital and this technican had no direct contact with the wards. Fisher (40) summarized the reports on the incubation period of cases of varicella contracted from herpes zoster and found this to vary from 10 to 21 days.

One patient in particular deserves additional comment. This is the patient on the floor above who developed herpes zoster, roughly two weeks after the outbreak of varicella had appeared among the hospital personnel. This was a 38 year old woman with myasthenia gravis. She was examined daily by the interne and resident staff who had free contact with the floor below. She gave a clear history of childhood chickenpox and was the only individual in the group involved

in the outbreak to give such a history. She developed zoster 26 days after the patient's rash first appeared, possibly through contact with one of the residents who visits both of these floors. There is no certain way of knowing whether her zoster was purely fortuitous or did actually result from secondary exposure to the case of generalized herpes zoster. It must be pointed out that she was one of the least exposed of the entire group. However, her inclusion in the outbreak would complete the cycle of zoster progressing to generalized zoster, leading to an outbreak of varicella, and finally a single case of herpes zoster.

McEwen (41) described four major classifications of herpes zoster-varicella disease.

1. Cases in which chickenpox developed from contact with herpes zoster.
2. Cases of localized herpes zoster becoming generalized in the same individual.
3. Cases of generalized herpes zoster followed by varicella in their contacts.
4. Cases in which herpes zoster developed from contact with chickenpox.

McEwen found that fully two-thirds of the cases fell into group 1. Group 3 is interesting because it is so rare. McEwen (41) and Shelmire and Shelmire (42) could find only 7 such cases in reviewing the literature, and the latter authors feel that examples of group 3 are the rarest of zoster-varicella disease. If the true nature of "generalized herpes zoster" were in fact varicella and zoster occuring coincidentally in a single patient, one would expect a similar secondary attack rate to that of cases of ordinary varicella (43). Barker (35) in 1939, could find less than 20 well authenticated cases falling into group 4. Certainly the case reported here falls into group 3 and if the additional case of herpes zoster in the patient with myasthenia gravis was also causally related, we would have the distinct rarity of a combination of groups 3 and 4. This combination would result in the cycle of:

$$\text{herpes zoster} \longrightarrow \text{generalized zoster} \longrightarrow \text{varicella} \begin{cases} \nearrow \text{varicella} \\ \searrow \text{zoster} \end{cases}$$

An unusual feature of the outbreak was the high percentage of adults, all but one of whom were above the age of eighteen years. No chickenpox had been recorded in the hospital emergency room during this period and no cases of varicella were hospital in-patients at that time, including the pediatric service. The experience of many physicians with extensive clinical observation of exanthematous disease is that varicella in adult life is unusual, although by no means rare (16, 44). An atypical case of adult chickenpox occasionally can be confused with smallpox and an interesting historical anecdote concerning a procedure practiced in Holland to deal with this problem is provided by Snapper (45). Recognizing the uncommon occurrence of chickenpox in adults and realizing the difficulty of diagnosing the initial, often atypical cases of smallpox, before an epidemic had started, van den Bergh instituted the following practice in the Municipal Hospital in Rotterdam. This large municipal hospital had special

wards containing bed upon bed of "catheter men", since no effective operation for benign prostatic hypertrophy yet existed. Van den Bergh made a regulation that all children and all adult males, suffering from what appeared to be chickenpox had to be admitted to the prostatic ward and placed between the beds of these elderly hospital boarders. These greybeards had, in the course of their long lives acquired immunity against chickenpox. Therefore, whenever one of these old gentlemen contracted a rash which appeared to be "chickenpox", the possibility arose that this was in actuality an atypical case of smallpox and an immediate laboratory and epidemiologic investigation was carried out. In this way it was possible to detect the first atypical cases, possibly heralding an epidemic of smallpox. During the years that van den Bergh was chief physician of the Municipal Hospital in Rotterdam this city never had an epidemic of smallpox and the harbor was never quarantined, saving the parsimonious Hollanders from untold financial loss.

The question arises as to whether herpes zoster should be considered a contagious disease and isolation technique carried out on general medical wards. It should be pointed out that outbreaks such as the one described are rather rare. It is therefore not suggested that herpes zoster be handled as though it were highly communicable. However, it would seem wise to restrict the contacts of cases of generalized herpes zoster to those members of the hospital staff who have had a prior history of chickenpox.

SUMMARY

A case of generalized herpes zoster occurring in a patient with chronic lymphatic leukemia is presented. An outbreak of chickenpox in a group of hospital personnel apparently initiated by the patient with generalized herpes zoster is described.

BIBLIOGRAPHY

1. von Bokay, J.: Über den aetiologischen zusammenhang varizellen mit gewissen faellen von herpes zoster. Wein. Klin. Wchnschr., 22: 1323, 1909.
2. Le Feuvre, W. P.: A Plea for the Recognition of a Common Origin for Shingles and Chickenpox. Brit. J. Derm., 29: 253, 1917.
3. Netter, A. and Urbain, A.: Les relations du zona et de la varicelle: étude serologique de cent cas de zona. Compte Rend. Soc. de Biol., 94: 98, 1926.
4. Netter, A. and Urbain, A.: Le virus varicello-zonateux. Ann. Inst. Pasteur., 46: 17, 1931.
5. Blatt, M. L., Zeldes, M. and Stein, A. F.: Chickenpox following Contact with Herpes Zoster. J. Lab. and Clin. Med., 25: 955, 1940.
6. Weigand, C. G.: Varicella Developing after Contact with Herpes Zoster. Am. J. Dis. Child., 63: 1130, 1942.
7. School Epidemics Committee of Great Britain: Epidemics in Schools. Medical Research Council, Special Report Series No. 227, London, His Majesty's Stationery Office, 1938.
8. Sharpe, G. A.: A Case of Concurrent Herpes Zoster and Varicella. Brit. Med. J., 1: 916, 1946.
9. Horton, S. H., Jr.: Herpes Zoster following Exposure to Varicella; Treatment of Herpes Zoster with Cowpox vaccine. U. S. Naval Med. Bull., 48: 747, 1948.
10. Cookson, H. A.: Four Cases of Herpes Zoster. Lancet, 1: 901, 1924.

11. Spillane, J. D.: Bell's Palsy and Herpes Zoster. Brit. Med. J., 1: 236, 1941.
12. Rivers, T. M. and Eldridge, L. A.: Relation of Varicella to Herpes Zoster. J. Exp. Med., 49: 899, 1929.
13. Cantor, S. J.: Herpes and Varicella. Brit. Med. J., 2: 508, 1921.
14. Wooley, E. J. S.: Herpes Zoster in an Isolated Community. Brit. Med. J., 1: 392, 1946.
15. Peterson, P. H. and Black, S. A. B.: Varicella Herpetiformis. Brit. Med. J., 1: 762, 1946.
16. Stokes, J., Jr.: Varicella-herpes Zoster Group, in: Viral and Rickettsial Diseases of Man; edited by Thomas M. Rivers, Phila., J. B. Lippincott Co. 1952.
17. Kundratitz, K.: Experimentelle uebertragungen von herpes zoster auf den menschen und die beziehungen von herpes zoster zu varicellen. Monatschr. f. Kinderh., 29: 516, 1924.
18. Abramson, A. W.: Varicella and Herpes Zoster; an Experiment. Brit. Med. J., 1: 812, 1944.
19. Lauda, E. and Stöhr, D.: Zur frage des varicellösen (Bokay). Monatschr. Kinderh., 34: 97, 1926.
20. Bruusgaard, E.: The Mutual Relation between Zoster and Varicella. Brit. J. Derm. and Syph., 44: 1, 1932.
21. van Rooyen, C. E. and Rhodes, A. J.: Virus Diseases of Man. 2nd Ed., New York, Thomas Nelson and Sons, 1948.
22. Lipschutz, B.: Untersuchungen über die aetiologie der krankheiten der herpes-gruppe (herpes zoster, herpes genitalis, herpes febrilis) Arch. F. Dermat. U. Syph., 136: 428, 1921.
23. Cole, R. and Kuttner, A. G.: The Problem of the Etiology of Herpes Zoster. J. Exp. Med., 42: 799, 1925.
24. Eckstein, A.: Klinische und experimentelle Untersuchungen zur Frage der Varicellenencephalitis. Ztschr. F. D. Ges. Neurol. U. Psychiat., 149: 176, 1933.
25. Netter, A. and Urbain, A.: Zonas varicelleux; anticorps varicelleux dans le sérum de sujets atteints de zona; anticorps zosteriens et anticorps varicelleux dans le serum de sujets atteints de varicelle. Compte. Rend. Soc. de Biol., 90: 189, 1924.
26. Amies, C. R.: Elementary Bodies of Zoster and Their Serological Relationship to Those of Varicella. Brit. J. Exp. Path., 15: 314, 1934.
27. Paschen, E.: Vergleichende Untersuchungen von Varicellen, Variola, Sharlach, Masern und Röteln. Deutsch Med. Wchnschr., 43: 746 (1917).
28. Ruska, H.: Ziele und Erfolge der Übermikroskopie in der Medizinischen Forschung. Scientia, 37: 16, 1943.
29. Nagler, F. P. O. and Rake, G.: The Use of the Electron Microscope in the Diagnosis of Variola, Vaccinia and Varicella. J. Bact., 55: 45, 1948.
30. Rake, G., Blank, H., Coriell, L. I., Nagler, F. P. O. and Scott, T. F. M.: The Relationship of Varicella and Herpes Zoster: Electron Microscope Studies. J. Bact., 56: 293, 1948.
31. Goldberg, B. and Frances, F. D.: Herpes Zoster, J. A. M. A., 70: 1061, 1918.
32. Letters, Notes and Answers. British Medical Journal, 2: 115, 194, 327, 550, 1944.
33. Craver, L. F. and Haagenson, C. D.: Note on the Occurrence of Herpes Zoster in Hodgkin's Disease, Lymphosarcoma and the Leukemias. Am. J. Cancer, 16: 502, 1932.
34. Ferreira, M. J.: Herpes Zoster Generalisatus bei Leukamie. Arch. f. dermat. u. Syph., 176: 295, 1937.
35. Barker, L. P.: Generalized Herpes Zoster; Report of 9 Cases. Arch. Derm. and Syph., 40: 974, 1939.
36. Bafverstedt, B.: Herpes Zoster Generalizatus und Leukämische Lymphadenose. Acta dermat.-venereol., 21: 60, 1940.
37. Wile, V. J. and Holman, N. H.: Generalized Herpes Zoster Associated with Leukemia. Arch. Derm. and Syph., 42: 587, 1940.

38. Barton, R. L. and O'Leary, P. A.: Herpes Zoster Generalisatus Associated with Chronic Lymphatic Leukemia. Arch. Derm. and Syph., 51: 263, 1945.
39. Eisenbud, M.: Chickenpox with Visceral Involvement. Amer. J. Med., 12: 740, 1952.
40. Fischer, A. E.: Herpes Zoster and Disseminated Vesicles (Varicella?) J. Ped., 2: 301, 1933.
41. McEwen, E. L.: The Association of Herpes Zoster and Varicella. Arch. Derm. and Syph., 2: 205, 1920.
42. Shelmire, J. B. and Shelmire, B.: Concurrent Herpes Zoster and Varicella. Arch. Derm. and Syph., 17: 687, 1928.
43. Seiler, H. E.: A Study of Herpes Zoster Particularly in its Relationship to Chickenpox. J. Hygiene, 47: 253, 1949.
44. Schamberg, J. F.: Chickenpox, in Nelson loose-leaf medicine. Vol. II p. 137. New York. Thomas Nelson and Sons, 1946.
45. Snapper, I.: Personal communication.

RADIOACTIVE COLLOIDAL GOLD: A SIMPLE AND SAFE TECHNIQUE FOR ITS ADMINISTRATION*

NORMAN SIMON, M.D. AND JACK MELAMED, M.D.†

New York, N. Y.

Radioactive colloidal gold is a useful drug in the treatment of serous effusions due to cancer, but technical difficulties limit the ease of use of this isotope. Personnel must be protected from the high energy gamma radiation emitted by Au-198, and spillage of the radioactive colloidal gold solution must be avoided. A number of workers have reported suitable methods of administering radioactive colloidal gold (1, 3–7).

During the past three years one hundred patients with effusions due to malignant tumor have been treated with radioactive gold at The Mount Sinai Hospital. A simple and safe technique utilizing expendable material has evolved from this experience. Using this technique no member of the team administering gold has received more than three milliroentgens of total body radiation in a single treatment. The safety of the procedure is in great part due to the simplicity of the system. In earlier cases treated at this hospital with other reported techniques, personnel received considerably more than three milliroentgens at each administration, and accidental spillage occurred in three instances.

The present method of administration of Au-198 displaces gold from a lead-shielded bottle into the patient by saline solution from an elevated bottle (Fig. 1).

As indicated in Figure 1, a bottle of saline solution [1] is connected to a plastic expendable Venopak no. 4422 [2] and then suspended about one meter above the patient. The lower end of this plastic tube is attached to a female connector [A] of a three-way stopcock [4] containing one male [C] and two female connectors [A and B]. A 50 cc. syringe [3] is attached to the other female connector [B] of the three-way stopcock, and a Venotube no. 4429 plastic tube [5] fits on the male connector [C]. The other end of the Venotube [5] holds a 15 gauge three inch needle [6] whose point is inserted through the rubber cap of the bacterin bottle [10] to lie in the air chamber above the gold solution. Before insertion of the needle [6] the pinch clamp [a] is closed tightly to prevent back flow of gold solution which may be under pressure. Spattering is avoided by inserting the needle [6] through a sterile gauze pad before plunging it into the bacterin bottle [10].

A Donopak plastic tube [8] is connected to a needle [9] which had been inserted previously into the pleural cavity for thoracentesis. The other end of this Donopak tube [8] is attached to a needle [7], 15 gauge and 3 inches long, which is

From the Departments of Radiotherapy and Physics, The Mount Sinai Hospital, New York, N. Y.

* Items 1, 2, 5, 8, 10, and 11 in Figure 1 and item 11 in Figure 2 are supplied by Abbott Laboratories of Chicago, Illinois. Items 4 in Figure 1 and items 10 and 13 in Figure 2 are supplied by Becton and Dickinson of Rutherford, New Jersey.

† Present Address: Michael Reese Hospital, Chicago, Ill.

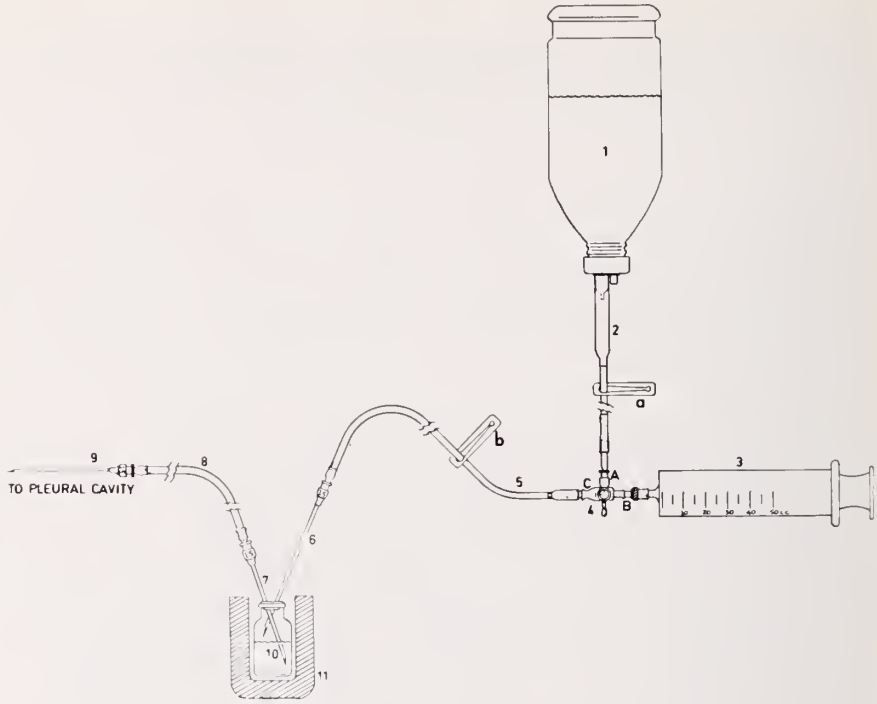

FIG. 1

pushed through a gauze pad and the rubber top of the bacterin bottle [10] to reach the bottom of the gold solution in the bottle.

At this time the pinch clamps [a and b] are opened, and the valve on the three-way stopcock is turned to direct the flow of saline solution from the elevated bottle [1] to the bacterin bottle [10] by-passing the 50 cc. syringe [3]. In approximately one minute the deep-purple gold solution is displaced from the bacterin bottle [10] to the pleural cavity, and about 100 cc. of saline solution is allowed to wash through the system.

When all the needles used, including the thoracentesis needle, are at least 15 gauge in size of lumen the flow of gold solution is rapid and unobstructed. Since we have adopted routine use of 15 gauge needles throughout the system we rarely find need for increasing pressure manually with the 50 cc. syringe [3].

The method for injecting radioactive gold into the abdominal cavity is the same as in the procedure described for pleural cavity treatment up to the needle [7 in Figure 1] which carries gold from the bacterin bottle [10] to the patient. Attached to this needle [7] is a modified Sub-Q-Pak no. 4434 [11 in Figure 2] of expendable plastic tubing. In modifying this commercially available Sub-Q-Pak [11] the central stem of the Y tube is cut off six inches from the Y-junction and a male connector [10 in Figure 2] attaches the shortened Y tube to the needle [7]. Each of the limbs of the Y tube [11] is connected to an 18 gauge 1½ inch needle [12]. These needles [12] are connected to the polyethylene catheters [13] which had been previously inserted into the patient's abdominal cavity.

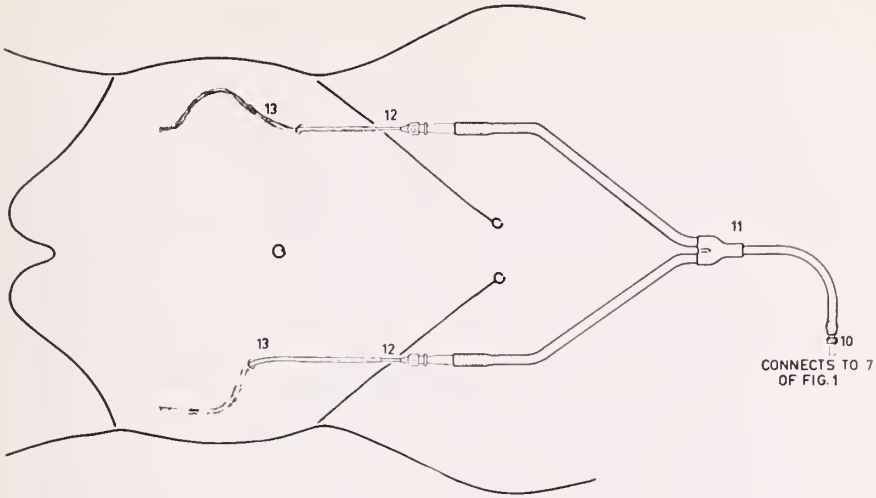

FIG. 2

As in the procedure described for treatment of the pleural cavity, the pinch clamps [a and b of Figure 1] are opened, and the gold solution is displaced into the abdomen. If the gold only runs into one limb of the Y, this side is temporarily clamped with a long hemostat to attempt equal distribution to each side of the abdomen. Since there are 18 gauge needles [12] in this set-up, flow is slower and may be accelerated by use of manual pressure from the syringe [3]. About two minutes is required to clear the system of gold and 200 cc. of saline solution is used to clear the tubing. The pinch clamps [a and b] are then closed to stop the flow, and the polyethylene tubes are withdrawn from the abdomen. Michel skin clips seal the openings in the abdominal wall through which the polyethylene tubes [13] are withdrawn. This prevents leakage of radioactive fluid on the skin or dressings.

Leakage of radioactive solution around the conventional paracentesis wound in the abdominal wall presented a hazard which can be avoided by adopting the technique of Bronfin et al (2) to the administration of radioactive colloidal gold in the peritoneal cavity. In this technique tubes are inserted into the abdomen about 24 hours before the gold is to be injected. During this period of 24 hours the abdominal fluid drains spontaneously through the tubes to a bedside bottle at the rate of 200 to 400 cc. per hour. As indicated in Figure 3, a 14 gauge thin-walled needle is inserted through the abdominal wall to lie within the peritoneal cavity. The stylet is removed from the needle and a polyethylene tube .065″ in diameter is threaded into the needle so that 10 to 12 inches of the tube lies in the peritoneal cavity. The 14T needle is withdrawn over the tube, and the tube is affixed to the skin with adhesive tape. The outside end of this tube drains into a bedside bottle. The portion of the tube within the peritoneal cavity has several holes cut in its side to assure continuous drainage. Two polyethylene tubes, one in each flank, are inserted into the abdominal cavity, and the patient finds little discomfort in the procedure of insertion and the subsequent period of 24 hours while the tubes are draining.

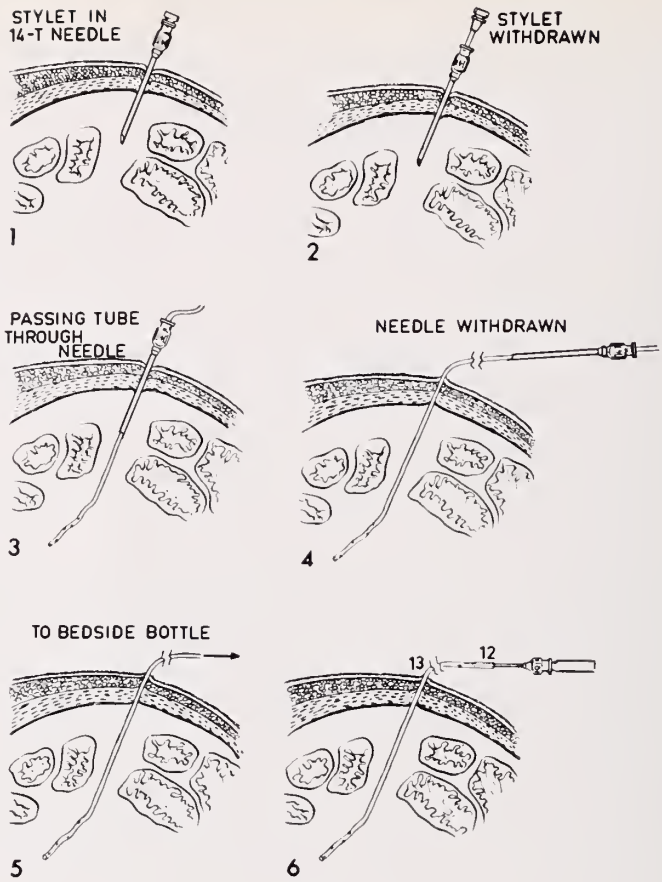

Fig. 3

These polyethylene tubes are also useful for the surgeon who finds a peritoneal effusion due to cancer during an exploratory laparotomy or inadvertently spills the contents of a cystic ovarian carcinoma into the peritoneal cavity. In these circumstances the polyethylene tubes may be placed by the surgeon to drain the peritoneal cavity for as long as a week while awaiting the arrival of radioactive colloidal gold which is then injected through these tubes.

In summary, the described method of administering radioactive colloidal gold solution into the pleural and peritoneal cavities is characterized by: 1. Relative simplicity; 2. Expendability of contaminated tubing; 3. Commercial availability of components; 4. Minimal handling of radioactive gold; 5. Low total body exposure to radiation of personnel; 6. Avoidance of spillage; 7. Little discomfort to the patient.

REFERENCES

1. Andrews, G. A., Root, S. W., Kerman, H. D., and Bigelow, R. R.: Intracavitary Colloidal Radiogold in the Treatment of Effusions Caused by Malignant Neoplasms. Annals of Surgery, 3: 375, 1953.

2. Bronfin, G. J., Liebler, J. B., and Katz, H. M.: A New Method for Abdominal Paracentesis. Gastroenterology, 21: 426, 1952.
3. Cohen, M., and Shanks, W.: An Apparatus for Intracavitary Administration of Radioactive Colloidal Gold. Brit. J. Radiol., 26: 660, 1953.
4. Rose, R. G., Osborne, M. P., and Stevenes, W. B.: Intracavitary Radioactive Gold. N. Eng. J. Med., 247: 663, 1952.
5. Simon, N., Abrams, J., Khilnani, M., Margolin, H. N., Gurman, S. I., Eliasoph, J., and Mayer, J.: The Use of Radioactive Gold in the Treatment of Effusions Due to Cancer. J. Mt. Sinai Hosp., 20: 237, 1953.
6. Ter-Pogossian, M. and Sherman, A. I.: Handling of Radioactive Gold for Therapeutic Purpose. Nucleonics, 10: 23, 1952.
7. Walton, R. J., and Sinclair, W. K.: Intracavitary Irradiation with Radioactive Colloidal Gold in the Palliative Treatment of Malignant Pleural and Peritoneal Effusions. British Med. Bull., 8: 165, 1952.

RADIOACTIVE GOLD TREATMENT: RESULTS IN 85 EFFUSIONS DUE TO CANCER

NORMAN SIMON, M.D.

New York, N. Y.

Increased experience has confirmed the efficacy of radioactive colloidal gold in helping to control the formation of fluid in pleural and abdominal effusions due to cancer. Radioactive colloidal gold has been used in the treatment of effusions due to cancer in 85 patients in the Mount Sinai Hospital since July 1, 1951. A preliminary report of the results in the first 19 patients treated was published in 1953. The formation of fluid was suppressed in about half of the patients in this early series (1).

The indications for the use of radioactive gold are not always clear cut. A tabulation of results in the tumors treated and some comments may clarify these indications.

It is sometimes difficult to determine whether this type of palliative treatment has been successful in an individual case. When a patient with an effusion due to cancer needs multiple paracenteses and the frequency of these taps is reduced after use of radioactive gold, a beneficial result is obvious. On the other hand, when a patient develops an effusion due to cancer and a tap is required, it is difficult to predict, at the time of the first tap, the rate at which the fluid will reaccumulate. Yet, an attempt to suppress the formation of fluid by injecting gold immediately after the first paracentesis may be a clinically sound procedure. During our early experience with the use of intracavitary gold for the suppression of fluid formation, patients were selected for treatment only if multiple taps had been required. More recently we have also elected to inject gold at the time of the first tap. In the accompanying tables these latter patients are listed as "uncertain" results. Favorable results listed in the tables indicate complete suppression of fluid formation or definite decrease in the rate of accumulation.

In Table 1 there are 46 pleural treatments tabulated with favorable results in 20 cases or 43%. The commonest tumor producing pleural effusions in this series is cancer of the breast. Our most gratifying results are obtained in this disease in which more than half the patients ($^{13}/_{20}$) had suppression of formation of pleural fluid. Pleural fluid in patients with cancer of lung is generally considered to be unrelieved by radioactive gold. Only 8 patients with carcinoma of the lung have been treated in this series, and two of these were benefited. It seems reasonable that pleural effusions due to cancer of the breast should respond better than those due to cancer of the lung. Inoperable cancers of the lung are almost uniformly rapidly progressive, while the survival of some patients with cancer of the breast and pleural effusions is comparatively long. Despite discouraging re-

From the Departments of Physics and Radiotherapy The Mount Sinai Hospital, New York, N. Y.

TABLE I

Pleural effusions treated with Au^{198}

Diagnosis	No. of Patients Treated	Favorable Results	No Effect	Uncertain
Carcinoma of breast	20	13	2	5
Carcinoma of lung	8	2	2	4
Carcinoma cells in pleural fluid; primary tumor not definitely known	10	2	5	3
Hodgkin's Disease	2	2		
Leukemia	1		1	
Carcinoma of ovary	2		2	
Carcinoma of thyroid	2		1	1
Carcinoma of uterus	1	1		
Total	46	20	13	13

TABLE II

Ascites treated with Au^{198}

Diagnosis	No. of Patients Treated	Favorable Results	No Effect	Uncertain
Carcinoma of ovary	22	7	6	9
Carcinoma cells in peritoneal fluid; primary tumor not definitely known	8	3	2	3
Carcinoma of colon	3	1	2	
Carcinoma of pancreas	2	1	1	
Carcinoma of stomach	2	1	1	
Leukemia	1		1	
Amyloidosis	1		1	
Total	39	13	14	12

sults in most patients with cancer of the lung, it is worthwhile to attempt suppression of fluid formation with gold if the fluid accounts for the patient's major symptoms or if frequent taps are required.

In this series of 46 pleural effusions 10 were due to cancers whose primary site was not determined. The diagnosis of cancer was established by study of cell blocks of pleural fluid. Only two of these patients were benefited. Two patients with pleural effusions secondary to Hodgkin's Disease were treated with gold and responded favorably.

In Table II the results in 39 patients treated for ascites secondary to cancer are indicated. Beneficial effects were seen in 33% ($^{13}/_{39}$). More than one half ($^{22}/_{39}$) of the treatments were given for carcinoma of the ovary and about 30% ($^{7}/_{22}$) of these resulted favorably insofar as suppression of fluid is concerned. Two of the patients with carcinoma of the ovary had radioactive gold injected postoperatively in an attempt to prevent seeding of any free carcinoma cells in the abdominal cavity. It is only in these two instances of spillage of contents of

carcinomatous cysts that intracavitary radiogold was used for its potentially curative effect on tumor cells. The result in these two patients is listed as "Uncertain" in Table II.

Eight patients were treated with radioactive gold for ascites due to cancer whose primary site was not definitely known. In these patients the diagnosis of cancer was established by study of cell blocks of abdominal fluid, and three were favorably influenced.

A summary of the total experience of 85 cases treated with intracavitary injections of radioactive gold indicates that 33 patients (39%) showed suppression of formation of fluid. Better statistical results could be obtained by a more strict selection of patients, giving gold only to those patients whose effusions are due to slowly growing cancers of the breast or ovary. However, occasional good results in effusions due to other primary tumors justifies a less restricted use of radioactive colloidal gold.

BIBLIOGRAPHY

1. Simon, N., Abrams, J., Khilnani, M., Margolin, H. N., Gurman, S. I., Eliasoph, J., and Mayer, J.: The Use of Radioactive Gold in the Treatment of Effusions Due to Cancer. J. Mt. Sinai Hosp., 20: 237, 1953.

OCCLUSION OF INTERNAL CAROTID ARTERY: CLINICAL DIAGNOSIS AND THERAPY

REUBEN OTTENBERG, M.D.

New York, N. Y.

Until recently diagnosis of occlusion of the internal carotid artery was rarely considered; and therapy was not attempted.

Usually the cases were discovered at autopsy following a hemiplegia. In numerous cases of hemiplegia no thrombi were found in the main cerebral arteries and this led to examination of the vessels of the neck which had previously been neglected. The neglect of this area was due to the fact that the examination of the brain and its contained arteries is carried out by the neuropathologist, while the arteries of the remainder of the body from the neck downward are examined by the general pathologist. This left the neck vessels, including the internal carotids, in a sort of "no man's land" and they were not studied.

The first step in understanding this symptom complex is due to the discovery of the carotid sinus reflex by Hering in 1924. In this fundamental monograph, "The Carotid Sinus Reflex of Heart and Arteries", Hering demonstrated that the slightly bulbous first portion of the internal carotid is an important part of the reflex mechanism which maintains blood pressure and pulse rate at a constant level. He described the two carotid sinus nerves (small filaments which reach the basal ganglia by way of the hypoglossal nerve); together with the two depressor nerves (aortic nerves) which together constitute the *centripetal* path for the blood pressure lowering reflex. And he also described the pulse retarding or inhibiting effect carried *centrifugally* by the vagus nerve. The sudden (or continuous) centrifugal blood-pressure-lowering effect is thought to be via the sympathetic nerves.

Hering's work was followed by pathological and clinical studies from which it appeared that the carotid sinus was one of the parts of the arterial system particularly prone to atherosclerosis, and that a resulting increased sensitiveness of this sinus due to this atherosclerosis was a cause of syncope.

This was followed by several clinical reports of cases confirmed at autopsy or operation. Schapiro and Peyton (1) reported 17 cases and reviewed about 200 old ones and Miller-Fisher (2) reported in detail 8 other cases. From these reports it appears that the disease is typified by (a) a more or less progressive and prolonged period of recurrent motor phenomena (monoplegias, convulsions, etc.), sensory phenomena (visual disturbances, etc.), or mental phenomena (loss of memory, changes of personality, etc.). These disturbances may be transitory and usually are repeated, or alternate with one another. Fisher (2) stresses as characteristic (b) a transient unilateral amblyopia always recurring in the *same* eye. This may be followed after a shorter or longer period (a day to a year, or more) by (c) a heterolateral hemiplegia (invariably on the side of the body opposite to that of the eye symptoms).

In summary, the clinical picture is characterized by a clear-cut and specific

triad: (a) Carotid sinus sensitivity, (b) unilateral transient amblyopia, (c) heterolateral hemiplegia.

In addition to the clinical symptomatology there is available a method of confirmation, arteriography; X-ray diagnosis of the carotids (internal and external) after injection of thorotrast into the common carotid. This procedure introduced by Moniz (3) requires a high degree of skill and co-ordination on the part of the operators, but has been used successfully in many cases, and has shown occlusion of the internal carotid, or in some cases irregularity or narrowing at the level of the carotid sinus; and in other cases reversal of the stream with some of the opaque substance going into the vertebral or innominate artery.

I have personally experienced the various phases of the clinical triad described above and propose to report my own case.

CASE HISTORY

I am a retired physician 73 years old and the father of two children. Previous illnesses were many but since none of them have any provable relation to the present illness they will be briefly listed:

1928: Pneumonia of left lower lobe during which there occured a paroxysm of auricular fibrillation.

From this time on one or two paroxysms of irregular heart action each year, usually regarded as auricular fibrillation or impure flutter. These have generally been self limited or stopped promptly by quinidine.

1936: Laparotomy for a lipoma of the colon.

1936: Bronchopneumonia of the left lower lobe. During this illness a syncopal attack occurred. The mechanism of this attack was not determined.

1945: Attack of mild appendicitis.

1946: Recurrent attack of appendicitis.

1947: Acute gangrenous appendicitis with general peritonitis.

In 1946 I began to have recurrent episodes of syncope at irregular intervals (1, 2, 3, 6 or 9 months). The first such attack was typical of those that followed. It occurred on December 21, 1946. I had gone into the hall of our apartment house in order to mail a letter. I had no prodromata and felt perfectly well. There may have been some emotional stress immediately antecedent. It was shortly after dinner. I recovered to learn that I had been found comatose in the hallway. The attack had apparently lasted about five to ten minutes. During the next two years I suffered several syncopal attacks always with such suddenness that I was unaware that anything had happened until I became conscious again. Repeated physical examinations, blood and urine examinations, X-ray studies, electrocardiograms and electroencephalograms were essentially negative except as described.

The blood pressure had always been normal, averaging 120/70. Urine examinations were negative except for a trace of sugar on one occasion. The fasting blood sugar was 120 mg.% and on another occasion, 159 mgs.%. The glucose tolerance test was normal. The blood cholesterol was 230 mgs.%. A cerebral arteriogram was not done.

The important positive finding was great sensitiveness of the carotid sinus on the right side. Light pressure of a finger on this area regularly produced cardiac stand-still lasting from 1–7 seconds. There was no response on the left side. Trials of full doses of ephedrine and of atropine ½ to 1 hour before the test showed that these drugs did not change the sensitivity while phenobarbital, particularly when used in combination with atropine, did diminish the reflex (Fig. 1).

During the period in which these syncopal attacks occurred, repeated episodes of right transient amblyopia also developed. These were much more frequent than the syncopes (once or twice a week). These attacks were always signalized by a transitory sensation best



FIG. 1. Asystole for 3 seconds produced by light finger pressure on right carotid sinus.

described as a snapping or clicking behind the eye ball. I would then notice that the eye was almost totally blind. On careful testing I noted that the center of the field of vision was intact. It resembled a small oval-shaped window in a grey screen which cut off all the field peripheral to it. After 3 to 5 minutes, vision always restored. Ophthalmological consultations found the ocular fundi to be normal and the attacks were ascribed to vasospasm.

On one occasion an attack of blindness came on while Dr. Weiss was in my office. He was able to carry out an immediate ophthalmoscopic observation and found a diffuse and complete spasm of all the retinal arterioles, in some of which fine filaments of trapped blood were noted, producing a segmented appearance. The fundus was blanched. The left eye was normal. Five minutes later, the fundus of the right eye was completely normal and vision was restored.

Two years later, in June of 1949, I found that my left arm was powerless. I then found that my left leg was also paralyzed. Dr. Weiss found that I had a left hemiplegia including involvement of the left side of the face and left side of the tongue. Speech was unimpaired except for a little slurring due to weakness of the left side of the tongue.

The hemiplegia disappeared completely in three months. A neurological consultation suggested the diagnosis of a thrombosis of the right internal carotid artery. The progressive symptom complex which had developed over several years was found to correspond to the published description of this disease and to include the typical triad described.

The only symptom which remained after the left hemiplegia was the syncopal attacks which continued to occur though with less frequency than before. In the hope of diminishing these I began to take phenobarbital, gr. ½, with atropine sulphate, gr. 1/100, t.i.d.

Electroencephalographic and electrocardiographic studies* showed that while I was taking atropine and phenobarbital regularly there was no increased sensitivity of the sinus, but when the phenobarbital was omitted for 24 hours there was immediate activation with syncope and cardiac asystole on slight compression of the right carotid sinus.

On phenobarbital and atropine, taken for the past 8 years, syncopal attacks have recurred at irregular intervals, usually 9 to 12 months apart except for two attacks 6 weeks apart in April–June, 1954. There have been none since. The attacks usually occurred following neglect of medication, emotion, excessive fatigue or hearty laughter, but, also, at times without any of these factors. Except for one occasion the attacks invariably occurred in the standing or sitting position. There are no residua of the hemiplegia and there has been no recurrence of the transient amblyopia, and aside from the syncopal attacks, the only after effect which has persisted has been a moderate physical sluggishness and mental dullness.† This sluggishness may be due to diminished blood supply of the brain (one internal carotid normally carries almost half of the cerebral blood supply), or it may be the effect of aging and progressive arteriosclerosis, or it may be due to the continuing therapy of 1½ grain phenobarbital daily.

---

* Carried out by Dr. Hans Strauss at the suggestion of Dr. Israel Wechsler.

† It should be noted here that banthine in rather large doses (200–400 mgs./day) has been recently suggested as a therapeutic agent in carotid sinus syncopy and satisfactory results reported (4).

Surgical exposure of the internal carotid and stripping the carotid bulb of its outer coat which is composed of the plexus of sympathetic nerves‡ from which the reflex is believed to arise has been suggested (5–7). The literature is not encouraging and surgical fatalities are reported.

An important question is that of therapy for prevention of hemiplegia in cases in which the diagnosis can be made in the early stage before hemiplegia has occurred. The combination of attacks of transient unilateral amblyopia with recurrent attacks of syncope traceable to the carotid sinus on the same side could suggest the diagnosis of a beginning thrombosis of the carotid sinus and a prolonged course of anticoagulant therapy could be instituted. The inconvenience of this form of therapy is obvious.

Two months ago I had an attack of transient partial blindness in the *left* eye. It differed from the earlier attacks in the right eye in that the blind field was exactly half of the visual field; it was as though a black screen were being held in front of the left eye and obscured everything in the inner (nasal) half of the field up to the mid-line where it ended sharply. This attack which occurred while I was resting quietly on a couch, was preceded by the same peculiar clicking sensation which I had previously noted with the right sided attacks and like these it lasted less than five minutes. This is the only recorded instance, as far as I am aware, in which a transient amblyopia has been noted in both eys. I hope that it is not the precursor of a hitherto unknown occurrence: thrombosis in both internal carotids. I am happy to say that there has been no further amblyopia and there has been no syncope for nine months. What other explanation (except hysteria) can be offered for the single transient amblyopia in the left eye?

SUMMARY

A clinical case of thrombosis of the right internal carotid is described which presents the classical symptom triad:

1. Hypersensitivity of the right carotid sinus.
2. Recurrent transient right amblyopia.
3. Heterolateral (left sided) hemiplegia.

More recently a transient amblyopia occurred in the opposite eye. This is unique and may indicate involvement of the left internal carotid.

DISCUSSION

Several interesting questions are raised by the above presentation. First: the lesion, thrombosis of the internal carotid may be much more frequent than it is thought to be. Unexplained hemiplegia occurs very often and a detailed previous history of the patient is not always available. Next the question of therapy is important: should it not be possible to make the diagnosis in the early stage (before hemiplegia) and by continued anticoagulant therapy to prevent the hemiplegia? Also in the rare cases (like my own) in which the patient recovers from the hemiplegia but continues to have embarrassing syncopes, the prevention of syncopes becomes important. Phenobarbital appears to be the most effective drug thus far, but several others deserve trial, as: ephedrine, benzedrine, dexedrine, etc. Also it is possible that some of the cases previously described as hemiplegia or monoplegia resulting from a carotid sinus pressure test may have been really cases in which a thrombosis was already in process of formation at the time of the test.

‡ Strangely enough, I can find no description of sensory nerve endings, only of nerve fibres (5).

ACKNOWLEDGMENTS

I wish to express my thanks to Drs. I. S. Wechsler, Hans Strauss, Richard Brickner, B. S. Oppenheimer and Harry Weiss, not only for their kind services, but especially for permitting me to use their findings and opinions. I am most particularly indebted to Dr. Weiss.

BIBLIOGRAPHY

1. Shapiro, S. K., and Peyton, W. T.: Spontaneous Thrombosis of the Carotid Arteries. Neurology, 4: 83, 1954.
2. Fisher, M.: Occlusion of Internal Carotid Artery. A. M. A. Arch. Neur. & Psych., 65: 346, 1951.
3. Moniz, G.: Arterial Encephalography. Rev. Neurologique, 2: 72, 1927.
4. Haymond, T., and Belle, S.: Effect of Banthine on the Cardiac Mechanism in States Associated with Increased Vagal Tone. Am. J. Med., 16: 516, 1954.
5. Bourdouresques, J., Luccioni, F., Berthon, J., and Dongier, M.: Myasthénie Aiguë Traitee par Énervation Sinu-Carotidienne Bilaterale. Rev. Neurologique, 83: 304, 1950.
6. Papin, F., and Doutre, L. P.: Apneé Secondaire Mortelle après une Intervention sur la Fourche Carotidienne. Bourdeaux Chir., 28: 1951.
7. Courty, A., Cabanettes, L., and Biscaye, A.: Énervation Sinu-Carotidienne dans la Myasthénie Bulbo-Spinal; Resultats après Trois Ans et Demi. Semaine Hôp. Paris, 26: 4807, 1950.

GROUP PSYCHOTHERAPY ON THE PSYCHIATRIC WARD OF A GENERAL HOSPITAL

AARON STEIN, M.D., WILFRED C. HULSE, M.D., WILLIAM V. LULOW, M.D., AND M. RALPH KAUFMAN, M.D.

New York, N. Y.

This report is a description of experiences encountered during a period of one year when group psychotherapy was given on the psychiatric ward of a general hospital. During this period it became apparent that group psychotherapy was a very useful method of treatment in many respects. However, its introduction raised many questions as to the nature of its effect in this particular setting.

The psychiatric ward where the group psychotherapy was given is part of a large general hospital with active medical, surgical and other departments including a large out-patient service. The psychiatric service, as has been described elsewhere (1), is very active and functions in four main areas: (a) a liaison service integrated with every other service in the hospital; (b) an out-patient treatment service; (c) a children's psychiatric service; and (d) an in-patient service for diagnosis and treatment. This last is the psychiatric ward where the group psychotherapy was given.

This ward, while in the hospital proper, is a separate unit physically, having its own floor on the medical side of the hospital. It consists of a ward proper and several rooms. The number of patients on the ward varies from 12 to 20 with 16 being average. Patients remain on the ward usually about 2 to 6 weeks. A resident staff of 2 or 3, together with a varying number of non-resident fellows, has the immediate care of the patients. Several of the attending staff supervise the care of the patients, especially with regard to psychotherapy in which the resident and fellows are proctored individually. Adjuvant services—psychiatric social work, psychological testing, occupational therapy,—are integrated into the treatment.

Patients are admitted to the ward from many sources—from the other services through the liaison psychiatrists, from the psychiatric out-patient treatment centers, by referrals from physicians and from community agencies. Patients are both male and female, and all ages, backgrounds, etc. are encountered. An occasional psychotic patient is admitted, usually with some concurrent somatic illness. Mostly the patients are nonpsychotic with varying kinds and degrees of neurotic and characterological difficulties. However, many are severely ill from the psychiatric standpoint. Usually there is present either an actual somatic illness or a marked somatic symptomatology.

The patients seen in the period the group psychotherapy was given ranged in age from 14 to 62 years. Usually women predominated, sometimes in the ratio of three or four women to one man. Many had somatic illnesses such as peptic ulcer, ileitis, colitis, arthritis, asthma, congenital cardiac disease, neurodermati-

From the Department of Psychiatry, The Mount Sinai Hospital, New York, N. Y.

tis, lupus erythematosus, migraine, hypertension. The psychiatric conditions ranged from anxiety and hysterical states to severe disabling characterological disorders.

Group psychotherapy, as previously reported (2), has been used at this hospital for several years but had not been given on the psychiatric ward up to the time of the work reported here. Several considerations led to the decision to institute the use of group psychotherapy on the ward. Since the ward physically constituted a unit, the patients on the ward comprised a group contained within this unit. This physical grouping led to another group experience for the patients, living together 24 hours a day. Such closeness caused the ward patients to develop a private group life of their own which, while not concealed, was not discussed with the doctors and the nurses. It had been noted also that patients showed fairly clear cut positive emotional attitudes toward the ward, and these had been used to form an out-patient group for group psychotherapy from former ward patients (2).

In addition, the patients, from time to time, showed clearly the existence of what might be called a group spirit which was manifested by the expression of similar attitudes towards the ward routine and their treatment. As is common on psychiatric wards, such attitudes were often negative, defiant or hostile and occasionally led to acting out and consequent difficulty in following the ward routine. Often such manifestations of the groups' attitude were inspired by one patient around whom the group centered, while, at times, there were opposing cliques. It was felt that group psychotherapy could utilize this group attitude and perhaps channel its energy into more therapeutically useful outlets for the patients.

Finally, certain other considerations connected with our current knowledge of the nature of group psychotherapy entered into the decision to use it on the ward. Among other things, group psychotherapy is known to be helpful in two ways: (a) it provides ego-support and assists ego-integration, and (b) it strengthens the patients' contact with reality. It was thought that with the seriously ill patients on the ward in whom inability to cope with severe emotional conflicts often further weakened inadequate egos and diminished their contact with reality, that group psychotherapy would be specifically helpful along these lines.

Since individual psychotherapy is given to all patients on the ward, the question at once arose as to what would be the effect of the introduction of group psychotherapy upon the individual treatment of the patients? This was discussed in several conferences with the entire staff of the ward and during these conferences several other points were raised. These might be summarized as follows: How would patients react to having one doctor for group psychotherapy and another for individual psychotherapy? Would patients find contradictions between what one therapist said compared with the other and how should this be handled? Would the patients use one therapy in opposition to the other? Would the group psychotherapy tend to encourage acting out? How could the individual and group psychotherapy be coordinated? How would the patients

be brought into the group psychotherapy? What would be done about patients who did not come to the group sessions?

The discussions concerning these questions proved to be most useful. They served to prepare the rest of the staff for the introduction of group psychotherapy and provided an opportunity to set up methods of approach to some of the difficulties raised.

SUMMARY OF THE GROUP PSYCHOTHERAPY

The group sessions were held in the patients' recreation room on the ward. They were given once a week for a period of an hour to an hour and a half. There was no formal procedure and the patients could sit where they pleased, smoke, talk when they pleased, and ask questions. Except for a few very brief introductory remarks by the therapist during the first two sessions, the material of the sessions came from the spontaneous remarks of the patients.

The individual patients were prepared for the group sessions by means of a brief interview with the group therapist during which the purpose of the group psychotherapy was explained to them and they were asked if they would like to attend the sessions. Following this, they were notified of the time of the sessions and could attend or not as they pleased.

Because patients usually remained on the ward only about two to six weeks, there was a constant turnover of patients in the group. Usually every two or three weeks, one to three of the patients would leave and a similar number of new patients would come into the group. Occasionally, a larger number of patients would enter or leave the group. Occasionally also, the group would remain unchanged for a period of several weeks.

The material covered in the group sessions might be briefly summarized as follows: The first few sessions were largely concerned with discussions as to whether the patients would keep the material of the group sessions confidential. The patients then began to speak of fears—at first in a general and impersonal fashion, then gradually more personally. As they did this, there was a period when there was considerable discussion of the difficulty in talking over things with their doctors. The discussion then proceeded along the lines of whether their physical disabilities were real or not and what emotional factors had to do with them. At this time, they spoke at length of how they felt about their illness—how it made them feel different and ashamed.

At about this point, the 10th session, the group spontaneously commented that the group atmosphere had changed; it was more friendly and cooperative. Following this, the group decided to talk about sex and led by a relative newcomer to the group, the discussion centered about sexual difficulties in marriage and then went on to other marital difficulties. At about the 15th session, the group began to bring up in the discussions hostile and aggressive feelings, towards their husbands at first, later towards parents and, finally, in a veiled fashion, towards the therapist.

Following this, the patients began to display jealous and aggressive attitudes toward each other, and in one session, the 18th, at which only women were

present, they clearly revealed erotic and demanding attitudes concerning one of the male residents. Next came a period when the patients, led by those who knew they were going to leave the ward soon, spoke of their fears of going home. This led to a series of discussions of their expectations from their families on the one hand and from the doctors and the hospital on the other. Very childish attitudes became clear here. Demanding and aggressive attitudes and much guilt and fear over these, as well as many distorted ideas concerning their illness, and such things as sex and pregnancy were brought out.

This summary of the content of the group sessions, naturally, is far more clear and better organized that the discussions in the group. The "themes" noted above were not developed in an orderly fashion and in each session, there was much rambling back and forth with repetition of material and digressions. However, the general trend of the discussion was along the lines noted above.

The constant changing of the members of the group, of course, also tended to make the group discussions fluctuate. It took a while until the new members oriented themselves and began to participate and therefore repetitions and digressions inevitably occurred. However, to a surprising degree, the discussion maintained a general sort of continuity even when new patients entered the group. This resulted from the fact that the older patients "indoctrinated" the new ones, so to speak, by their discussions outside of the group meetings.

While it was true that the group discussions proceeded along certain general lines, they tended to center around and be led by certain individual patients. At times, external factors determined who this leader would be. For example, during the period when the group was discussing their fears about leaving the hospital, a definite "protocol" was set up by the group so that the discussion centered about and/or was led by the patient whose discharge from the ward was most imminent. Mostly, however, the sessions centered around patients who spontaneously became the leaders. As would be expected, some were very aggressive and articulate people who would naturally try to dominate and when such patients were in the group, they tended to be leaders and thus to determine the direction and nature of the group discussions to some extent. At other times, the leadership would be assumed by patients who, though they were usually shy or reticent, were laboring under strong emotional stresses. Finally, there were times when in response to the group reaction or feeling with regard to certain themes, patients would spontaneously become the spokesmen for the group feeling. This tendency of the group sessions to focus around and be led by certain patients is, of course, a reflection of the emotional currents existing in the group. The latter are the basis for the dynamics of the group psychotherapy and the observations concerning this made with these groups of patients will be described separately (3).

EVALUATION AND RESULTS

During the course of the year, the group psychotherapy was discussed at a series of conferences with the other personnel concerned with the treatment of patients. This permitted an opportunity to evaluate its influence and effective-

ness, especially in relation to the questions raised previously. The residents and nurses observed that the group psychotherapy had helped to improve the general atmosphere of the ward. The attitude of the patients towards the ward routine, the ward personnel and towards each other was more cooperative and realistic. Patients tended to relate to each other better and there was less isolation and clique formation. The questions raised about how the patients could be induced to come to the group and how their absences would be dealt with were answered quite clearly. The permissive attitude decided upon proved to be effective in having the patient come. The therapeutic group formed quickly and effectively with the minimal preparation noted above. When the ward census was in the neighborhood of fifteen, eight to ten patients attended the group; when the ward census was smaller, the group tended to be smaller.

Attendance at the group had a diagnostic and prognostic value. Those who were physically too ill could not attend, while those who were too regressed, withdrawn or depressed would attend for a session or two and drop out. Another diagnostic and prognostic index was the participation of the patient. Those who did not participate for one reason or another also proved to be relatively inaccessible to individual therapy. Among patients who usually attended and participated, an absence from the group was repeatedly found to be significant in relation to their underlying emotional state. Such patients would become anxious or upset by threatening conflicts, by feelings aroused by the relationships in the group or by fears of exposure to or reaction by the group. Their absences from the group could often be used both in individual or group psychotherapy as the starting point for eliciting important material or attitudes.

It had been decided to coordinate the individual and group treatment by means of a regular series of conferences in which the group therapist informed the individual therapists of the content of the group meetings, after which the relationship and interaction of the two forms of treatment were discussed. This series of conferences proved most valuable in enlarging and clarifying observations concerning the reactions of the patients and they also served as a basis for teaching the residents group psychotherapy.

At these conferences it was found repeatedly that patients did try to utilize the group treatment in the service of resistance against the individual treatment. This had been anticipated and as a result, it was recognized and dealt with without any great difficulty. The individual therapists had been especially concerned as to whether the patients would seize upon contradictions in statements made by the different therapists. This did occur and it was handled quite effectively by focusing on why the patient brought it up rather than on the contradiction itself. The most important observations concerning the relationship of the group psychotherapy to the individual treatment concerned the nature of the relationship between the therapist and the patient and the type of material brought out by the patient. The nature of the relationship between patient and therapist is different in group than in individual treatment and as a result, different material is brought up. In the group, the relationship was less threatening and on a more realistic basis, the patient had more support, and

consequently they could speak more freely. In the individual treatment, the relationship to the therapist was more intense and elicited other responses. In the individual treatment, the patients seemed to be more concerned with pre-genital conflicts, especially in terms of their attitudes toward therapist, and this made it difficult for them to speak freely. In the group, the patients could speak freely of sexual conflicts and their attitude to the therapist was much more realistic, but they did not discuss pre-genital strivings except in terms of their derivatives.

On the basis of the above, it was apparent that group and individual treatment tended to supplement each other. The residents found the individual treatment was aided by the group sessions in that patients were stimulated and new material was brought up. Their attitude in the individual sessions often showed a change in the direction of being interested in bringing up and working through problems. With some difficult patients who had held back a great deal in the individual therapy, such a change proved most helpful.

Despite this, the exact relationship between group and individual therapy remains to be more clearly defined. For example, the more experienced attending staff who proctored the residents in the individual treatment were not able to clearly estimate the impact of the group treatment. While they felt it had considerable usefulness, especially with patients who were either inaccessible to or too threatened by individual treatment, they also thought that the group psychotherapy added another emotionally charged influence to the multitudinous and complicated factors present in a set-up like the ward. It was observed that the emotional impact of the group sessions carried over into the atmosphere of the ward and with a group of patients who lived so closely and constantly together, this had a much more sustained effect than in an outpatient group. In relation to the individual treatment the patients received, the question was raised as to whether the group psychotherapy, even if it did supplement the individual psychotherapy, would not also tend to disperse the latter's therapeutic effect.

This last question, whether the addition of group psychotherapy to the individual psychotherapy with a different therapist for each did not tend to disperse the therapeutic effect of the individual treatment, raised a very important point in connection with the theoretical formulations on which the treatment of the patients on the ward was based. The ward patients were often severely ill from the psychiatric point of view with weakened egos, impaired contact with reality and poor object relationship. The need to establish contact with these patients in order to help them establish adequate object relationships was the first and most important goal of therapy. Obviously, the use of two therapists and two different forms of therapy instead of helping to focus the very necessary therapeutic relationship could be regarded as having the opposite effect.

At the end of the year's experience with group psychotherapy, these considerations were involved when, in accordance with the policy of rotating the attending staff, the treatment program of the ward came under the supervision

of a different member of the attending staff. It was felt that the likelihood of a dispersal of the therapeutic effect as noted above was considerable and that the use of group psychotherapy in addition to the individual treatment, for the time being, should be discontinued. Accordingly, group psychotherapy has not been given on the ward during the past year. During this time further observation of the effectiveness of individual psychotherapy with some of the seriously ill ward patients has indicated that many of them are relatively inaccessible or unresponsive to individual treatment and for such patients, group psychotherapy would appear to be a more easily tolerated and quite useful form of therapy. Plans, therefore, are being worked out to integrate group psychotherapy in the ward treatment program so as to make it available for those patients who would benefit by it without interfering with the individual treatment of those patients who need this latter form of therapy.

In the group sessions themselves, certain evaluations were possible and these clearly indicated that the group psychotherapy was helpful. The patients themselves spontaneously indicated changes in attitude that were helpful and attributed this to the group psychotherapy. There was emergence and working through of conflicts in relation to physical symptoms, childish and aggressive attitudes, marital and sexual problems again and again. Better contact with reality was made possible for many of the patients. Patients who were confronted with difficult physical problems and with complicated home situations were enabled to develop, to some degree at least, more flexible and realistic approaches to these. In the preparation of patients for discharge from the ward, the group sessions appeared to be most helpful. Discharged patients who visited the ward often asked about the possibility of being admitted to a group in the out-patient service.

CONCLUSIONS

Group psychotherapy was introduced quite readily as one of the forms of treatment on the psychiatric ward of a general hospital. Difficulties that had been anticipated concerning the relationship of individual psychotherapy to the group psychotherapy were dealt with by coordinating the two forms of therapy through a series of conferences between the group and the individual therapists. Our observations appear to indicate that group psychotherapy tends to supplement and aid individual therapy. The relationship between patient and therapist in the group was found to be different from that in individual therapy and there were indications that different material was brought out in the group sessions than was dealt with in the individual treatment. While some of the relationships between the individual and group treatment in a setting like the ward became clear, more observations and further clarification are necessary. Group psychotherapy was found to be helpful in the development of a better and more cooperative attitude in the patients in relation to ward routine. The group treatment was found to be useful in helping patients bring up and work through problems related to their somatic difficulties, sexual problems and family relationships and in enabling them to begin the development of more realistic and

effective approaches to these, especially at the time of their discharge from the ward.

BIBLIOGRAPHY

1. Kaufman, M. R.: The Role of the Psychiatrist in a General Hospital. Psychiatric Quarterly, 27: 367, 1953.
2. Stein, A., Lipshutz, D. M., Rosen, S. R., Mischel, E. and Sheps, J.: Experimental and Specific Types of Group Psychotherapy in a General Hospital. Internat. Jour. Group Psychother., 2: 10, 1952.
3. Stein, A., Kaufman, M. R., Hulse, W. and Lulow, W.: Some Aspects of the Dynamics of Group Psychotherapy. In preparation.

THE VARIABILITY OF PROTHROMBIN TIME DETERMINATIONS WITH "STANDARDIZED THROMBOPLASTIN PREPARATIONS"*

FRANK A. BASSEN, M.D.

With the technical assistance of VALIJA SKRODELIS

New York, N. Y.

INTRODUCTION

For proper control of dicumarol dosage the use of thromboplastin reagents of uniform activity has been recommended. Thromboplastin, prepared commercially or otherwise, having a control time of twelve to fifteen seconds on repeated testing against normal undiluted plasma has been considered to have a standard uniform activity. Variations between preparations may exist but consistency of the normal control time has determined the adequacy of the material. For dicumarolized patients a prothrombin time two to three times the control has been considered desirable.

This rather simple summary and rule of thumb formula for managing patients is very convenient but is based on the assumption that there are thromboplastins of standard uniform activity. Despite identical normal control values however, two thromboplastin preparations may give entirely different results on a single dicumarolized plasma (1); thus control times as a means of standardization are not valid. To obviate this difficulty results were reported in terms of concentration of prothrombin. This was accomplished by referring the times obtained with dicumarolized plasmas to the appropriate points on curves derived from doing prothrombin times on serial dilutions of normal plasma. Results however did not prove this concept to be correct, and Conley and Morse (2) found that with present methods it was impossible to compare results from one laboratory with those of another. Consequently they felt that the value of clinical studies with dicumarol was to a great extent impaired.

In a preliminary comparison study, using commercial thromboplastins, marked differences which bore no relation to control times frequently resulted, but a certain consistency in the differences was noted. This latter fact, previously reported by Conley and Morse (2) might be helpful in comparing results with reference to the brand name of the thromboplastin used. With this in mind a comparison study of some of the commonly used commercial thromboplastins was undertaken.

METHOD OF STUDY

Four widely used commercial thromboplastin preparations were selected for this study.† The method for the prothrombin determinations was that described

From the Hematology Department, The Mount Sinai Hospital, New York City.

* Aided by the A. A. List and A. R. Lowenberg Funds.

† Brand A: Simplastin; Chilcott Laboratories, Morris Plains, N. J. Brand B: Difco Thromboplastin; Difco Laboratories, Detroit 1, Mich. Brand C: Cappel Laboratories, Box 352, Wayne, Pa. Brand D: Certified Blood Donor Service, Jamaica 2, N. Y.

TABLE I

Prothrombin times (seconds): Results obtained in one group of 9 dicumarolized plasmas tested simultaneously with 4 different thromboplastin preparations. Note the variations unrelated to the control values

Thromboplastin	A	B	C	D
Control 100% plasma	14.5	13.0	13.5	13.0
Control 10% plasma	26.0	21.0	20.0	21.0
Dicumarol Plasma #1	26.0	26.0	23.5	27.0
#2	24.0	22.5	21.0	24.5
#3	25.0	25.0	22.0	25.5
#4	25.0	27.0	23.5	25.0
#5	34.0	33.0	26.0	28.0
#6	31.5	39.5	43.0	55.5
#7	32.0	34.5	32.0	33.5
#8	31.6	35.5	40.5	38.0
#9	31.0	36.0	37.0	35.0

by Quick, and the thromboplastin powders were prepared for use in accordance with the methods described by the manufacturers. Prothrombin time dilution curves were made with each of the four preparations. These curves were made by one technician and always with blood from the same donor. Prothrombin-free plasma from the same donor, prepared by adsorption with a 30% suspension of $BaSO_4$ (3) was used as the diluent. Four curves were plotted with each brand of the same lot number to determine the reproducibility of results under rigidly controlled conditions.

The same thromboplastin preparations were then used simultaneously in a large series of patients receiving dicumarol therapy.

1. *Results on Normal Plasma and Normal Plasma Serially Diluted with Prothrombin-Free Plasma*

In these dilution studies, prolongation of the prothrombin times were so slight in concentrations above ten per cent that comparative studies were of little value. In final dilutions of 10% and 5% the results as shown in Table II were similar with each brand. At 2.5% the results with three preparations varied somewhat. Reproducible values however were obtained with Brand C. It will be noted that this material gave consistently faster results in the more dilute mixtures.

The control times of three of the brands (B, C and D) were very similar (12.5–14 seconds). The fourth brand (A) was usually longer (14–15 seconds). The curves of all were quite similar although, as already stated, Brand C on the average gave faster times in the more dilute mixtures. Although Brand A usually gave longer times at 100 and 10%, the times at 2.5% were comparable to the others and in one instance with a control time of 15 seconds the time at 2.5% was as fast or faster than all the others.

In summary, although the 100% plasma control times varied to some extent, the curves obtained with the various thromboplastin preparations were comparable, with the exception possibly of Brand C which in general gave faster times in the 5% and 2.5% dilutions. There was nothing to indicate that the

TABLE II

Prothrombin times (seconds): Results obtained with four commercial thromboplastins, each of the same lot number

Normal plasma was diluted serially with prothrombin free plasma prepared by adsorption with barium sulfate plasma. The tests were performed in quadruplicate to determine reproducibility of results.

	Plasma 100%	Plasma 10%	Plasma 5%	Plasma 2.5%
Thromboplastin A	15-15-15-14	23.5-20-25-24	31-27-31-33.5	42.5-36-48-46.5
Thromboplastin B	13-13.5-13-13	21-22.5-21-22	27-30-28-31	45.5-49-40-45
Thromboplastin C	14-13-12.5-13	20-20-20-21	26-26-25-26	37.5-37-36-37
Thromboplastin D	13-13-12.5-12.5	21.5-21-21-20	30-28.5-28-28	49-51-41-42

preparations with longer 100% control times will give proportionately longer times in the more dilute mixtures.

2. *Results on Dicumarolized Plasmas*

Preliminary testing had indicated that there might be some consistency in the various results obtained with the different brands. This seemed to be particularly true when comparing Brand A with Brand B. Although Brand A almost always gave longer control times it was noted that it gave faster times than Brand B on dicumarolized plasmas with prothrombin times of over 20 seconds. This cross over was very common but enough exceptions were found to indicate it could not be relied on.

In testing the four brands simultaneously, the thromboplastin preparations were prepared by the same technician and the same source of normal plasma was used for control times as was used for making the curves. The tests were run on sets of 25 dicumarolized plasmas for four sessions so that in all 100 plasma specimens were tested with all four of the preparations.

It became apparent almost from the beginning that the dicumarolized plasmas gave unpredictable results with the various thromboplastins. There was no consistency in the results in that variations in time with one preparation bore no constant relationship with those of another. As noted earlier in comparing Brands A and B there was often the cross over with the longer times but there were enough exceptions to indicate this difference could not always be relied on. As would be expected, the differences shown with all preparations were most noticeable on plasmas over 20 seconds. Some notable examples of these variations may be seen in Table I. These are isolated examples but similar variations were found on many occasions and cannot reasonably be attributed to errors in technique. From the practical standpoint this is important because it will be noted that the differences may be considerable and the shortest times were often obtained with the thromboplastin giving the longest control time.

DISCUSSION

The purpose of this investigation was to make comparative studies of some of the commonly used commercial thromboplastin preparations. The plan of

study was, first, to make dilution curves with the various preparations using barium sulfate adsorbed plasma as a diluent and, secondly, to use the same lot preparations on dicumarolized plasmas. It is generally assumed that curves bear some relationship to control times, i.e., preparations giving longer control times give proportionately longer times in the more dilute mixtures. However all the curves were generally quite similar despite the control times and in one instance the fastest times in the dilute mixtures were obtained with a preparation having the longest control time (Table II). It was therefore apparent from these curves at least that using normal plasma one could not predict the time of the more dilute mixtures from the time obtained on the whole plasma.

From the similarity of the curves it seemed reasonable to assume that results on dicumarolized plasmas would be closely approximated. Comparable results were obtained but all too frequently there were differences which, as would be expected, were most marked in the plasmas with longer times. The differences could not be explained by differences in control times, as often the fastest times were obtained with the thromboplastin having the longest control time. On the other hand, preparations with identical controls both in the 100% and 10% range very often gave results which were quite different from each other. To add to the confusion a preparation which gave the fastest time on one plasma would often give the shortest time on another, or a time intermediary between the fastest and the slowest.

It seems fair to conclude from these results that the evaluation of at least these commercial thromboplastins is impossible, using these methods of comparison which are usually considered satisfactory. The fact that prothrombin determinations on normal undiluted plasmas is not a satisfactory method for the standardization of thromboplastin preparations is known and has been best expressed by Mann who stated: "In testing dicumarol plasmas, there appear differences between thromboplastin extracts that are not apparent in testing normal plasma. In other words, the sensitivity of thromboplastin extracts in detecting the abnormality produced by dicumarol varies entirely apart from the variation in the activities of these extracts with respect to normal plasma." Obviously, if two thromboplastin preparations give identical times on a single normal undiluted plasma but different times on a single dicumarolized plasma, they cannot be considered to be of standard uniform activity.

It was thought therefore that if prothrombin determinations were made on serial dilutions of normal plasma this difficulty would be overcome by revealing differences in the thromboplastin preparations not apparent with the undiluted plasma. Furthermore, it was thought that the differences found would be comparable to the differences noted when these same thromboplastin preparations were used with dicumarolized plasmas. To suspect that such a method for standardization would work, it would have to be assumed that the diluted normal plasmas were identical with dicumarolized plasmas.

Just what the differences are between normal plasma diluted with barium sulfate adsorbed plasma and dicumarolized plasma is not altogether clear. The very fact, as shown in this report, that different thromboplastin preparations

may react one way with plasma diluted in this fashion and in other ways with dicumarolized plasmas indicates that they are certainly not the same. The problem of determining what the exact differences are, both qualitatively and quantitatively, is exceedingly difficult with present techniques. The barium sulfate adsorbed plasma used as a diluent is depleted of prothrombin and there is also a marked reduction in a stable clotting factor, variously described in the literature as SPCA (5), proconvertin (6), co-thromboplastin (7), and factor VII (8). Dicumarolized plasma is also deficient in these factors so these plasmas may be considered generally similar in these respects. There is disagreement however as to the effect of dicumarol on the labile factor (Factor V) (9). Quick and Stefanini found that it was little effected but Fahey et al reported that it may be markedly depleted (10). On the other hand, it is generally agreed that barium sulfate adsorbed plasma contains ample labile factor. Koller is of the opinion that the hypoprothrombinemia from dicumarol, found by the one-stage method, represented a deficiency not only of prothrombin but also Factor V, Factor VII and fibrinogen and he felt that the reduction in Factor VII was probably the most important (5).

Without attempting to elaborate further on the differences between these plasmas it would appear that the normal diluted plasmas reacted much more uniformly with the commercial thromboplastin preparations used than did the dicumarolized plasmas. It is very probable that the in vivo effect of dicumarol produces disproportionate changes in the plasma constituents involved in the coagulation mechanism, whereas simple in vitro dilution of normal plasma produces a more orderly reduction of all the clotting constituents. The in vivo action of dicumarol is further complicated by the fact that different patients may respond differently to the drug, and also changes occurring early in treatment may be different than those occurring later (5, 10). It should not be surprising therefore that such complex plasmas may magnify subtle differences in thromboplastin preparations not ordinarily discernible when tested against normal or diluted normal plasmas.

It has been suggested that there might be a certain consistency in the differences revealed (2). This, if it were true, would be of value as results could be reported with reference to the brand name of the thromboplastin used. In the present study we were unable to confirm this "consistency of differences". One is steadily forced to the conclusion that the term "thromboplastin of standard uniform activity" when applied to its use against dicumarolized plasmas is meaningless and gives a sense of security which is not justified.

It may be contended that from the practical therapeutic standpoint present methods of standardization are satisfactory. This is to some extent true because the margins of safety are wide but no one should be deluded as to the facts. It is common experience that despite the utmost caution bleeding is still a frequent complication of dicumarol therapy even though the prothrombin time is within the "safe range".

While there is as yet no satisfactory method of knowing what constitutes a

good therapeutic range it is generally agreed that a 5–10% prothrombin level is satisfactory. Whether dicumarolized plasmas that give the same time as those of 5–10% normal plasmas with barium sulfate adsorbed plasma as the diluent, have a comparable prothrombin content is open to question. If it is comparable, prothrombin times need not exceed 25 seconds, using the thromboplastin preparations herein reported. Even at these levels fairly marked variations have been found and bleeding not infrequently occurs. A greater tendency to bleed, for some unknown reason, is probably an important factor in some of these cases and must be accepted as a calculated risk. Patients with peptic ulcers or exposed mucous membrane surfaces, such as colostomies, are grave risks and in our opinion should not receive anticoagulant therapy. It should also be remembered that even at normally "safe levels" considerable bleeding may follow the use of injections, particularly deep intra-muscular injections.

Curves made with saline as a diluent were entirely different from those made with barium sulfate adsorbed plasma and usually gave about 40 seconds at 10% with the same thromboplastins. Beyond this dilution clotting was greatly prolonged and the end points were not sharp. The much longer times in the more dilute mixtures with any diluent may represent only slight variations in the prothrombin concentration, percentagewise, but bleeding occurs much more frequently at these critical levels.

Selecting prothrombin times intermediary between those obtained from 5% and 10% normal plasma, prepared with barium sulfate adsorbed plasma as the diluent, may be arbitrary for the management of patients receiving therapy, but it at least serves the purpose of better evaluating clinical results.

SUMMARY

1. Prothrombin time curves on normal plasma with barium sulfate adsorbed plasma as a diluent were made, using four different commercial thromboplastins.

2. The type of curve bore no relationship to the control time with these preparations.

3. Prothrombin times were done on a large series of dicumarolized plasmas using simultaneously the four same thromboplastin preparations used above. Each thromboplastin preparation was from the same lot.

4. The findings indicated that the interaction of thromboplastin preparations with normal plasma, and normal plasma diluted with barium sulfate adsorbed plasma, is frequently different from the interaction of similar preparations with dicumarolized plasmas, and standardization cannot be accomplished in this fashion.

5. There was no indication that differences found between different thromboplastin preparations were consistent enough to be relied on for comparing results.

6. It is suggested that for management and comparative studies patients be maintained at a level equivalent to the time obtained on 5–10% normal plasma, using barium sulfate adsorbed plasma as the diluent. With the four commercial preparations used this would be about 25 seconds.

BIBLIOGRAPHY

1. Hurn, M. M., Barker, N. W. and Magath, T. B.: Determination of Prothrombin (2 stage method) and Antithrombin using commercially available reagents. Am. J. Clin. Path. 17: 741, 1947.
2. Conley, C. L. and Morse: W. I. Thromboplastic Factors in the Estimation of Prothrombin Concentration. A. J. M. Sci. 215: 158, 1948.
3. Rosenfield, R. E. and Tuft, H. S.: Estimation of prothrombin level from prothrombin time. Am. J. Clin. Path. 17: 405, 1947.
4. The Josiah Macy, Jr. Foundation: Blood Clotting and Allied Problems. p. 157, 1952.
5. Alexander, B., De Vries, A., Goldstein, R., and Landweir, G.: The prothrombin accelerator of serum (SPCA), its partial purification and its properties compared with serum ac-globulin. J. Clin. Invest. 14: 881, 1950.
6. Owren, P. A. and Bjerkelund, C.: A new previously unknown clotting factor. Scand. J. Clin. & Lab. Invest. 1: 162, 1949.
7. Mann, F. D. and Hurn, M.: The complex mechanism of the Quick prothrombin test and the effect of dicumarol. Am. J. of Clin. Path. 20: 225, 1950.
8. Koller, F., Loeliger, A. and Duekar, F.: Experiments on a new clotting factor (VII). Acta Hermat. 6: 1, 1951.
9. Owren, P. A.: Parahemophelia, hemorrhagic diathesis due to absence of a previously unknown clotting factor. Lancet 1: 446, 1947.
10. Fahey, J. L., Olivin, J. H. and Ware, A. G.: Effect of dicumarol on ac-globulin and prothrombin activity. Proc. Soc. Exp. Biol. and Med. 69: 491, 1948.

CONGENITAL MUSCULAR HYPERTROPHY WITH MENTAL DEFICIENCY (DE LANGE'S DISEASE)

ROBERT MARSHALL, M.D.* AND HORACE L. HODES, M.D.

In 1934 Dr. Cornelia de Lange (1) reported three cases of a syndrome of congenital generalized muscular hypertrophy, extrapyramidal motor disturbances and mental deficiency. To these she added a case reported by Bruck in 1889 (2). Since that time there have been seven other cases recorded in the world literature (3–9). We present the following case, the second reported American case, because of the unusual clinical circumstances and because, to the best of our knowledge, it is the first instance in which androgenic studies have been used in an attempt to establish the etiology.

CASE REPORT

C. M. G., a male infant of Jewish extraction, was born at the Mount Sinai Hospital on March 2, 1953, six weeks prior to term. The mother was 29 years old. She had borne one normal infant previously. She had been well until January 1953, from which time she noted progressive weakness of the lower extremities. She was operated upon on February 24, 1953 and was discovered to be suffering from a hemangioma of the spinal cord. Paraplegia developed post-operatively. On March 2, 1953 spontaneous, painless labor occurred, and she was delivered of the infant by low forceps. The father was 38 years old. He was obese and suffering from essential hypertension. Both his thyroid and renal function were normal.

Physical examination of the infant at birth revealed an apparently healthy 2240 gram premature infant. At 36 hours of age he voided grossly bloody urine. At that time there was moderate jaundice, and both kidneys were palpable and obviously enlarged. Hematuria persisted for five days. Laboratory data revealed no evidence of hemorrhagic or hemolytic disease. Blood cultures were sterile. The kidneys decreased in size to normal by the eighth day of life. Jaundice subsided by the third week of life. Urinalyses, blood urea nitrogen and serum electrolyte determinations all indicated persistence of renal damage. In view of the clinical and laboratory findings, a diagnosis of vascular disease of the kidneys, probably intra-renal renal vein thrombosis, was made. His urine function slowly improved, although the blood urea nitrogen levels remained elevated.

The infant's course in the hospital was marked by severe irritability and hypertonicity which were first noted at one week of age. He took feedings poorly and his weight gain was slow. There was recurrent normochromic anemia which was treated by multiple transfusions of whole blood. Despite his low weight and poor general condition, however, from the third week of life the infant showed muscular development much beyond the normal, and supernormal muscle power. By three months of âge the muscular hypertrophy was so marked that the infant presented the appearance of a small wrestler. There was generalized, symmetrical muscular hypertrophy, more marked over the upper half of the body, affecting mainly the muscles of the neck, upper extremities, chest and back. The muscles were soft during relaxation but during contraction they were very firm and stood out like bands beneath the skin. There was no myotonic reaction, and no delay in relaxation. The infant alternated between periods of lethargy and marked irritability. During the periods of irritability there was a raucous, high-pitched cry, marked hyperextension of the neck with assumption of an extreme opisthotonic posture, tonic contraction of the muscles, and marked tachypnea. These episodes were provoked by the smallest stimulus. There was

From the Department of Pediatrics, The Mount Sinai Hospital, New York, N. Y.
* Present address, 4333 St. Claire Avenue, Studio City, California.

rigidity and resistance to passive movement of all the limbs, which were held in a position of flexion of the major joints. Muscle power was excellent; the infant could hang from the fingers of the examining physician for longer than 60 seconds (see pictures). The cranial nerves were intact, the deep tendon reflexes were markedly hyperactive, and the abdominal and cremasteric reflexes were absent. Babinski, Hofman and Oppenheimer reflexes were present bilaterally. Ankle clonus was present bilaterally and the tonic neck reflex was strongly positive. Sensation appeared to be normal. Psychomotor development was poor. He did not smile or coo; he did not recognize the bottle or persons around him; he showed no interest in his environment. The facies was that of an old man. The panniculus was extremely poor. Hair was normal in texture and distribution. There was marked superficial venous engorgement. The kidneys were no longer palpable. The external genitalia appeared somewhat abnormal; the scrotum was deeply pigmented and wrinkled; the penis appeared longer and thicker than normal; the testes were normal in size.

Urinary 17 keto-steroid determinations performed at 3½ and 4 months of age, were 0.19 mgm. and 0.12 mgm. per 24 hours, respectively. Total blood cholesterol was 170 mgm.%; cholesterol esters were 130 mgm.%. Skeletal survey revealed normal bone age and changes suggestive of secondary hyperparathyroidism. Electroencephalography performed at 4½ months of age revealed diffuse abnormality with multiple, large, slow wave rhythms. Twenty-four hour urinary excretion revealed 28 mgm. of creatinine and no creatine.

During the period of observation, the clinical course of the patient progressed unchanged. The "infant wrestler" habitus became more pronounced. From five months of age, vomiting occurred with increasing frequency and there was a fall in weight. His nutritional status became progressively worse and he expired on August 24, 1953, at the age of 25 weeks.

Postmortem Examination: The body was small and emaciated (2700 grams) with extreme depletion of the subcutaneous tissues. Muscular hypertrophy was as described above. Microscopic examination of the muscles revealed no evidence of myotonia. Muscle cells were uniform in size; striations and staining reactions were normal. The picture was one of work hypertrophy. The kidneys were pale and atrophic with exaggerated fetal lobulation. The surface was finely granular. There was slight dilatation of the pelves and flattening of the papillae. Each kidney showed severe atrophy of the medulla and patchy atrophy of the cortex. The small peri-pelvic veins bilaterally revealed several thrombi which were organized and showed beginning calcification. The adrenals were normal except for a few small calcified thrombi in the central veins. The testes were normal with no adrenal rests or tumors. The heart revealed moderate hypertrophy of the left ventricle.

The brain was small with a relatively large cerebellum. The gyral pattern was altered with microgyri and macrogyri. There were large cysts in both temporal lobes. Section of the cerebrum revealed multiple intercommunicating cysts occupying a major portion of the central white matter of both cerebral hemispheres. The subcortical white matter was similarly involved; most markedly in the region of the temporal lobes. The lateral ventricles were distorted and somewhat asymmetrical. The left frontal horn was larger and deeper than the right and the right occipital horn was larger than the left. Both ventricles were dilated. Section of the cerebellum revealed the central white matter and the dentate nucleus to be decreased in size. The basal ganglia were grossly under-developed. Microscopic examination revealed areas of decreased cellularity in the cortex. The subcortical white matter varied in cellularity, the portion beneath the cortex being less cellular than in the central white matter. Many of the cells in the central white matter possessed elongated, deeply-staining nuclei. Small irregular cavities, present in the central white matter, were lined by a slight condensation of glial cells and fibers, and were traversed by irregular bands of similar glial tissue. Within the white matter were seen numerous granules and clumps of a deeply basophilic material. Some of the clumps formed large ovoid masses deposited in zones of necrosis. There were focal collections of xanthoma cells which were apparently filled with fat. The tissue surrounding these collections contained increased numbers of astrocytes and calcific deposits. The cerebellar white matter revealed occasional globular masses of basophilic material. Examination of the basal ganglia revealed large numbers of primitive cells in the subependymal zone. In some of these areas large masses of blood pigment along with numerous large astrocytes were noted. There were groups of foam cells in the tissue and peri-vascularly. Deposits of basophilic material were noted in the tissues and in the blood vessel walls. The areas of degeneration were devoid of neurons. Heterotopic glial nests were noted in the subarachnoid space.

The pathologic diagnoses were: (a) congenital muscular hypertrophy; (b) bilateral intrarenal renal vein thrombosis; (c) malnutrition; (d) infantile cystic encephalomalacia; (e) internal hydrocephalus, moderate; (f) deposition of basophilic material. Cause of death: nutritional failure.

DISCUSSION

This symptom complex of congenital muscular hypertrophy, extrapyramidal motor disturbances and mental deficiency is as yet poorly understood. In the reported cases one or the other of the components of the syndrome have predominated, although all have been present in each case to a greater or lesser extent. Of the twelve known cases, seven have died as a result of poor nutritional status or of infections secondary to it. Those who have survived have shown persistence of the muscular hypertrophy, mental retardation and hypertonicity with some improvement noted in the hypertonicity and even in the mental retardation. Growth has been maintained at a greatly reduced rate.

Only two other cases have had adequate examination at post-mortem. In the first case, that of Bruck (2), examination of the brain was not entirely satisfactory. The brain was reported as being normal except for disturbance of the gyral pattern. In the first case of de Lange (1) examination of the brain revealed essentially the same findings as in ours (marked diffuse porencephaly, moderate hydrocephalus and underdevelopment of the corpus striatum, especially the neostriatum). Morano-Brandi (8), in 1947, reported the results of pneumoencephalography in one case. There was generalized cerebral atrophy, most marked in the left cerebral hemisphere, as well as a moderate degree of hydrocephalus. de Lange postulated that the primary lesion was underdevelopment of the neostriatum associated with congenital porencephaly. She attributed the various extrapyramidal disturbances to the neostriatal maldevelopment. The exact mechanism of the muscular hypertrophy is not elucidated.

In our case an attempt was made to rule out all other possible etiologies. The normal urinary 17 ketosteroid values (12) eliminate the possibility that the muscular hypertrophy was due to, or caused by, adreno-genital syndrome, interstitial cell tumor of the testes or pituitary gonadotrophic stimulation secondary to the diffuse central nervous system disease. To the best of our knowledge this is the only instance in which that laboratory aid has been employed in such a case. Its value is self-evident. Skeletal surveys, which revealed normal bone age, aided in the differential diagnoses of the above conditions and of the so-called Debre-Semelaigne syndrome of hypothyroidism and muscular hypertrophy (10). In addition, the infant showed no stigmata of hypothyroidism and the blood cholesterol values were normal. The infant showed none of the characteristics of Thomsen's Disease. The age is against such a diagnosis and examination of the muscles failed to reveal any of the characteristics seen in that disorder. Pseudo-hypertrophic Muscular Dystrophy also may be eliminated readily. There have been no cases of muscular hypertrophy reported secondary to vascular disease of the kidneys (11), and the intra-renal renal vein thrombosis appears to be a coincidental finding in this case.

It is concluded that this is a distinct clinical syndrome based on a marked derangement of the central nervous system.

BIBLIOGRAPHY

1. De Lange, C.: Congenital Hypertrophy of Muscles, Extrapyramidal Motor Disturbances and Mental Deficiency. Am. J. Dis. Child., 48: 243, 1934.
2. Bruck, F.: Ueber einen Fall von Congenitaler Makroglossie combiniert mit allgemeiner wahrer Muskelhypertrophie. Deutsche med. Wchnschr., 15: 229, 1889.
3. Hall, B. F., Sunderman, F. W., and Gittings, J. C.: Congenital Muscular Hypertrophy. Am. J. Dis. Child., 52: 773, 1936.
4. Carrau, A., and Otero, M. V.: La Hipertrofia Muscular Generalizada Congenita. Arch. de Pediat. del Urug., 11: 29, 1940.
5. Arana, M. R., Gareiso, A., and Aguirre, R. S.: Un Caso de Enfermadad de Lange. Arch. Argent. de Pediat., 17: 339, 1942.
6. Middelhoven, A.: Un Petit "Lutteur", Syndrome de de Lange. Ann. Paediat., 166: 283, 1946.

7. Willemin Clog, L., Blanchet, S., and Travade, J.: Un Nouveau Cas de Typus Amstélodamensis: Coexistence d'une Hypertrophie Musculaire Généralisée. Arch. franç. de Pédiat., 4: 100, 1947.
8. Morano Brandi, J. F., de Caino, V. E., and Mazza, J. A.: Un Caso de Enfermadad de Lange. Arch. Argent. de Pediat., 27: 280, 1947.
9. LeComte-Ramioul, S., and Houet, R.: Contribution à L'Étude de L'Hypertrophie Musculaire du Nourrisson. Ann. Paediat., 174: 326, 1950.
10. Debré, R., and Semelaigne, G.: Syndrome of Diffuse Muscular Hypertrophy in Infants Causing Athletic Appearance: Its Connection with Congenital Myxedema. Am. J. Dis. Child., 50: 1351, 1935.
11. Zuelzer, W. W., Charles, S., Kurnetz, R., Newton, W. A., and Fallon, R.: Circulatory Diseases of the Kidneys in Infancy and Childhood. Am. J. Dis. Child., 81: 1, 1951.
12. Talbor, N. B., Butler, A. M., Berman, R. A., Rodriguez, P. M., and MacLachlan, E. A.: Excretion of 17 Ketosteroids by Normal and by Abnormal Children. Am. J. Dis. Child., 65: 364, 1943.

MASSIVE FRONTAL OSTEOMA; SURGICAL MANAGEMENT; REPORT OF TWO CASES*

MAX L. SOM, M.D. AND MANSHO T. KHILNANI, M.D.†

New York, N. Y.

Benign osseous tumors of the paranasal sinuses occur rather frequently but rarely give rise to clinical symptoms. However, because of potential growth beyond the sinus boundaries, the possibility of grave complications exists. Under these circumstances, surgical extirpation may be necessary. In two recent cases, surgical intervention was considered to be advisable. The roentgen and operative findings will be described.

According to Eggston and Wolf, osteomas form fifty percent of all tumors of the nose and paranasal sinuses (1). Childrey found fifteen cases of osteoma in 3,510 roentgen examinations of the paranasal sinuses, an incidence of about 0.41% (2). The frontal sinus is the most frequent site of the development of osseous growths. Malan, in his series of 455 cases of osteomas of the parafacial cavities collected from the literature up to 1938, showed that 39% of these occurred in the frontal sinuses (3). Teed, in his review of the literature, found 321 cases of frontal osteomas up to 1941 (4). He pointed out that these tumors have been variously described as "petrified brain, sinus calculi, enostosis and hyperostosis". Hooper, in 1828, was the first person to call these growths osteomas, but this term was not universally adopted until 1890 (5). Coppez (Novick) in 1899 was perhaps the first to make the roentgen diagnosis of osteoma of the frontal sinus.

Osteomas usually occur in the younger age groups, although they have been observed for the first time in later life. According to Moore 80% of the osteomas are seen before the fiftieth year (8). They occur more often in males and their rate of growth is unpredictable. They have been observed not to increase in size appreciably for considerable lengths of time. On the other hand, rapid growth has been reported in isolated instances. Trauma, infection and syphilis have been blamed for initiating or accelerating an osseous tumor. Teed, however, does not feel that trauma or infection play any part whatsoever, as a predisposing or exciting cause (4). In our two cases, there was neither a history of trauma, nor was there infection present at the time of operation. In younger people, osteoma have a greater tendency to grow. In this age group, it is therefore desirable that frequent x-ray examination be done to detect increase in size.

Brunner and Spiesman have classified osteomas into "eburnated or compact, cancellous and mixed varieties", the mixed variety being the most common with spongiosa forming the core (7). These authors believe that osteomas develop as a result of metaplasia of connective tissue with formation of bone by the paranasal mucosa which acts as periosteum. Osteomas have been known

* From the Department of Otolaryngology and the Department of Radiology, The Mount Sinai Hospital, New York, 29, N. Y.

† George Blumenthal, Jr. Fellow in Radiology.

to arise from any wall of the frontal sinus, including the intersinus septum and are covered by intact sinus mucosa.

Osteomas should be surgically removed whenever there is evidence of progressive expansion. Gerber (Teed) in 1907 aptly described this condition as "benign histologically but malignant clinically" (4). If the growth proceeds at the expense of the anterior sinus wall, it becomes manifest by deformity and prominence of the frontal sinuses. If expansion occurs laterally, ocular symptoms become progressively more noticeable. Should the growth proceed posteriorly, symptoms may be late in appearance and great risk of intracranial complication exists.

When growth occurs under observation, it is likely that expansion beyond the bony boundaries of the sinus is inevitable. Most dangerous of all the osteomas are those which erode the posterior wall of the frontal sinus or the roof of the spheno-ethmoid labyrinth. In such instances, the osteoma may lead to erosion of the dura with subsequent intracranial complications, even though the osteoma may be relatively small in size. Pneumocephalus and meningitis may be the first manifestations as reported by Cushing (8). Intracranial involvement may occur without direct bony erosion of the sinus wall by the tumor per se as a result of suppuration within the sinus. Infection may be secondary to interference with drainage caused by the substance of the tumor within the sinus lumen, occluding the naso-frontal passage. Pyoceles occasionally result from the retention of secretion with distention of the sinus boundaries and secondary purulent infection.

CASE REPORTS

Case # 1. G. J., a 14 year old boy, was first seen in February 1952, because of nasal obstruction of two months duration. There had been some deformity of the nasal tip since childhood as a result of the dislocation of the nasal septum from the columella. There was mucoid secretion in the right middle meatus and intranasal evidence of a right suppurative maxillary sinusitis. Lavage of the right antrum yielded a large amount of pus. This infection cleared up after three irrigations, supplemented by antibiotic therapy. X-ray examination of the paranasal sinuses showed an osteoma, measuring 2 x 1 cm. on a pedicle which appeared to arise from the floor of the right frontal sinus (Fig. 1a). The frontal sinuses appeared otherwise normal. The patient was followed by his family physician with frequent films of the sinuses. He next came under observation in 1954. Surgery had been recommended because of the increase in the size of the osteoma. Re-examination of the frontal sinus showed the osteoma to be almost twice its previous size (Fig. 1b). At this time, he was symptom-free except for occasional obstruction, attributable to septal deviation. He was admitted to the hospital and, on February 18th, 1954, a right, external frontal operation was performed under general anesthesia. A curvilinear incision was made starting midway between the inner canthus and the dorsum of the nose and continued laterally through the right eyebrow. The incision was carried down to the bone and the orbital periosteum was retracted downward, exposing the floor of the frontal sinus. The lachrymal sac was elevated from its groove and displaced. An opening was made into the floor of the right frontal sinus at its antero-mesial angle. The thin floor was removed along its entire extent, exposing the osteoma within the limits of the frontal sinus. The $2\frac{1}{2}$ cm. osteoma was attached posteriorly by a narrow pedicle. The tumor was removed by ablation of its limited attachment and was delivered complete through the floor of the frontal sinus (Fig. 2). There was no evidence of infection in the frontal sinus and the naso-frontal duct was not disturbed. The anterior wall of the frontal

FIG. 1a. *G. J. Feb. 1952.* Osteoma 2 x 1 cm. arising from floor of right frontal sinus. Pedicle can easily be identified. No evidence of infection.

FIG. 1b. *G. J. Two years later.* Osteoma appears to be twice the previous size. It appears to abut against the intersinus septum. No evidence of infection.

FIG. 2. *G. J.* Removed osteoma measures $2\frac{1}{2}$ x $1\frac{1}{2}$ cm. Surface is smooth and eburnated. Pedicle indicated by arrow.

sinus was not interfered with, in order to prevent subsequent deformity. The skin was approximated by interrupted sutures, after insertion of a drain at its outer angle. The patient made an uneventful recovery without any evidence of external deformity.

COMMENT

Surgical intervention was advised in this instance because of the increase in size of the osteoma under observation. There existed the likelihood that continued growth of the osteoma would sooner or later encroach upon the bony confines of the frontal sinus and produce either external deformity, ocular symptoms or intracranial complications. Since removal is a relatively simple procedure without any resultant deformity, it was undertaken promptly.

Case #2. M. F., a 15 year old, school boy, was admitted to the Mount Sinai Hospital in December 1954. He was entirely well until two years previously when, for the first time, his mother noticed a bump on his forehead, just above the root of his nose. No medical advice was sought during the next 15 months. At this time, roentgen examination of the paranasal sinuses was done which showed a homogeneous, osseous density occupying completely both frontal sinuses. There was a lucent zone surrounding the osteoma and dividing it into right and left. This lucent zone was interpreted as residual, sinus mucosa. The lateral view showed slight bulging of the posterior wall. The anterior wall of the sinus was intact (Fig. 3a, 3b). No therapy was advised and the patient was observed for the following six months. It was then felt that the protuberance was increasing in size and repeated x-ray examination was advised. This confirmed the suspicion that there had been an increase in the size of the swelling. There was increasing bulging of the anterior and posterior walls. The radio-lucent zone surrounding the osteoma was still present. The site of attachment could not be identified (Fig. 3c).

On admission, local examination showed a marked prominence in the region of the frontal sinuses, resulting in an elevation above the general surface of his forehead of about 2 cm. This protrusion extended over an area of 3–4 cm. to either side of the midline. There was no tenderness or redness over the deformity. The remainder of the physical examination was entirely normal. Intranasal examination revealed no evidence of suppurative sinus disease.

Under general anesthesia, a butterfly incision was made through the eyebrows and across the bridge of the nose. The periosteum of the left orbit was separated from the floor of the left frontal sinus and the ethmoid region. The lachrymal sac was displaced from its groove. By means of a sharp curette, the thin floor of the left frontal sinus was dissected from the bony tumor occupying the sinus cavity. The entire sinus lumen had been obliterated by the

FIG. 3a. *M. F. 1952.* Homogenous, bony density occupying right and left frontal sinuse with a surrounding lucent zone. Upper part of intersinus septum is well seen. Bony densit extends into the left ethmoid sinus.

FIG. 3b

FIG. 3c

FIG. 3b. *M. F.* Lateral view shows bulging and thinning of the anterior and posteri walls. Extension into the ethmoid sinus indicated by arrow.

FIG. 3c. *M. F. Two years later.* The antero-posterior diameter is markedly increased wit bulging of both anterior and posterior walls.

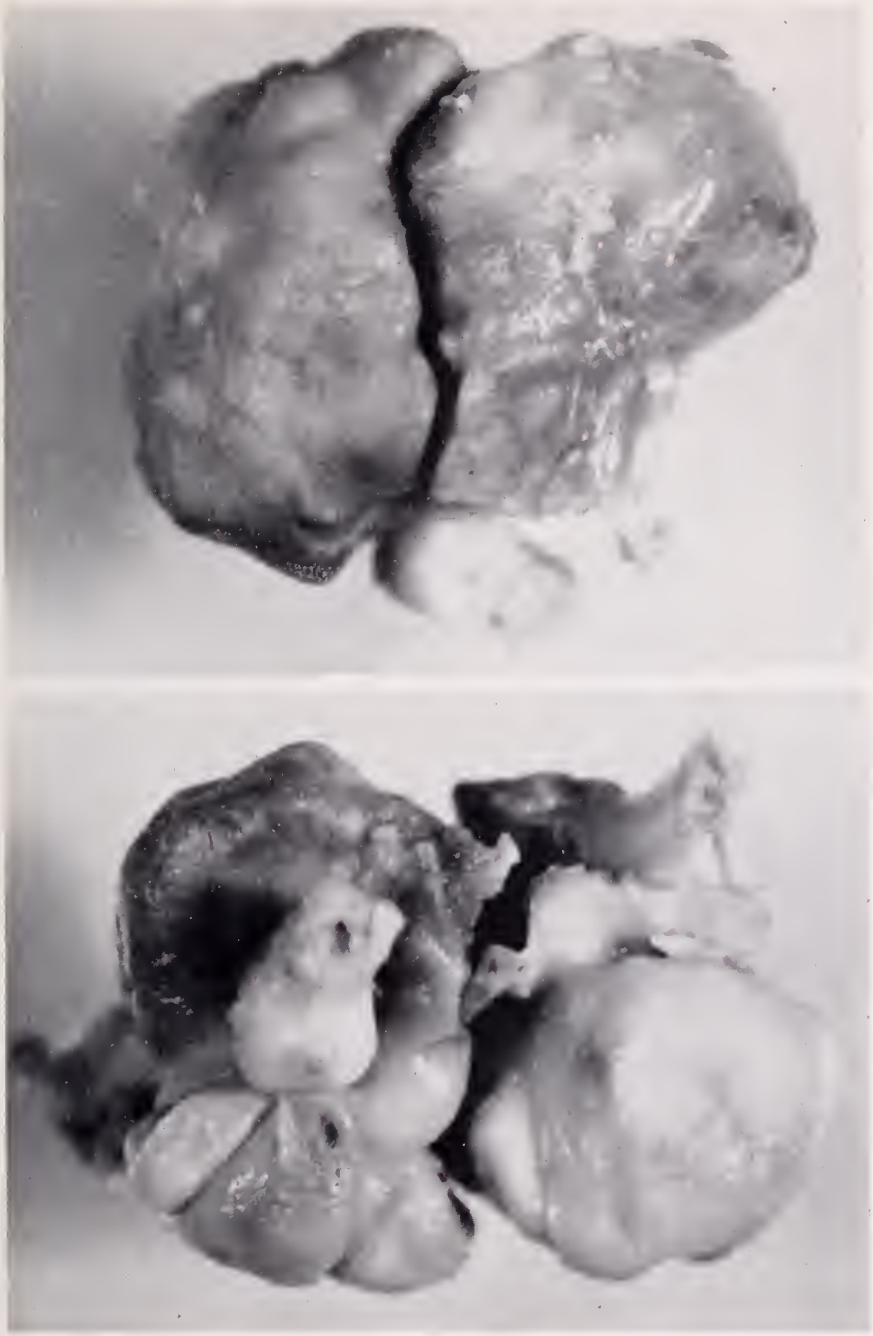

FIG. 4. *M. F.* Removed specimen 6 x 5 x 4 cm. (a) is a frontal view and (b) an inferior view. The central fissure represents the site of the intersinus septum. On the inferior view, the bony-extension into the ethmoid is seen.

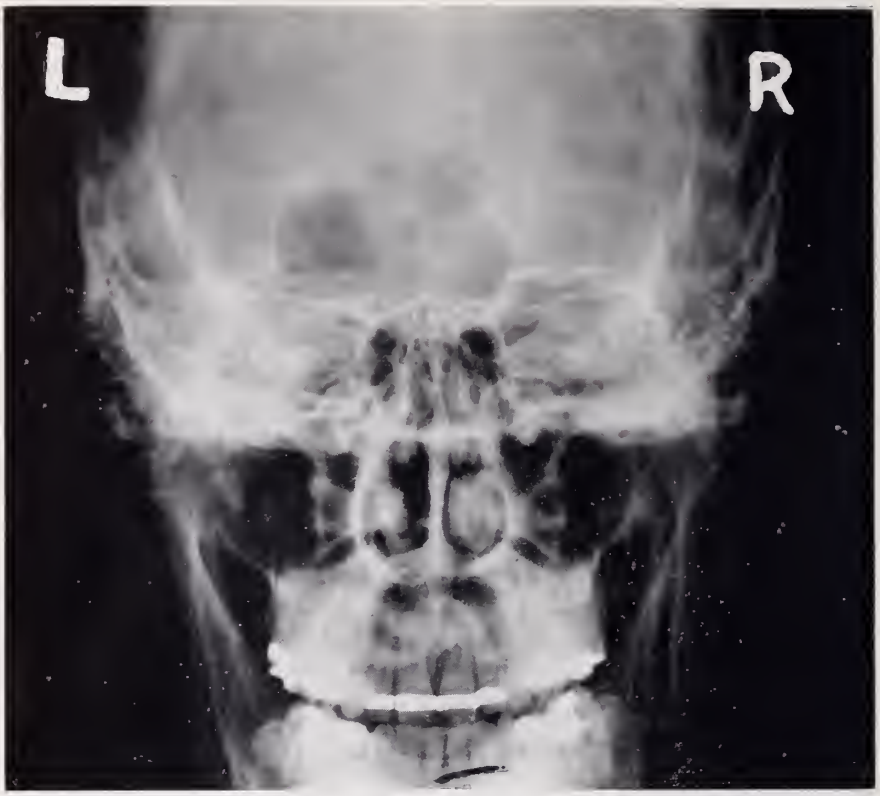

FIG. 5a. *M. F.* Post-operative P.A. view. Complete removal of osteoma is confirmed. The defects in the posterior wall are not recognized.

growth and the osteoma was so opposed to the bony walls of the frontal sinus that the mucosa was atrophic. The thinned out, bony floor of the frontal sinus was removed in its entirety, thereby defining the caudal limits of the osteoma, both laterally and posteriorly. Normal dura of the anterior fossa was uncapped laterally for orientation and mobilization of the lateral boundaries of the osteoma. The same procedure was then performed on the right side so that the entire floor of the right frontal sinus was similarly uncapped. A prominence was now noted on the mesial wall of the left orbit which was interpreted as being the site of origin of the osteoma. Further exposure of the osteoma was obtained mesially along the lamina papyracea. It was now determined that the osteoma originated in the left, anterior ethmoid region and produced a bulge into the mesial wall of the orbit anteriorly. The osteoma had eroded the frontal process of the left maxilla, the lachrymal bone and the lamina papyracea. It had thinned out the left nasal bone and the nasal process of the frontal bone. The anterior walls of both frontal sinuses were paper-thin and bulged anteriorly. Exposure of the tumor mass was continued by removal of part of the orbital ridge and glabella. The expansion of the tumor could be traced from its origin in the left anterior ethmoid region through the nasal process of the frontal, directly into both frontal sinus cavities, without destruction of the intersinus septum. The limits of the osteoma having been defined, the tumor was gently dislodged and delivered en masse, through the floor of the frontal sinuses (Fig. 4). After removal, two large, bony defects with dural exposure were identified where the osteoma had eroded the posterior wall. In this instance, part of the anterior wall of the frontal sinus had to be removed in order to get adequate exposure of the osteoma and a sufficient area for delivery of the tumor, through the floor. In most instances, there seems

FIG. 5b. *M. F.* Post-operative lateral view showing no depression of the anterior wall.

little need for removal of the anterior wall. Delivery can readily be effected through removal of the floor. There was no evidence at operation of any naso-frontal duct or passage. In spite of this, infection was not present. The intersinus septum was removed, thereby creating one large sinus cavity. A polyethylene tube of ⅜ inch in diameter was inserted into the left nasal cavity and anchored in the lumen of the left frontal sinus by a silk suture through the skin. The skin was then closed with interrupted sutures. Post-operative roentgen film showed complete extirpation of the tumor with retention of sufficient anterior wall to prevent significant deformity (Fig. 5a, 5b). The polyethylene tube was left in situ for three months so that epithelization around the new naso-frontal passage could be assured.

COMMENT

A perusal of the modern literature fails to reveal an osteoma of the frontal sinus of such magnitude as this case presented. Peculiarly enough, although the osteoma had eroded the posterior wall of the frontal sinus and produced dural exposure, there were no meningeal symptoms. The reason for the repeated roentgen examinations was the progressive deformity produced in the region of the frontal bosses. The neoplasm took origin in the anterior ethmoid region and proceeded to grow into both frontal sinuses, obliterating the entire lumen of the frontal sinus. The naso-frontal passage was completely occluded, yet no infection was apparent at the time of operation. It may therefore be assumed that the osteoma caused an obliteration and atrophy of the sinus mucosa before the naso-frontal passage was entirely obliterated. It is not clear why the osteoma, in its growth, spared the intersinus septum.

Because of the unusual large size of this osteoma, it was necessary to remove part of the supraorbital ridges and the caudal portion of the anterior sinus wall. This was done in order to provide sufficient room for delivery of the tumor and the ablation of the pedicle, which should in all cases be sought to avoid recurrence of the tumor. In other instances, where dural exposure has occurred, a fistula with pneumatocele have resulted. For such complications, Cushing (8) has suggested a trans-frontal osteoplastic craniotomy with closure of the fistula by transplantation of a flap of fascia lata.

Acknowledgement: We wish to thank Dr. Leo Davidoff for referring these two private patients for surgery.

BIBLIOGRAPHY

1. Eggston, A. A., and Wolf, D., "Histopathology of the Ear, Nose and Throat"; Baltimore, Williams and Wilkins Company, 1947.
2. Childrey, J. H., "Osteoma of the Sinuses, Frontal and Sphenoid Bone"; Archives of Otolaryngology, 30: 63, 1939.
3. Malan, cited by Salvadori, G.; "Osteoma of the Frontal Sinus"; Archives of Otolaryngology, 35: 671, 1942.
4. Teed, R. W., "Primary Osteoma of the Frontal Sinus"; Archives of Otolaryngology, 33: 225, 1941.
5. Hooper, R., "The Morbid Anatomy of the Human Brain"; London, The author, 1828, 14.
6. Moore, J. A., "Osteoma of the Para-nasal Sinuses with Report of Three Cases"; Laryngoscope, 61: 379, 1951.
7. Brunner, H., and Spiesman, I. G., "Osteoma of the Frontal and Ethmoid Sinuses"; Annals of Otology, Rhinology and Laryngology 57: 714, 1948.
8. Cushing, H., "Experiences with Orbital Ethmoid Osteomata Having Intracranial Complications, with Report of Four Cases"; Surg. Gynec. and Obs., 44: 721, 1927.
9. Tamari, M. J., and Weisman, E. B., "Massive Osteoma of the Ethmoid Sinus"; Annals of Otology, Rhinology and Laryngology, 61: 1017, March–Dec., 1952.
10. Beck, J. C., "Some Uncommon Types of Neoplasms about the Head; Osteomata of the Frontal Sinus; Multiple Myeloma; Intra-palatal Tumor"; Tr. Am. Laryng. Rhino., and Otol., Soc., 36: 375, 1930.
11. Novick, J. N., "Osteoma of the Frontal Sinuses",; Arch. Oto-laryngol., 46: 655, 1947.

THE JOSEPH H. GLOBUS MEMORIAL PRIZE

The first annual award of the Joseph H. Globus Memorial Prize has been presented to Dr. Mortimer Ostow for his paper entitled, "Electrical Response of the Cerebral Cortex to Corticopital Impulse: A Comparison of Peripheral and Contralateral Cortical Stimulation". The Prize committee, Dr. Paul Klemperer, Chairman; Dr. Eli Moschcowitz and Dr. Mark Ravitch, unanimously chose it as the best of those papers that qualified for consideration. The prize is offered only to junior members of the staff up to the level of Assistant Attendings in order to stimulate the interest of the younger members of the Hospital staff in the Journal of The Mount Sinai Hospital.

The award is named for Dr. Joseph H. Globus, who founded and for twenty years zealously served as editor of the Journal of The Mount Sinai Hospital.

Important Notice
TO SUBSCRIBERS

Changes in your address should be made in writing:

1. *To The Editor*, The Journal of the Mount Sinai Hospital, 1 East 100 Street, New York 29, New York. Notice should be given 60 days preceding your change of address, and your old and new address should be given.

2. *To your Postman.* Ask him for Form 22 and Form 22-S and fill these out carefully.

We regret that in instances of change of address guarantee cannot be made of replacement of issues not received. If you have recently had a change of address and have failed to receive the publication, assure delivery of future issues by writing promptly to The Editor.

THE JOURNAL OF
THE MOUNT SINAI HOSPITAL

THE MOUNT SINAI HOSPITAL

announces

POSTGRADUATE COURSES IN CLINICAL MEDICINE

given in affiliation with

COLUMBIA UNIVERSITY

July through December, 1955

PART-TIME COURSES OF VARYING LENGTH

General and Special Pathology	September 24, 1955 to Jan. 14, 19
Neuropathology	September 30 to December 2, 19
Pediatric Cardiology	October 5 to December 21, 19
Radiology of the Chest	October 17 to 25, 19
Physiology, Normal and Pathological	October 19, 1955 to April 25, 19
Clinical Cardiology	October 25 to December 27, 19
Radiology of the Chest (Diff. Diagnosis in)	October 31, 1955 to January 23, 19
Hematology	November 1 to December 20, 19

INTENSIVE COURSES (FULL-TIME)

Minor Surgery for General Practitioners	October 3 to 5, 1955 (3-day cours
Elementary Electrocardiography	October 24 to 29, 19
Advanced Electrocardiography	October 31 to November 5, 19
Spatial Vectorcardiography, etc.	November 7 to 12, 19
Office Proctology	November 14 and 15, 1955 (2-day

COURSES FOR SPECIALISTS

Rhinoplasty and Otoplasty	July 16 to 30, 1955 (Full-time cours
Trans-meatal Surgery	September 12 to November 7, 19
Electroencephalography (Clinical)	September 29, 1955 to Jan. 19, 19
Radioactive Isotopes (Clinical Use of)	October 6, 1955 to May 31, 19
Nuclear Radiation Physics	October 12, 1955 to Jan. 25, 19

COURSES OF WHICH DATES ARE TO BE ARRANGED

Laboratory Training in Clin. Electroencephalography	a 3-months cour
Use of Radioactive Iodine	October through December, 19
Radiotherapy	A six-month or twelve-month course (by arrangemen

For application forms and information address
the Registrar for Postgraduate Medical Instruction
The Mount Sinai Hospital, 11 East 100th Street, New York 29, New York

In Memoriam

ISRAEL STRAUSS
1873–1955

On April 4, 1955, less than three months before he would have attained his eighty-second year, Israel Strauss died quietly in his office from a brain hemorrhage; and so passed away an eminent figure in American neurology.

Dr. Strauss was born in Pawtucket, Rhode Island on June 23, 1873. He received his A.B. degree from Brown University in 1894 and his M.A. and M.D. degrees from Columbia University and the College of Physicians and Surgeons in 1898. After an internship at The Mount Sinai Hospital he spent a year in Vienna studying neurology. On his return he became Adjunct Attending Physician at the Beth Israel and The Mount Sinai Hospitals. He soon transferred to the neurological service under Dr. Bernard Sachs at The Mount Sinai Hospital and served the Hospital as Neurologist until his retirement as Attending and Chief of Service in 1938. For many years, he was also Associate Neuropathologist to the Hospital. Beginning in 1903 as instructor in histology at the Cornell University Medical School he attained the rank of Assistant Professor of Neuroanatomy, a position he held until 1917. For many years he served as Attending Neurologist to the Montefiore Hospital in New York and the Jewish Hospital in Brooklyn. On retirement he became Consultant in neurology at The Mount Sinai, the Montefiore, the Morrisania and the Maimonides Hospitals.

Israel Strauss was a member and past president of the American Neurological Association. He was also a member of the American Psychiatric Association and the Association for Research in Nervous and Mental Diseases. As Fellow of the New York Academy of Medicine he was Chairman of its Section of Neurology and Psychiatry, and from 1929 to 1940 served as Chairman of the Special Committee of Medical Jurisprudence. In 1917 he organized and became President of the Committee of Mental Health among Jews and founded the Hillside Psychiatric Hospital, over whose destiny and development he presided till the end of his days.

Though Dr. Strauss was not a prolific writer he published several very good papers on a variety of neurological subjects. His most outstanding contribution of social, communal and psychiatric significance was his creation of the Hillside Hospital. From its inception as a small sanitarium it blossomed under his acting guidance into an unusually fine and exceptional institution, which will forever remain as a monument to his creativeness and to his social vision.

Dr. Strauss was a good physician, a very good neurologist, and a scientist of intellectual integrity. He possessed moral courage to a high degree. He was fatherly and helpful to many aspiring neurologists and psychiatrists whose careers he tried to guide and for whose training he often provided financial support from private sources and public funds. In recent years he provided fellowships for many young scientists with funds from the Dazian Foundation.

Israel Strauss

Israel Strauss was intolerant of sham, and so he was occasionally impatient and outspoken in his criticism of people and things. He could not or would not garnish the truth as he saw it, perhaps in the somewhat innocent belief that one may speak it out raw. People who knew him only superficially or merely contacted him tangentially sometimes misunderstood and misjudged him. He was a highly ethical practitioner and a kind man with a warm and generous heart. The Mount Sinai Hospital has lost one of its worthy sons. As his pupil and successor at the Hospital I had deep regard for him, and I shall, together with all his friends and many of his associates, continue to cherish his memory.

I. S. Wechsler, M.D.
For The Editorial Board

Dr. Kaufman Schlivek

In Memoriam

DR. KAUFMAN SCHLIVEK
1881–1955

On March 31, 1955 Dr. Kaufman Schlivek died at his home, after an illness of several years. He was held in high esteem by his colleagues, students and friends. His experience in medicine and in his specialty was very large, and his interest in both was quite active up to the time of his death.

Dr. Schlivek was born in New York City seventy-four years ago. He attended the public schools and received his B.S. from the College of the City of New York in 1900. He was graduated from the College of Physicians and Surgeons of Columbia University in 1904. The following year he became associated with The Mount Sinai Hospital as an interne. In the early part of his medical career he spent several years in general practice and devoted considerable time to the Nose and Throat and Pediatric clinics at The Mount Sinai Hospital. But he soon became interested in ophthalmology and had the good fortune to be associated with John E. Weeks, Arnold Knapp and John M. Wheeler, all great teachers, who helped train him in his career.

In 1917 he was appointed Adjunct Attending Ophthalmologist to The Mount Sinai Hospital, became Associate Attending Ophthalmologist in 1921, Attending Ophthalmologist in 1932, and finally Consulting Ophthalmologist in 1943. He was associated for a long time with the New York Eye and Ear Infirmary.

For many years he taught ophthalmoscopy. His chief aim was to instruct younger men, and all associated with him profited. Possessed of a keen clinical insight, he always sought to impart his techniques and knowledge to those who received training under him. His capacity for work was outstanding and his tremendous practice indicated the great admiration and friendship his patients had for him. His life was one of achievement. To have worked with him was a rare privilege.

Dr. Schlivek was a former Clinical Professor of Ophthalmology at the College of Physicians and Surgeons, Columbia. A fellow of the American College of Surgeons, he was also a diplomate of the American Board of Ophthalmology and Otolaryngology, the New York Academy of Medicine, the American Medical Association and the New York State and County Medical Societies.

At his death, he was Consulting Ophthalmologist to The Mount Sinai Hospital in New York, the New York Eye and Ear Infirmary and the St. Joseph Hospital, Far Rockaway, Queens. Posthumously, he received the Jacobi Medallion for metitorious service to the Alumni Association and The Mount Sinai Hospital.

Dr. S. Miller
For The Editorial Board

SYMPOSIUM
on
REGIONAL ILEITIS

Guest Editor
BURRILL B. CROHN, M.D.

EDITOR'S NOTE

With Dr. Burrill B. Crohn as Guest Editor this Symposium on Regional Ileitis is presented as the first in a series.

It is intended that these symposia cover areas in which workers at The Mount Sinai Hospital are at the present time engaged on a broad front, or fields to which they have made significant contributions.

Since the seminal paper on Regional Ileitis was by Drs. Crohn, Ginzburg and Oppenheimer, it is fitting that the first be Guest Editor and the second the author of the article on its surgical management.

LESTER R. TUCHMAN, M.D.

THE EARLY DAYS OF REGIONAL ILEITIS AT THE MOUNT SINAI HOSPITAL—REMINISCENCES

BURRILL B. CROHN, M.D.

New York, N. Y.

In my fourth year as a student at the College of Physicians and Surgeons (1906) the text book was Osler's *Practice of Medicine*. I well recall the then professor of clinical medicine saying, "The next chapter deals with diseases of the small intestine; we will skip that chapter since nothing is known about that section of the bowel, if any diseases really exist." Such was the view as of that day and yet after all these years that remark remained indelibly in my student memory as a stark, if negative, fact. On the other hand, as an interne in pathology under Dr. Emanuel Libman, I was at all times, under his admonishing discipline, forced to open the entire length of small intestine as part of every routine autopsy although disease of moment was rarely discovered. Obviously in spite of this routine autopsy minuteness, ileitis was never seen at post mortem examinations because autopsies in fatal cases of ileitis are even today extremely rare.

The fog that beclouded the small intestine was the preoccupation and preconception that all disease processes in the small bowel were tuberculous in origin and nature. Ileocecal tuberculosis was a common end stage of pulmonary phthisis but, since at the Mount Sinai Hospital we regularly transferred such cases to other specialized institutions, it was rarely observed at autopsy. Primary ileocecal tuberculosis of bovine origin was supposedly common and may have been more frequent in the days before state sanitary herd inspection, yet a review of twenty five years autopsy material at the hospital, when critically analyzed revealed only four authentic cases of primary intestinal tuberculosis of which only one, in my experience, occurred in a specimen following surgical resection; and this was about fifteen years ago.

The same misconception and misinformation applied at that decade to the origin and nature of rectal fistulae. It was routinely taught and maintained that over 90 per cent of perirectal fistulae were tuberculous in origin and such an eminent specialist as Lockhart-Mummery in England so taught. The first clinical case of regional ileitis was a young man of sixteen years of age with diarrhea, fever, a mass in the lower right abdomen accompanied by pain. X-ray of the lungs was negative for tuberculosis; the Von Pirquet test, and the intradermal tuberculin test were negative. The intraperitoneal insufflation of oxygen led to no decided improvement. With scientific curiosity aroused and with the insistent urge to accomplish relief or cure, Dr. A. A. Berg was approached with the request for surgical exploration. Once again the cloud of tuberculosis preconception rose to confuse and thwart the logical demand. Dr. Berg related that at the insistence of the Saranac group he had operated upon five cases of intestinal tuberculosis in the hope of finding a cure for the local intestinal complication of phthisis. Of

From the Department of Medicine, The Mount Sinai Hospital, New York, N. Y.

the five cases, three died soon after operation, two were not relieved even in their terminal hopeless state and Dr. Berg at first refused to reopen that discouraging chapter of intestinal surgery. But with argument and with presentation of the negative facts, persuasion succeeded, for Berg was an adventuresome surgeon, of great technical dexterity and well-earned self-confidence and with a mind open to the logical presentation of scientific facts.

The resection of the ileocecal and ileal segment in this case gave the opportunity for the determination of the non-specific origin of this granulomatous disease (1930). (Incidentally, the sister of this young patient was operated upon a few years later for regional ileitis and constituted the first instance of familial involvement. It is further of interest that these siblings are today alive, well and free of recurrence twenty five years later.) Within a year, the involved area in thirteen more cases of terminal ileitis was resected by Berg. It soon developed that the abdominal wall fistulae was the important clue to the recognition of such cases. We had in the wards many chronic cases of diarrhea with persistent abdominal fistulae, the nature of which were not discernible. They were supposedly tuberculous in nature without tubercle bacilli, or actinomycotic without actinomyces. These cases were then collected, one with eleven abdominal fistulae, and resections were performed.

When the time approached for publication of a comprehensive paper, Dr. Berg magnanimously declined to be a coauthor, pointing to the fact that coincidently Dr. Leon Ginzburg and Dr. Gordon D. Oppenheimer had been collecting and studying the pathological characteristics of non-specific granulomata of the gastro-intestinal tract. Thus logically were combined the fundamental pathology of non-specific intestinal granulomas with the clinical picture of those granulomas which because they occupied the final loop of small bowel, led to the title of "Terminal Ileitis, A Pathological and a Clinical Entity." The paper was read on a hot day in May 1932 at New Orleans at the annual meeting of the American Medical Association, and was discussed by Dr. J. A. Bargen who suggested that the name of the disease be changed to Regional Ileitis since it was likely that the pathological process might some day be found to involve upper segments of ileum or even jejunum. In his prescience Bargen anticipated the descriptions of ileojejunitis and localized jejunitis and even duodenitis which was to follow in time, and did follow within a few years.

It is of some interest to note the rapid acceptance of Regional Ileitis by the scientific world. Within a year the subject was being discussed at a surgical congress in Germany and the Mayo Clinic, shortly thereafter, published a comprehensive paper confirming our findings and enlarging, with their abundant clinical material, our original concepts.

On my return from New Orleans I was requested by Dr. John Kantor to review some of his radiographic films. With meticulous care, Kantor had retained all of his interesting intestinal films of many years experience and on my visit had arranged an exhibit of past films which he had observed but had been unable to interpret. Obviously he had been seeing ileitis but had not recognized the essential import of his findings. He noted that the films seemed to resemble a "string" such as had been described in the large bowel cases of spastic or irritable color

and he called it a "string sign" a name which remains as a classical description of the radiographic manifestations of regional or terminal ileitis.

The rapid development of a surgical approach for the cure of the disease gave the opportunity for marked development and enlargement of our knowledge of the pathology of the underlying process. Fortunately for us, resection was first adopted as the logical surgical approach, for thereby we were enabled to receive pathological specimens for close study, an opportunity which disappeared later with the adoption of short circuiting procedures as a less risky and equally satisfactory cure for the disease process. The original operation was performed in two stages, an ileotransversostomy and ileal transection, followed some weeks later by a localized resection of the primary diseased segment. But when the second stage was performed it was noted that complete healing of the original lesion had occurred as a consequence of the by-pass procedure, and thereafter the second stage of the operation was omitted and our interesting specimens ceased to reach the laboratory.

The pathological study of the basic phenomena of the disease was credited to the careful studies of our coauthors Ginzburg and Oppenheimer and to the meticulous care and ever kindly and freely granted advice of Dr. Paul Klemperer, Pathologist to the hospital and to his staff. With time the concept of regional ileitis has been extended to include ileojejunitis, forms of localized jejunitis, the now recognized involvement of the duodenum in the same process and even cases where the stomach and exceptionally the oesophagus are identically the seat of disease. In the upper alimentary tract the process is no longer granulomatous as in the terminal ileum but is ulcerating and often stenotic and is not characterized by fistula formation, a process which is signally typical of terminal ileitis.

Actually, in time, the description of right-sided or segmental colitis had preceded the recognition of regional ileitis, for in 1930 Bargen had published a significant study on this subject. Combined ileitis and colitis was first recognized by Colp. A paper by Crohn and Rosenak from The Mount Sinai Hospital in 1937 included a study of nine cases of so-called combined ileocolitis. We think of ileitis in its classical form, as a pure type of disease to which the colon is regularly immune.

In the concept of ulcerative colitis we presume the disease to be different and unique, and any involvement of the terminal ileum is due purely by accident to "back-wash" through the patent but insufficient ileo cecal valve. The resultant ileal disease is superficial and does not represent true regional or terminal ileitis. But combined-system disease does occur and not infrequently, a subject which will be elaborated in this symposium by Dr. H. Yarnis. Such combinations of these two unitary diseases can take place identically in time (synchronous) or may occur in sequence (metachronous). Thus if one designates ileitis as "E" and ulcerative colitis as "C" the following variations may occur:

E = pure regional ileitis
C = pure ulcerative colitis
EC = synchronous combined ileocolitis
E + C = primary ileitis to which later ulcerative colitis is added.

C + E = ulcerative colitis in which later in time enteritis or ileitis occurs as a complication.

These confusing and bewildering combinations of the two diseases defy medical and often surgical treatment and lead to disappointment. Perhaps permanent and high ileostomy and colectomy offers the greatest eventual relief and the prospect of return to efficiency and health.

This generation has seen the passing of many of the fetishes of the past, of the Age of Faith and compliant belief. Chronic appendicitis, acalculous gall bladder disease, colonic bands, gastroptosis and coloptosis, tuberculous rectal fistulae; these are some of the preconceived concepts that have been banished by the advent of the Age of Reason and the Age of Enlightenment. Doubt, honest sceptical doubt, leads to reasoning, to seasoned observation, to forward experimentation. Doubt in the hands of men who are sufficiently self-confident to be willing to enter fields not satisfactorily explored, leads to new, wholesome and often surprising rewards for the inquisitive and acquisitive mind.

PATHOLOGY OF REGIONAL ENTERITIS AND REGIONAL ENTEROCOLITIS

SADAO OTANI, M.D.

New York, N. Y.

Since the publication of the classical paper by Crohn, Ginsburg and Oppenheimer in 1932, regional ileitis has been recognized as a clinico-anatomical entity.

The disease process, however, is not limited to the terminal portion of the ileum, but also occurs in the jejunum; an apparent initial involvement of a portion of the jejunum has repeatedly been observed. It was for this reason that the term, regional enteritis has subsequently been adopted. Furthermore, colonic involvement also has been added to this group, namely, the existence of regional enterocolitis which has been emphasized in recent years. It seems that the term has been used in a widest sense, and there is a possibility that ordinary chronic ulcerative colitis may have been included in this group. This has caused much confusion as to the pathogenesis of regional ileitis. A certain number of investigators have been inclined to believe that regional enteritis as an anatomical entity does not exist.

It seems to me that a great deal of confusion is based upon a lack of a precise anatomical definition of enterocolitis. It may be appropriate, therefore, to describe again the pathological-anatomical pictures of regional enteritis and regional enterocolitis.

REGIONAL ILEITIS

Macroscopic picture. The pathological disease process may show variation among different cases; it is quite natural to find various forms, namely a typical form and an atypical form. The latter may cause some confusion in regard to an interpretation of the disease process.

When a resected specimen of regional enteritis is examined, the lesion is usually quite advanced. An early stage of this disease process is rarely seen since a surgical resection usually is performed in advanced cases. It is for this reason that the disease process, in a typical instance, generally is seen as a segmental thickening of small intestine, with the lumen being markedly narrowed. The wall of the small intestine may measure 7 mm. in thickness in an extreme case. On palpation, it feels like an infiltrating scirrhus carcinoma; it is hard and rubbery in consistency. The serosal surface shows considerable vascularity and evidence of fibrous adhesions. Multiple pin-head size nodules can be seen on the serosal surface. The mucosal surface, in general, is ulcerated and covered by a fresh purulent exudate. Because of non-ulcerated mucosal islands, the mucosal surface presents a granular, cobble-stone appearance (Figs 3A and B). The ulcerated portion of mucosa is covered by a purulent exudate.

From the Department of Pathology, The Mount Sinai Hospital, New York, N. Y.

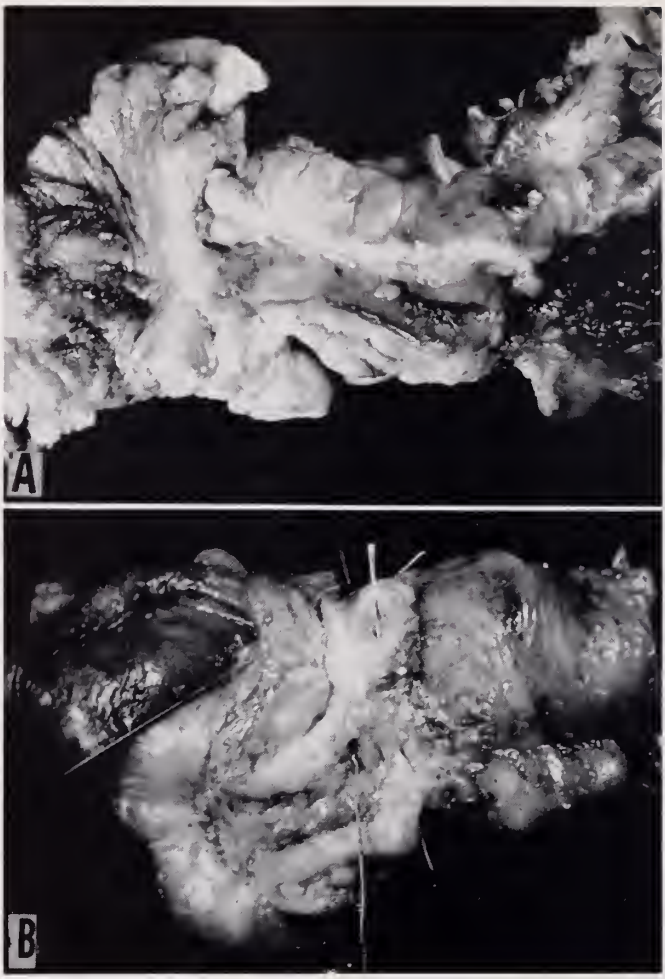

Fig. 1 A. Typical regional ileitis. Note segmental thickening of terminal ileum with narrowing of lumen. Colon is not involved. B. Typical regional ileitis involving terminal portion of ileum with marked narrowing of lumen. Note multiple fistulous tracts.

Characteristically, fistulous tract formation occurs from the thickened, ulcerated areas. The tract lead to the cecum, ascending colon (close to the ileocecal valve), to adherent portion of small intestine, or to the sigmoid colon. The tracts can be multiple (Fig. 2.).

The granulomatous process involving the small intestine is characteristically segmental, and the adjacent portion of small intestine appears completely normal. It is very common to find the terminal portion of ileum initially involved by this granulomatous process, but the lesion may begin 10 cms. from the ileocecal valve. Each diseased segment may vary in length, in some instances involving 20 cms. of small intestine. Small, similar segmental lesions often are found proximally, alternating with adjacent, normal areas of small intestine. The term "skipped lesion" is conveniently used to describe these segmental diseased areas. The

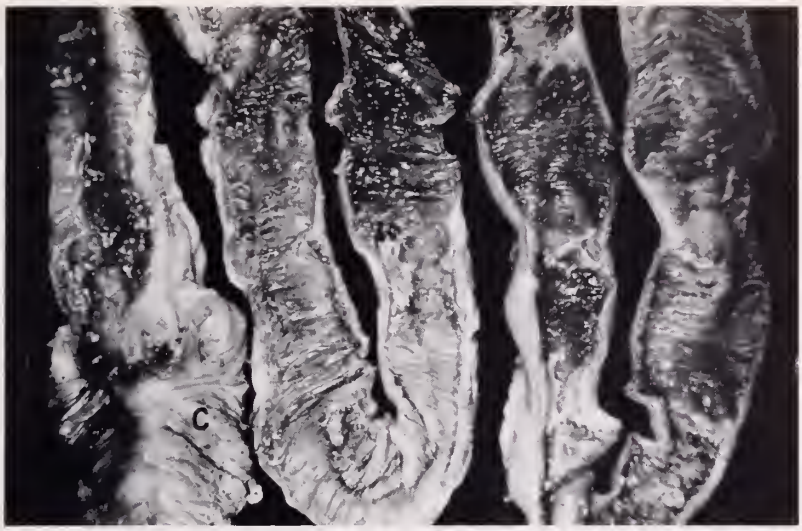

FIG. 2. Regional ileitis involving almost entire ileum with twelve skipped lesions. Note an absence of colonic involvement (C).

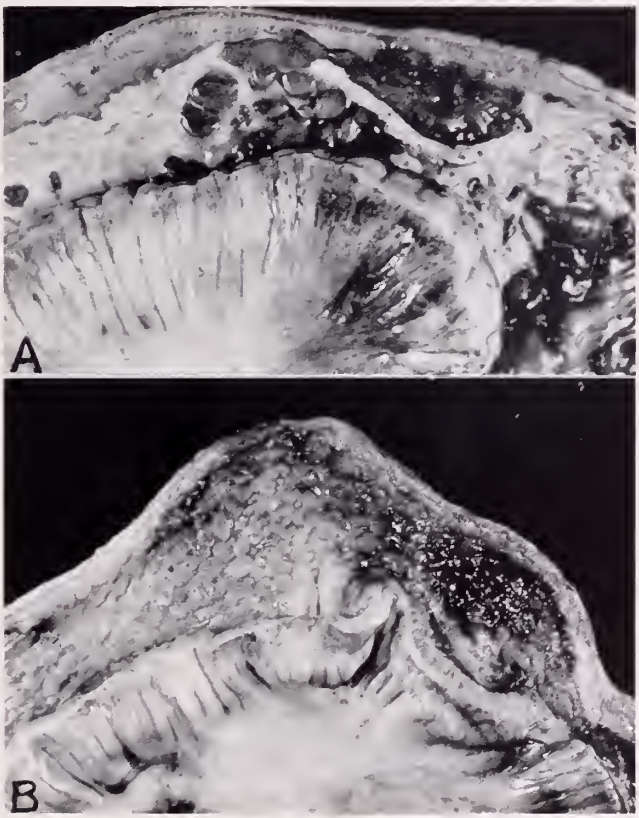

FIG. 3 A. A portion of regional ileitis with ulcerations of mucosa and acute purulent exudate. Note marked thickening of wall of ileum. B. Regional ileitis with cobblestone appearance of mucosal surface. Note typical thickening of wall of ileum.

skipped lesions can be multiple. In an extreme instance, the author has observed in one resected ileum twelve skipped lesions spread over almost the entire specimen (Fig. 2). The portion of bowel between the skipped lesions is often distended, but appears to be normal, except for occasional small ulcerations of the mucosa.

When the granulomatous lesions begin at the terminal portion of the ileum, it is a general rule that the lesion stops abruptly at the ileocecal valve and does not extend into the colon. If the cecum or the ascending colon is involved, it is always limited to a small portion of colon. Involvement of the right colon is exceptional. In fact, the involved portion of right colon is so limited, that it is the writer's opinion that the inflammatory extension into the colon may have been caused by direct fistulous tracts from the terminal portion of the diseased ileum. It is not unusual to find fistulous tracts between the ileum and right colon (Fig. 1B).

Microscopic picture. The gross appearance of regional enteritis in advanced cases is more or less identical. The microscopic picture, however, varies a great deal among individual cases. This variation may be roughly divided into two main groups:

A) Advanced, granulomatous enteritis with a thickened wall, but still showing acute inflammation. Submucosal abscesses may be seen.

B) Grossly identical with group A, but an acute inflammatory process is not present. The extremely thickened, fibrotic submucosa shows focal collections of large numbers of plasma cells and lymphocytes. The lesions usually are found in cases that previously have had an anastomosis between the ileum and the colon so that the diseased segment has been bypassed (Fig. 10B).

The first group is actually the significant one in the study of the pathogenesis of regional enteritis. It is this group of cases that shows granulomatous lesions. An outstanding aspect of the microscopic picture of Group A cases is the extensive collections of plasma cells and lymphocytes in the submucosa which is markedly fibrosed. This may give the misleading impression that the gross segmental thickening of the intestinal wall is actually due to submucosal inflammation. However, a considerable degree of inflammation of the hypertrophic muscle layers, inflamed serosa, and fat tissue around the intestine also account for the segmental thickening of the intestinal wall, which is so characteristic of this disease process (Figs. 5 and 6). If the mucosa is ulcerated, it is often covered by an acute purulent exudate.

Multiple, small epithelioid tubercle-like nodules with occasional giant cells can be seen scattered in the submucosa, muscle layers, the thickened serosa and in the fat tissue around the intestine (Figs 6, 7, 9 and 10). These miliary granulomatous lesions are by no means a constant occurrence in each case. In some instances, they are quite frequent, while in others they are rare. Some of the tubercle-like structures may show central necrosis; some are actually suggestive of caseation (Figs. 10C and E). However, repeated examinations for acid-fast bacilli have failed to disclose a single tubercle bacillus. Among these tubercle-like nodules, there are sporadic epithelioid cell collections close to the blood vessels (Fig. 7C) which simulate tuberculous vasculitis.

As to giant cells, there are distinctly two types: Langhans type and foreign

FIG. 4 A. Regional jejunitis with multiple skipped lesions. Note dumbbell shaped appearance. B. Regional jejunitis showing three skipped lesions. Mucosal ulcerations can be seen in dilated portions of jejunum.

body giant cell type. There is no question that some of the giant cells found in the diseased portion belong to the foreign body type of giant cells, since actual foreign bodies can be demonstrated in the cells (Fig. 10F). It is felt that these foreign bodies have been adsorbed from the ulcerated, mucosal surface.

The lymphocytic infiltration in the submucosa and serosa often form a lymph follicle arrangement and a cross section of the diseased portion of small intestine often shows numerous follicles forming a row along the serosa (Figs. 5 and 10A).

Another important lesion is the deep, narrow, ulceration which occurs in the mucosa. The acute purulent inflammation which tends to form abcesses extends from the ulcerated mucosal surface into the submucosa, and sometimes deep into the muscle layer (Fig. 5B). In some sections, this acute purulent inflammatory process may appear as a small submucosal abcess. These submucosal puru-

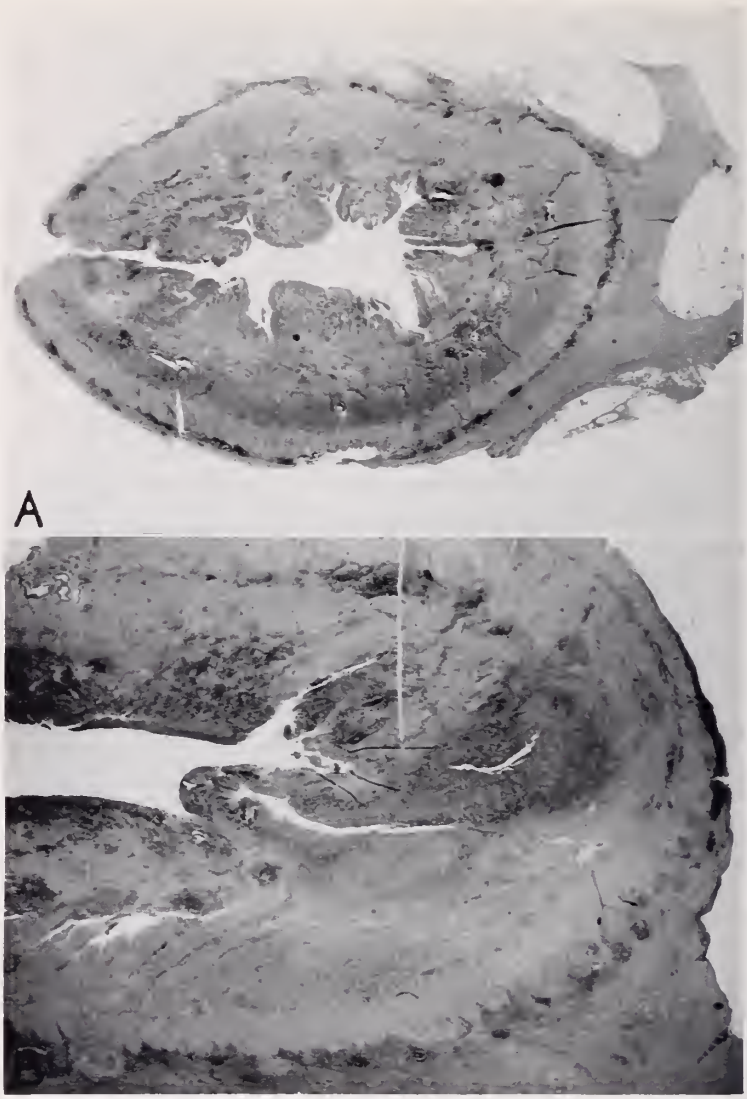

FIG. 5A, B. Cross section of ileum showing granulomatous lesions in submucosa, muscle layers, serosa and fat tissue around the intestine. Note abscess formation in submucosa 4(B).

lent foci are obviously responsible for the future development of fistulous tracts, which is so characteristic of this disease process. The submucosal inflammation with subsequent fistulous tract formation is not found in chronic non-specific ulcerative colitis.

REGIONAL JEJUNITIS

A granulomatous process, initially involving the segments of the jejunum is identical with that of the ileum, grossly and microscopically. However, in the

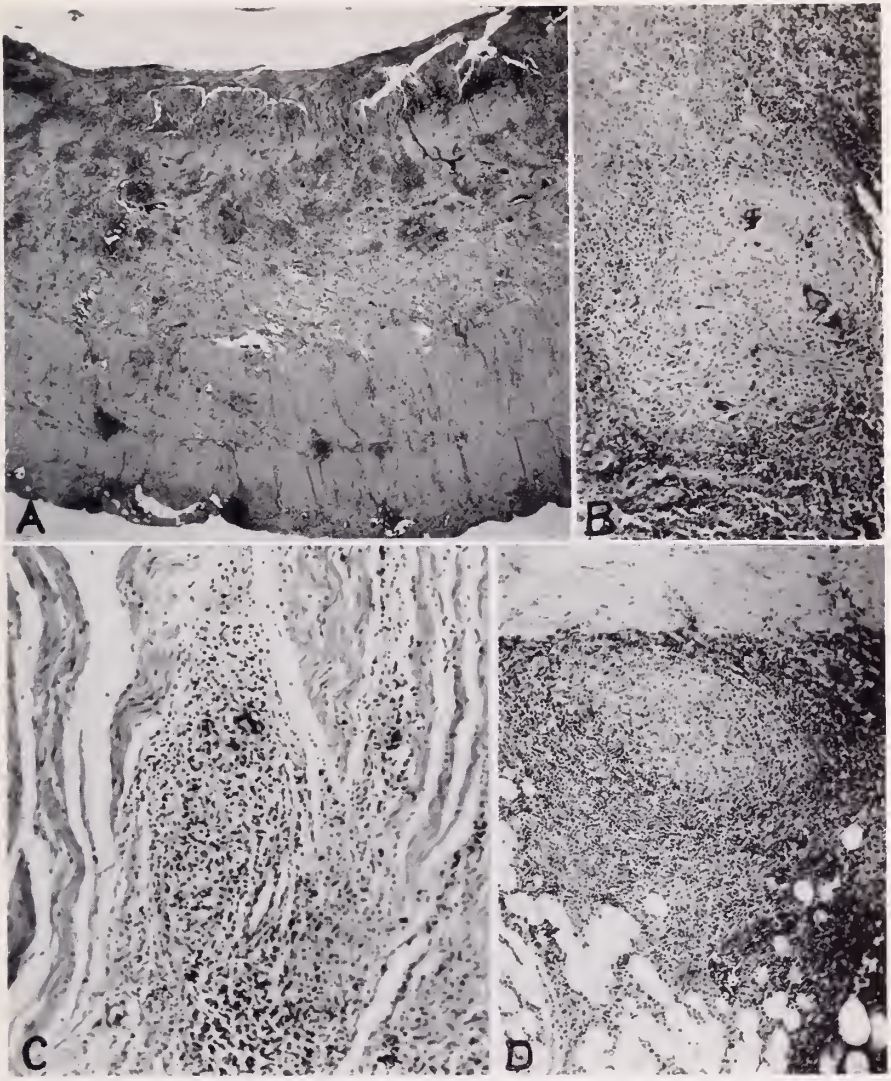

FIG. 6 A. Low power picture of granulomatous ileitis. The mucosa surface is covered by purulent exudate. Granulomatous lesions in submucosa (B), muscle layer (C) and serosa and fat tissue (D).

jejunum, the lesions appear as short, segmental thickenings of the intestinal wall almost resembling "skipped lesions". The portions of the jejunum between the two segmental lesions is often markedly distended and dumb-bell shaped, and its mucosa may show many shallow ulcerations (Fig. 4). The existence of short, segmental lesions in the jejunum may lead one to the erroneous conclusion that these lesions are part of extensive skipped lesions also involving the ileum. However, it is common to find a severe granulomatous jejunitis with only minimal involvement of the terminal ileum.

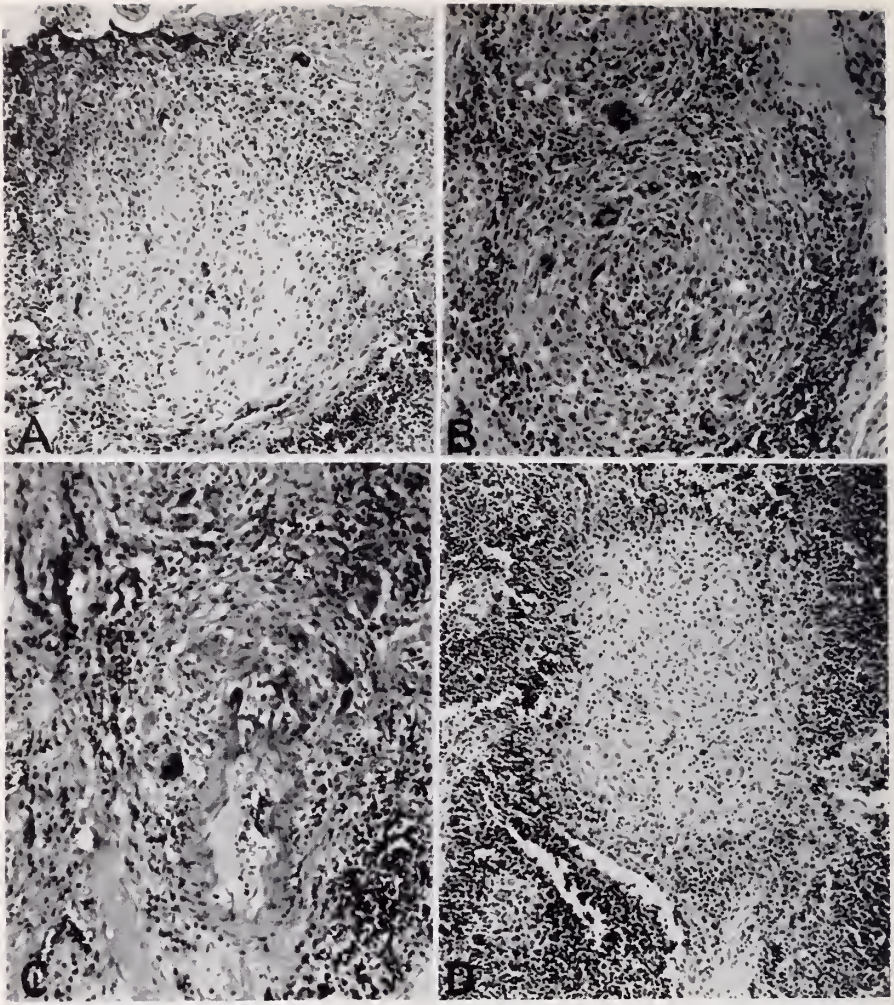

Fig. 7. Various granulomatous lesions found in mucosa (A), submucosa (B, C), and lymph node (D). A small artery involved by granulomatous process (C).

Since the original observations concerned a portion of the terminal ileum, the term "terminal ileitis" was at first used. In a broad sense, since the granulomatous lesions may involve both the ileum and the jejunum, it is logical to regard this condition as Regional Enteritis.*

REGIONAL ENTEROCOLITIS

If one examines a typical case of regional ileitis, one finds that the pathological lesion stops abruptly at the ileocecal valve. If one studies a typical case of chronic non-specific ulcerative colitis, one inevitably finds that the ulcerative lesion

* Clinical observations on an occurrence of regional duodenitis and gastritis have recently been described. However, the writer has had no chance to examine the actual specimens, except for small biopsy tissue fragments.

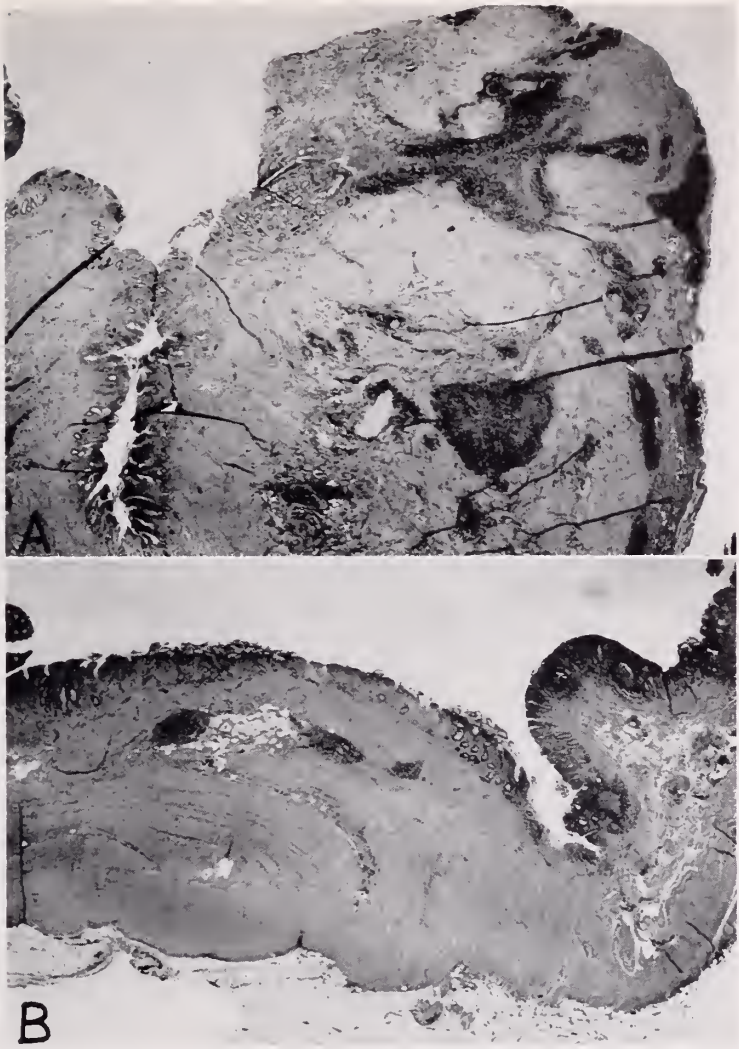

FIG. 8. An example of regional ileitis with coincidental association of ordinary ulcerative colitis (Group 1). A. Indicating granulomatous lesion of terminal portion of ileum. B. Portion of colon showing healing chronic non-specific ulcerative colitis with inflammatory polyp. No granulomatous lesions found in the colon.

stops abruptly at the ileocecal valve. These are the findings typical in each condition.

The slight involvement beyond the ileocecal valve which may occur in both conditions should be considered as a rather exceptional occurrence.

These two conditions (i.e. regional ileitis and ulcerative colitis) differ so much from each other anatomically as well as clinically that one suspects different etiological factors.

In recent years, however, an unusual combined form of regional ileitis and ulcerative colitis has been observed. This association, however, cannot be in-

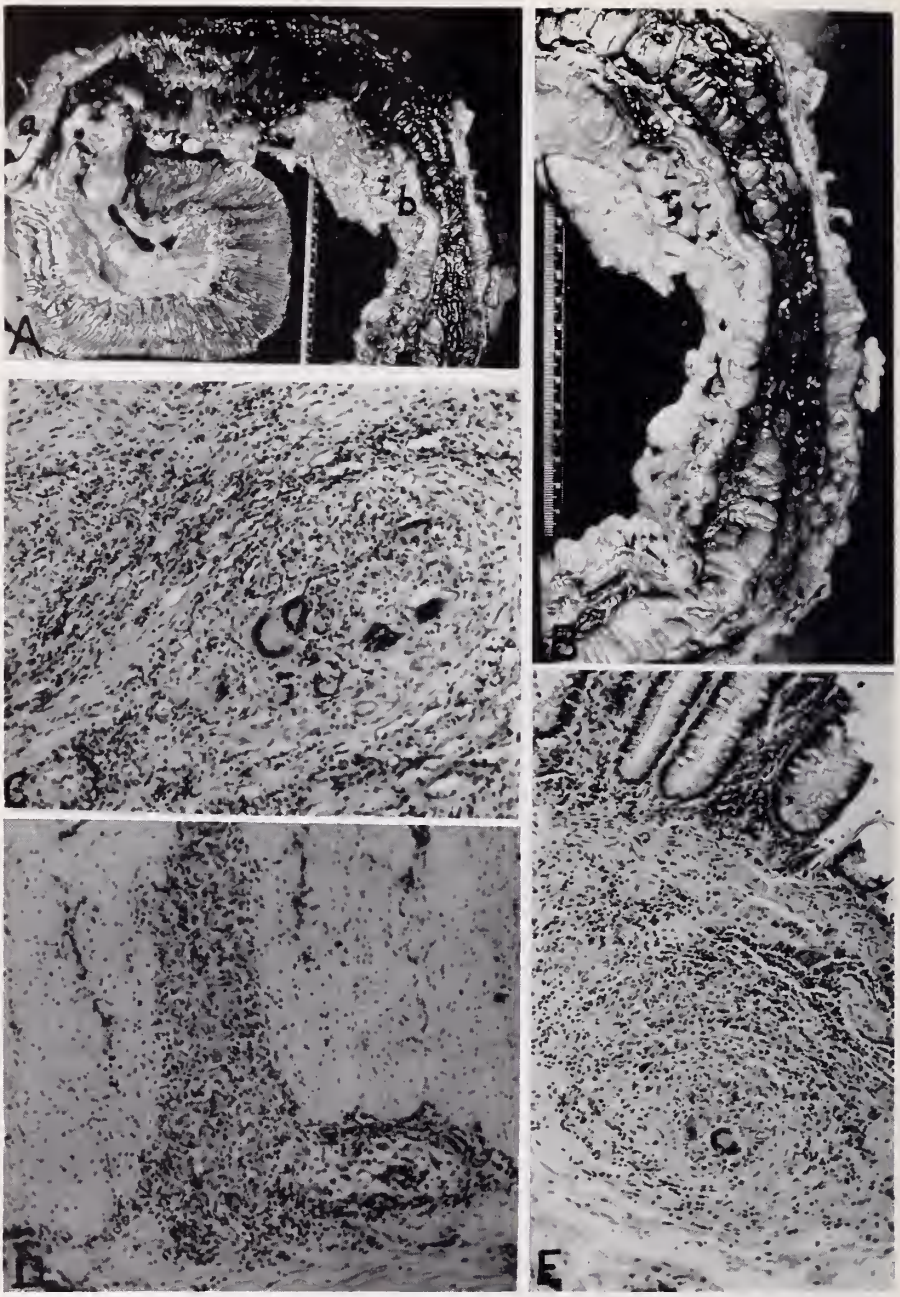

FIG. 9. An example of group 2. Regional ileitis and regional colitis. A. Granulomatous lesions with narrowed lumen of ileum (a) and colon (b). B. Narrowed portion of colon with linear ulcers. C. Granulomatous lesions found in submucosa of ileum. D and E. Showing colonic granulomatous lesions.

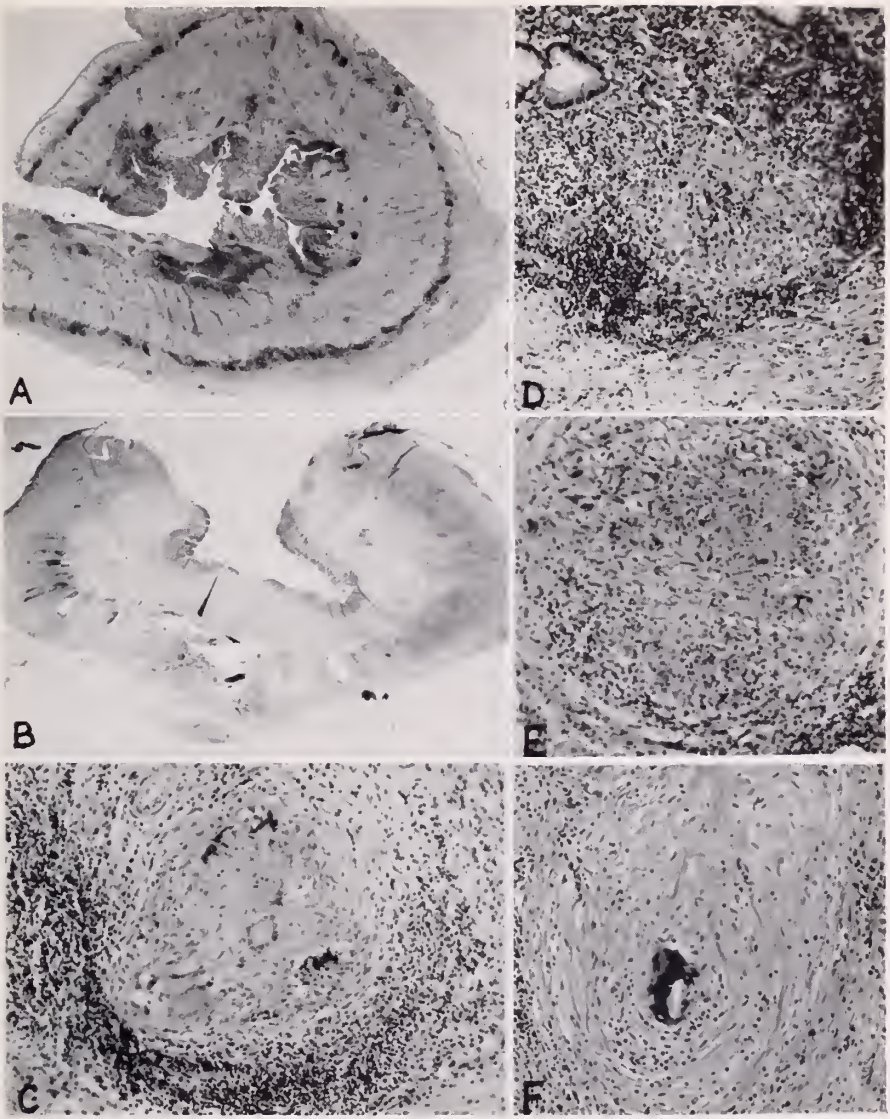

FIG. 10. An example of group 3 (regional entero-colitis following ileo-colic anastomosis. A. Granulomatous inflammation of ileum, which was anastomosed to colon. B. Granulomatous lesion of terminal ileum, previously bypassed. C. Granulomatous lesion of ileum. D, E, and F. Granulomatous lesions found in the diseased portion of colon.

terpreted as a single disease process, because there are various types of ulcerative colitis associated with a regional enteritis. Each case should be critically analyzed.

Group 1. Among the cases of enterocolitis, there are instances of granulomatous regional ileitis coincidentally associated with simple chronic ulcerative colitis. Figure 8 illustrates this combination of diseases. The terminal portion of ileum shows a typical granulomatous ileitis with a markedly narrowed lumen.

The colonic mucosa, however, presents an ordinary diffuse chronic ulcerative colitis with sporadic inflammatory polyps. No thickening of the colonic wall exists and there is no narrowing of the lumen of the colon. No granulomatous lesions have been found in the colonic wall, neither macroscopically, nor microscopically. In another words, the colonic ulcerative lesions are simply the usual lesions found in non-specific ulcerative colitis. A simultaneous existence of typical granulomatous regional ileitis in these cases should be interpreted as merely coincidental.

Group 2. The cases belonging to this group completely differ from the cases described above. The colonic lesion, which coexists with the granulomatous ileitis, is somewhat similar to the lesion found in the terminal portion of the ileum. A segmental thickening of the colonic wall with slight narrowing of the lumen is seen. However, the thickening of the large bowel wall and narrowing of the lumen may be said to be of a much lesser degree in comparison with that of the terminal ileum. The type of ulceration of the colonic mucosa differs from the ulcerations seen in an ordinary case of ulcerative colitis; they are not diffuse, but linear deep ulcerations scattered throughout the colonic mucosa (Fig. 9B).

More significant colonic lesions are found microscopically. In the ulcerated colonic wall, one finds many scattered epithelioid cell tubercle-like nodules with occasional giant cells. The location of the microscopic granulomas in the colonic wall is also identical with the location of the granulomas in the ileum. The nodules are found in the ulcerated submucosa, muscle layers and in the fibrotic serosa (Fig. 9C, D, and E). Some of the epithelioid cell nodules with giant cells strikingly resemble true tubercles. Many attempts to demonstrate acid-fast bacilli, however, have failed.

The lymph nodes removed from the pericolonic fat tissue also show identical microscopic epithelioid cell nodules as in the colonic wall.

Group 3. After longstanding ileotransversostomy in a case of regional ileitis, a localized, ulcerative colitis, particularly near the site of ileocolic anastomosis may develop. This may well be interpreted as a continuation of the granulomatous process of the ileum because the ileum close to the anastomosis is often diseased and shows granulomatous thickening of the wall. The ileal involvement may be either a recurrence or a skipped lesion. However, the colonic ulceration differs from the ordinary diffuse ulcerative colitis in that the colonic wall is thicker and deep linear ulcers can be seen. The colon in this type of case is similar to that described in the previous group.

The colonic ulcerative lesions described in groups 2 and 3, differ strikingly from those lesions in ordinary ulcerative colitis, particularly since miliary granulomatous nodules are found microscopically in these two groups. The existence of segmental thickening of the colonic wall is also unique, and not observed in the ordinary case of ulcerative colitis.

Since the pathological picture of the colonic lesions is so identical with that of regional enteritis, it is logical to assume that the simultaneous association of regional ileitis and colitis (particularly groups 2 and 3) should not be interpreted as a mere coincidence, since they may have a common etiological factor. It is justifiable to term groups 2 and 3 Regional Enterocolitis.

THE SYNDROME OF COMBINED ILEOCOLITIS

HARRY YARNIS, M.D.

New York, N. Y.

Ileocolitis is a term that has been loosely applied to several forms of inflammatory disease affecting the terminal ileum and the proximal colon simultaneously. Before 1932 most of these cases were considered to be of tuberculous origin. Universal ulcerative colitis has been known to involve the terminal ileum in about 24 per cent of cases. The inflammatory process in the ileum, superficial and exudative in character is due to "backwash" of the infected colonic contents through an incompetent ileocecal valve.

In 1930 Bargen and Weber (1) described the right-sided type of ulcerative colitis localized to the proximal colon. Subsequently many case reports and articles have been published describing ulcerative colitis localized to various segments of the colon excepting the rectum and sigmoid. Usually in the proximal type of colitis the extension of the lesion is towards the rectum; however involvement of the terminal ileum secondary to the colonic lesion occurs frequently. Crohn, Garlock and Yarnis (2) reported 77 cases of right-sided colitis in which 40 per cent showed involvement of the terminal ileum, with a superficial ulcerative process that started in the mucosa and was exudative in nature. There was no evidence of granulomatous or productive change, such as characterizes typical regional ileitis.

When "terminal ileitis" was originally described in 1932 as granulomatous in nature, it was postulated that the disease was limited by the ileocecal valve and did not extend aborally. Only two years later Colp (3) described a case of non-specific granuloma of the terminal ileum and cecum which he resected. In 1936 Crohn and Rosenak (4) reported a series of 60 cases of ileitis in which nine (15 per cent) involved the colon. Rappaport, Burgoyne and Smetana (5) in 1951 reported a series of one hundred cases of regional ileitis in which the pathologic process extended into the colon in 55 instances. In many of these cases the granulomatous process involving the colon could only be detected microscopically, the cecum and ascending colon appearing normal on gross examination. In the author's experience, granulomatous involvement of the colon, secondary to ileitis is rare and is usually a result of fistulous tracts originating in the diseased ileum.

The term combined ileocolitis is used in this paper to denote the presence of granulomatous ileitis and non-specific ulcerative colitis, two separate and distinct pathological processes. As stated by Warren and Sommers (6) these two conditions are morphologically different; regional ileitis is a sclerosing granulomatous lymphangitis involving the entire wall of the intestine and producing a thick, rigid tube; ulcerative colitis is an exudative inflammatory process restricted chiefly to the mucosa and submucosa. In their experience the combination of ileitis and ulcerative colitis is rare.

Neuman and Dockerty (7) reported on findings in 25 resected specimens of

From the Department of Medicine, The Mount Sinai Hospital, New York, N. Y.

regional colitis in which there was a non-specific "granulomatous" process producing a consistent thickening of the entire wall to almost twice its normal size. Wells (8) also described segmental colitis which he believes to be a colonic type of granulomatous ileitis and describes in the colon the typical granulomatous microscopic appearance with giant cells and epithelioid tubercle formation. In the authors' experience, granulomatous involvement of the colon is rare and resected specimens of right-sided or segmental colitis have almost always been reported as ulcerative colitis. In several instances the pathologist reported fibrosing or cicatrizing colitis which is probably similar to the cases described above.

Recently Brooke and Cooke (9) described a form of ileocolitis which they believe starts with steatorrhea due to small bowel dysfunction and poor fat absorption. According to them this produces shallow ulcerations in the ileum, and this superficial ulcerative process spreads through the ileocecal valve to gradually involve the proximal and distal colon. The progressive nature of this disease precludes surgical intervention where resection is inevitably followed by diffuse recurrence resulting in inanition.

The clinical and pathological entities of regional ileitis and of non-specific ulcerative colitis are well known and discrete. Much confusion in the literature exists concerning the incidence of granulomatous formation in segmental or regional colitis. Likewise, there is no universal agreement on the pathological picture of ileocolitis. The term combined ileocolitis should be used to denote two different and distinct pathological processes, namely granulomatous ileitis and ulcerative colitis. The 54 cases of combined ileocolitis reviewed in this paper are taken from office files and have been collected over a twenty five year period. Included are 654 cases of ileitis, 1520 cases of universal ulcerative colitis and 109 cases of segmental colitis. The disproportionate number of ileitis cases (29 per cent) as compared to the other two groups does not represent the true incidence of the two diseases, and recognizes a special interest in the study of the life history of regional ileitis. In 1949 the present series contained 306 cases of ileitis with only 22 cases of combined ileocolitis accumulated over a 17 year period. Now, only 6 years later there are 654 cases of ileitis and 54 cases of combined ileocolitis; well over double the original figure.

In 38 instances both of these diseases were present when the patient was first seen; the combined ileocolitis was therefore "synchronous" or simultaneous at the very onset. In 16 cases either ileitis or ulcerative colitis was originally present, but after surgical intervention for the cure of the original disease, the second disease developed. One, therefore, may call this group combined ileocolitis "metachronous" in nature signifying that the combined diseases succeeded or followed each other.

Even though ileitis and non-specific colitis present different pathological features, they appear to be related diseases causing similar symptoms and having the same age distribution. In this series there were 23 females and 31 males. The onset of the symptoms is most frequent in the second decade, and two cases developed at the age of 9 years. However, one case was present in a man 70 years of age (Table 1).

TABLE 1

Combined ileocolitis—sex and age incidence

Females—23; Males—31

Age at Onset	Number of Cases
Years	
1–10	2
10–20	24
20–30	16
30–40	8
40–50	3
60–70	1
Total	54

The anatomical distribution of combined ileocolitis presents almost all combinations of the various segments of the small and large intestine. An exact classification is impossible but for practical purposes the 38 cases of "synchronous" ileocolitis are divided into the following anatomic groups as depicted in Figure 1:

A. Terminal ileum and ascending colon	16 cases
B. Terminal ileum and transverse colon	2 cases
C. Terminal ileum and distal colon	5 cases
D. Terminal ileum and entire colon to sigmoid	10 cases
E. Ileum, jejunum and entire colon to sigmoid	5 cases
	38 cases

The 16 cases of "metachronous" ileocolitis are divided into two groups (Figure 2). In 12 cases the primary disease was in the terminal ileum and after an ileotransversostomy had been performed for the cure of the original disease, ulcerative colitis developed. In four instances, the primary disease was ulcerative colitis involving the entire proximal colon, excepting the rectum and sigmoid. After subtotal colectomy and ileosigmoidostomy had been performed, granulomatous ileitis developed within two to five years after the resection.

Ileitis or jejunitis also occurs after total colectomy and ileostomy for universal ulcerative colitis. Granulomatous jejunitis occurred once and ileitis four times after colectomy in this series. Lyons and Garlock (10) reported this complication in six cases.

CLINICAL FEATURES

The clinical picture of combined ileocolitis presents the symptoms common to both diseases but in a more severe form. Fever is present during the active stages of the disease and usually ranges between 101° and 102° F., and may reach as high as 105° F. in some cases with high toxicity. Leukocytosis with polynucleosis corresponds to the fever and ranges from 12,000 to 15,000 per cu. mm. and in

FIGURE I

"SYNCHRONOUS" COMBINED ILEITIS AND COLITIS (38 CASES)
ANATOMICAL DISTRIBUTION

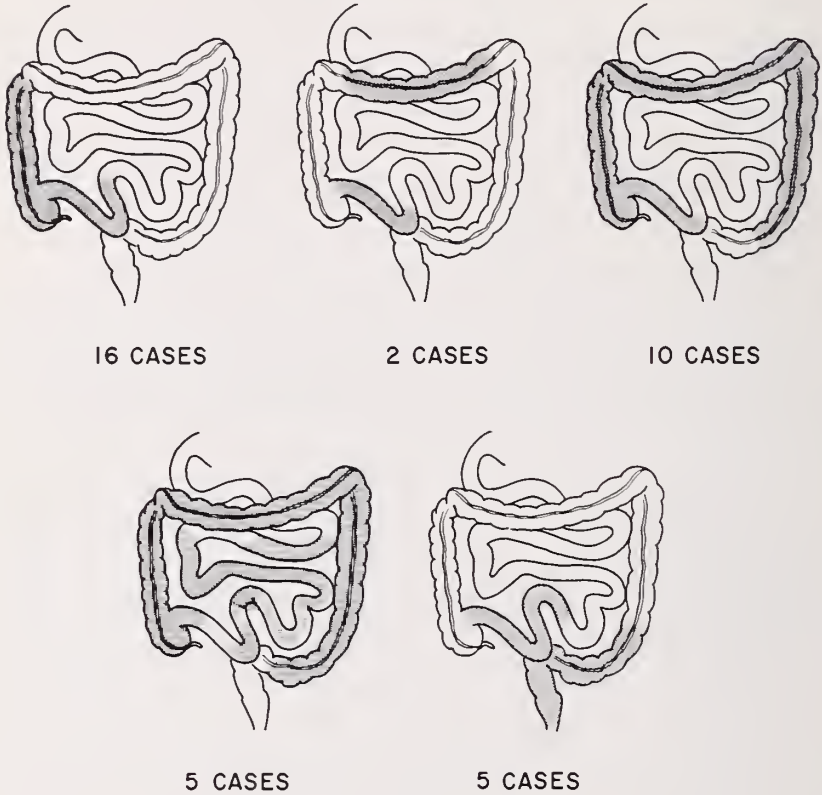

Fig. 1

exceptional cases reaches 20,000 per cu. mm. The sedimentation time also rises during the acute phases but usually remains elevated during the afebrile periods, until the inflammatory process completely subsides. Cramps and bloody diarrhea are uniformly present but in three cases persistent constipation was noted. Massive intestinal hemorrhage was present in seven cases and melena was noted in two instances. Anorexia and weight loss are marked during the recurrences, and in extreme cases severe malnutrition with losses of fifty pounds may occur. Intestinal obstruction with abdominal distention and fluid levels in the small intestinal loops occurs infrequently but usually subsides after intestinal intubation. Secondary anemia is consistently present with hemoglobin values between 9 and 10 grams. Frequently the hemoglobin dropped below 8 grams. Hypoproteinemia is usually mild with blood protein values averaging 6.1 grams. Nutrional edema is rarely observed. Hypocalcemia and tetany were observed in only one case. Arthritis was present in 14 instances and usually involved the large joints,

FIGURE 2

"METACHRONOUS" COMBINED ILEITIS AND COLITIS (16 CASES)
ANATOMICAL DISTRIBUTION

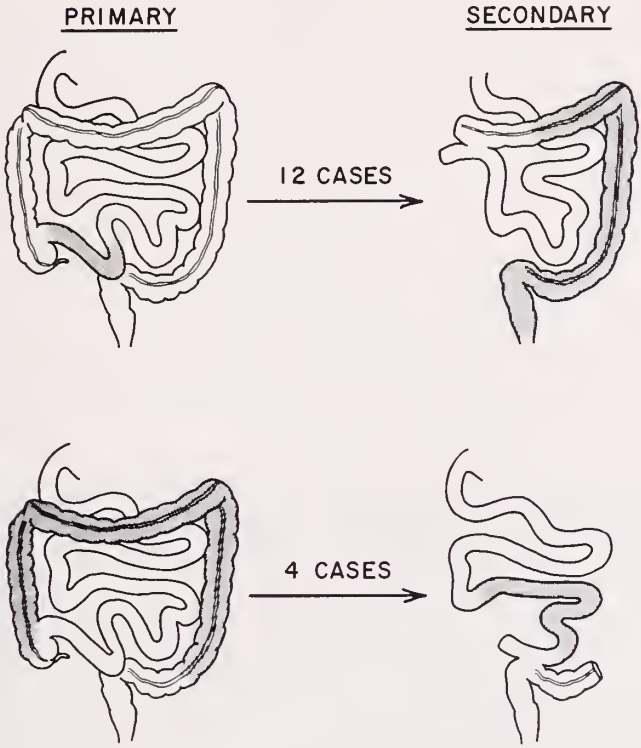

Fig. 2

causing severe disability in two cases. An associated duodenal ulcer was present in five patients.

An abdominal mass was palpable usually in the right lower quadrant in 22 cases. Splenomegaly was noted in two instances and clubbing of the fingers was present in four cases. Erythema nodosum in the lower extremities occurred four times and stomatitis with ulcerative pharyngitis twice. Phlyctenular conjunctivitis was noted once.

Internal fistulae, originating in the terminal ileum and extending to the cecum and other parts of the colon existed in four cases and in one instance a jejuno-ileal fistula occurred. External fecal fistulae, opening on the anterior abdominal wall, complicated six cases. Four of these fecal fistulae originated in the sigmoid and were the result of a perisigmoidal abscess secondary to a perforated ulcerative colitis; two fistulae began in the terminal ileum.

Rectal complications were frequent; perirectal abscesses and fistulae occurred in 20 cases; four of the latter were associated with rectovaginal fistulae and in one male there was a deep recto-urethral fistulous tract.

MEDICAL THERAPY

The basis of medical therapy as in ileitis and colitis consists of supportive measures including bedrest, low residue diet, injections of vitamins, crude liver extract and multiple transfusions whenever necessary. Insoluble sulfonamides and antibiotics such as tetracycline and dihydrostreptomycin are used to combat infection. Penicillin is of no value for the treatment of this disease and its complications. Steroid therapy is of definite value and is most effective in the form of ACTH parenterally. One patient with diffuse disease of the small and large intestine, has made a remarkable recovery gaining 30 pounds and is restored to normal working efficiency. However, he must continue to take a maintenance dose of 10 units of ACTHar gel daily. A second patient, 70 years of age, with high temperature, marked toxicity and large nodules of erythema nodosum became asymptomatic after six injections of ACTH. The oral use of cortisone, hydrocortone and meticorten has been disappointing because of the uncertain absorption.

Of 16 cases that were treated medically, one is cured, two are well, four are improved. Seven continue to have frequent recurrences and are in a chronic state of malnutrition. There was no follow-up in two cases. The case that was cured had involvement of the terminal ileum and transverse colon and responded dramatically to non-specific protein shock therapy using typhoid vaccine. Four years later barium enema X-rays revealed a normal mucous membrane throughout the entire colon and only a slight distortion in the terminal ileum. Now, eighteen years since the onset the man is perfectly well.

SURGICAL ASPECTS

The surgical management of ileocolitis depends upon the extent and distribution of the disease in the small and large intestine. In general, surgical intervention is indicated if pathology is localized to the distal ileum and proximal colon, and there has been no response to medical therapy. However, in several instances extensive resections of the colon and the small intestine have been performed because of massive hemorrhage or progression of the disease. Local, palliative resection of stenosing granulomatous skip areas in the small intestine are frequently necessary due to obstruction, even when diffuse disease exists. Of this series 38 cases were treated surgically and multiple operations were performed in most instances.

"SYNCHRONOUS" ILEOCOLITIS

There were 22 cases of "synchronous" ileocolitis; in 11 of these cases, the disease was limited to the terminal ileum and ascending colon. Ileocolic resection was performed in eight and a short circuiting procedure in the other three. Results were good in four cases, poor in six, due to recurrent disease and one patient died after a secondary resection.

Of the remaining 11 cases, one had an ileosigmoidostomy with transsection of the ileum for terminal ileitis and transverse colitis; he is well and weighs 190 pounds. Two cases with terminal ileitis and proctitis had an ileotransversostomy performed; both had upward extension of the colitis with perianal abscesses and a rectovaginal fistula necessitating ileostomy.

In six cases, ileocolic resection and ileosigmoidostomy were performed for right-sided colitis and terminal ileitis. Four of these patients required ileostomy after the disease extended into the rectum. One is in poor condition with recurrent disease in the ileum producing abdominal masses and the last case is improved.

Two cases presented diffuse ileojejunitis and ulcerative colitis involving the entire colon excepting the rectum. One is a fifteen year old boy in whom ileosigmoidostomy and colectomy were performed. He continues in poor nutrition with acute exacerbations of fever and arthritis. The second case has been observed for 16 years and presents the life history of ileojejunitis and right-sided colitis with its gradual progression to involve the entire colon. The symptoms and the sequence in this last case may be tabulated as follows:

Case A. S., male—38 years of age (1955).

1—18 years ago: terminal ileitis and proximal colitis (Figure 3).

2—16 years ago: resection of 24 inches of terminal ileum and the right colon to hepatic flexure. Diffuse ileojejunitis noted at time of exploration. The pathological specimen indicated colitis with pseudopolyps and true granulomatous ileitis with fistulae (Figure 4).

FIG. 3. Case A. S. Terminal ileitis and proximal colitis demonstrating multiple internal fistulae.

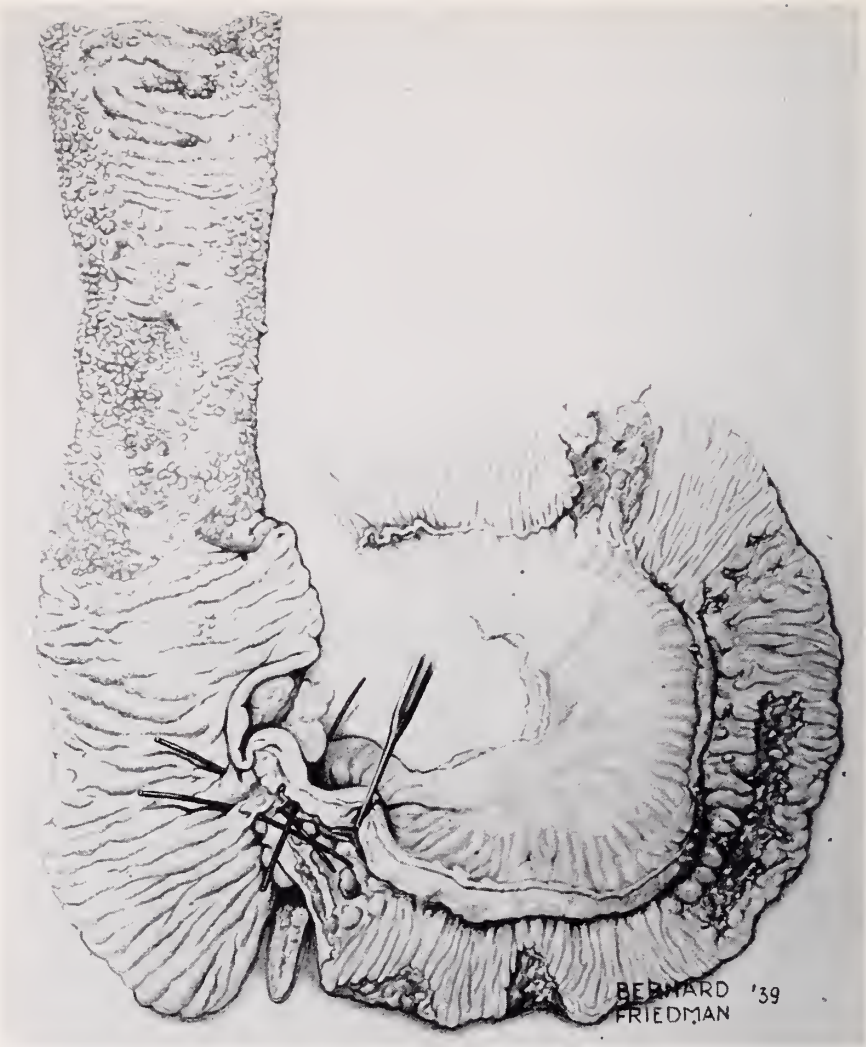

Fig. 4. Case A. S. (See also fig. 3.) Pathological specimen: granulomatous ileitis with fistulae and ulcerative colitis with pseudo-polyposis.

3—14 years ago: resection of residual colon for ulcerative colitis with ileosigmoidostomy. At exploration healing of jejunitis was noted but with persistence of skip lesions in ileum; sigmoid and rectum were normal.

4—6 years ago: resection of 24 inches of lower ileum with three stenotic areas which caused intestinal obstruction. Sigmoidoscopy was normal.

5—3 years ago: onset of proctitis with rectal ulcerations followed by development of pseudo-polyps.

6—1 year ago: ileostomy performed because of severe rectal infection. Ileostomy seven feet from ligament of Treitz. Serum electrolytes and hemoglobin at normal levels without parenteral supplements. Weight constant.

"METACHRONOUS" ILEOCOLITIS

There were 16 cases of "metachronous" ileocolitis. 12 of these began initially with terminal ileitis and developed ulcerative colitis after an ileotransversostomy with or without ileocolic resection. In one case the secondary colitis was restricted to the transverse colon and after a further resection he is well. Another patient after a short circuiting operation for terminal ileitis, developed diffuse ulcerative colitis but has been in a continuous remission for the past two years. In two other patients ileocolic resection was performed for ileitis, and the results are only fair due to a mild but persisting ulcerative colitis, and in one instance death followed a gas bacillus infection; one case was lost to follow-up. Of the remaining six patients whose disease began as terminal ileitis originally, the subsequent ulcerative colitis has been severe, eventually requiring ileostomy in three instances. One of the latter cases is another example of the complicated sequence of events which may follow each other, even though the initial disease was a true terminal ileitis:

Case R. W., male, 42 years of age (1955).

1—Thirteen and a half years ago: terminal ileitis diagnosed at exploratory operation.

2—Thirteen years ago: temporary enterostomy for intestinal obstruction, shortly followed by ileotransversostomy with exclusion of four feet of diseased terminal ileum; colon normal.

3—Twelve and a half years ago: recurrent granulomatous ileitis, followed by resection of ileotransversostomy and four feet of ileum proximal to anastomosis with new ileotransversostomy.

4—Twelve years ago: resection of ascending colon and four feet of previously excluded terminal ileum. Active ileitis still present in the isolated terminal ileum which was the original site of disease. Intraperitoneal abscess present between sigmoid and terminal ileum. Remission with subsequent improvement for seven years.

5—Four years ago: recurrence of chills, fever and increased diarrhea.

6—Three years ago: intermittent intestinal obstruction requiring intubation. Barium enema showed an ileosigmoid fistula with narrowing of ileum and evidence of sigmoiditis. Proctoscopy revealed the rectal mucosa to be normal.

7—Two years ago: persistent fever, progressive weight loss and secondary anemia despite ACTH and supportive measures. Barium enema showed ulcerative colitis involving sigmoid and lower descending colon, but proctoscopy revealed normal rectal mucosa.

8—Six months ago: ileostomy and resection of entire distal colon to rectum for severe advanced ulcerative colitis causing massive hemorrhage. Despite profuse drainage from ileostomy, serum electrolytes and hemoglobin are now normal and weight is stabilized at 130 pounds.

The other four cases of "metachronous" ileocolitis began with a segmental or right-sided ulcerative colitis for which subtotal colectomy and ileosigmoidostomy were performed. The resected terminal ileum in two instances was normal and in the two other cases presented superficial mucosal ulcerations typical of "backwash" ileitis. Granulomatous ileitis developed in all four cases in the "new terminal ileum" proximal to the site of anastomosis within two to five years after the original resection. Two of these cases required ileostomy subsequently due to rectal complications and are in excellent nutrition. The third case de-

veloped a mild proctitis and an active duodenal ulcer. The fourth case is presented briefly below and is significant because granulomatous ileitis recurred twice after resection for right-sided colitis and yet the sigmoid and rectum remained normal.

Case T. K., female, 28 years of age (1955).

1—Ten years ago: subtotal colectomy and ileosigmoidostomy for right-sided colitis with fecal fistula to the abdominal wall. Resected terminal ileum normal. Dramatic recovery, and well for five years.

2—Five years ago: recurrence of fever and diarrhea. Barium enema revealed typical granulomatous ileitis proximal to ileosigmoidostomy. Rectum and sigmoid still normal.

3—Four years ago: resection of 46 cms. of "new" terminal ileum following complete obstruction due to apricot pit embedded in a stenotic area at the anastomosis. The pathology was reported as granulomatous ileitis with fistula formation.

4—Three years ago: intestinal obstruction due to adhesions obstructing the lower ileum. Ileum and sigmoid were normal at operation.

5—Two years ago: normal delivery of a full term infant.

6—Seven months ago: recurrence of fever and diarrhea during the eighth month of second pregnancy.

7—Six months ago: acute ileitis seen during the Cesarian section following a full term pregnancy.

PROGNOSIS AND RESULTS

As expected, the prognosis in the combination of these two severe diseases is poor. Of the 16 cases treated medically, three are well, four are improved and seven are poor. Two were lost to follow-up. Of the 38 surgical cases only nine can be considered good; six are improved; 18 are poor, two died and three cases are lost to follow-up. Eleven of the surgical cases eventually required ileostomy. The poor results cited above may be attributed to the fact that usually the most complicated and unsuccessfully treated cases are referred to this office. Undoubtedly there are many instances of combined ileocolitis cases that were treated with favorable results.

What can we learn from the experience of the last twenty five years? In the early days, operative treatment was suggested as soon as the diagnosis of granulomatous ileitis and colitis was made, especially when the rectum and sigmoid were not involved. Now, from experience with the treatment of the combined ileitis and colitis, it is apparent that conservative treatment should always be tried initially, where there are no urgent surgical indications such as massive hemorrhage, intestinal obstruction or persistent fistulae.

The best surgical results are obtained when the patient has been observed for long periods of time, and the course of the disease is followed with serial radiographic studies. When the disease in the small and large intestines has become localized and definitely delimited the recurrences are less. Surgical intervention during the acute phases with marked inflammatory reaction is almost always followed by recurrent disease, because the surgeon is unable to define the limits of the involved segments. However, in cases of diffuse disease with gradual progression and a downhill clinical course, operative interference may be necessary as a

life saving measure. With the newer surgical techniques, use of wide spectrum antibiotics and multiple transfusions, even the most extensive resections are now possible with satisfactory results.

REFERENCES

1. Bargen, J. A., and Weber, H. M.: Regional Migratory Chronic Ulcerative Colitis. Surg., Gynec. & Obst., 50: 964, 1930.
2. Crohn, B. B., Garlock, J. H., and Yarnis, H.: Right-sided (Regional) Colitis. J.A.-M.A., 134: 334, 1947.
3. Colp, R.: A Case of Non-specific Granuloma of the Terminal Ileum and the Cecum. S. Clin. North America, 14: 443, 1934.
4. Crohn, B. B., and Rosenak, B. D.: A Combined form of Ileitis and Colitis. J.A.M.A., 154: 189, 1954.
5. Rappaport, H., Burgoyne, F. H., Smetana, H. F.: The Pathology of Regional Enteritis. Mil. Surgeon, 109: 463, 1951.
6. Warren, S., and Sommers, S. C.: Pathology of Regional Ileitis and Ulcerative Colitis. J.A.M.A., 154: 189, 1954.
7. Neuman, H. W., and Dockerty, M. B.: S.G.O. 99: 512, 1954.
8. Wells, C.: Ulcerative Colitis and Crohn's Disease. Ann. Roy. Col. Surg. Eng., 11: 105, 1952.
9. Brooke, B. N., and Cooke, W. T.: Ulcerative Colitis: Diagnostic Problem and Therapeutic Warning. Lancet, 2: 462, 1951.
10. Lyons, A. S., and Garlock, J. H.: The Complications of Ileostomy. Surgery, 36: 784, 1954.

THE EXTRA-INTESTINAL MANIFESTATIONS OF REGIONAL ILEITIS: SOME COMPARISONS WITH CHRONIC ULCERATIVE COLITIS

ALBERT CORNELL, M.D.

New York, N. Y.

Regional ileitis, like ulcerative colitis, may manifest itself by extra-intestinal signs and symptoms. These may appear before or after the intestinal lesion itself has been discovered. Although some of the extra-enteric manifestations of regional enteritis may occur uncommonly, knowledge of their existence may lead to the correct diagnosis whenever the true nature of the underlying condition is obscure.

GENERAL CONSTITUTIONAL EFFECTS

Fever. As is well known, ileitis is usually characterized by low grade, irregular fever but it also may be associated with high temperatures. Many cases of fever of unknown origin have been discovered to be caused by ileitis. For example, there have been cases of rheumatic fever, brucellosis, subacute bacterial endocarditis and lupus erythematosis which were ultimately correctly diagnosed regional ileitis. Chills rarely accompany the fever but there may be associated toxemia. Fever was observed in 69 cases of the 222 cases in Crohn's series (1).

Nutritional effects. The loss of weight and strength, the marked wasting, cachexia and avitaminoses that accompany the fever, diarrhea and toxemia are all well known, e.g. pellagra and scurvy. These deficiency states vary in severity and occur in association with the initial disease or with recurrent ileitis as well as after a partial or complete exclusion of the ileitis. According to Van Patter, et al (2) they result from a number of factors (2):

(a) Gradual decrease in food intake due to anorexia or fear of colicky pain.
(b) Hyperperistalsis.
(c) Self-restriction of diet to liquids only.
(d) Reduction in absorptive surface of bowel.
(e) Continual loss of blood and plasma (this may reach very large amounts as in ulcerative colitis).

The uninvolved bowel is unable to maintain nutrition by:

(f) Alteration of physiological function as a result of intestinal obstruction.
(g) Presence of insufficient bowel after previous resection.
(h) Inability to perform proper absorption.

It is notable in the Mayo Clinic series by Van Patter, et al (2) that the deficiency states were usually explained by recurrent disease except for a few exceptions. In only an occasional patient with regional ileitis will a nutritional deficiency constitute the outstanding clinical feature.

Changes in Growth and Development. As a result of malnutrition and its serious

From the Gastro-Intestinal Clinic, The Mount Sinai Hospital, New York City.

side effects, there may occur failure to develop proper sexual maturity. Infantilism may appear not uncommonly especially since many cases of ileitis occur in the younger age group, i.e. pre-puberty. In the majority of cases, however, the retardation of growth is usually mild in nature. Marked retardation of growth along with delayed maturation of secondary sex characteristics is rarely seen. After the ileitis has been controlled surgically, these abnormalities usually disappear.

Other Endocrine Changes. Apparently, ileitis causes little disturbance in endocrine function in females. Thus, menstruation is unaffected even in severe cases. By comparison, amenorrhea occurs quite often with ulcerative colitis as a manifestation of the severe, toxic phase of the disease. The return of menstruation may be a sign of abating disease and an improved prognosis. Fertility, of course, is not affected by regional ileitis.

Anemia. This usually is of the *microcytic, hypochromic type.* The bone marrow is hyperplastic in response to blood loss from the intestinal lesion.

Macrocytic, hyperchromic type of anemia with megaloblastic bone marrow is due to defective absorption and poor utilization of hematopoietic factors.

The presence of chronic inflammatory disease also contributes to the anemia. In the series reported by Van Patter (2), the anemia was most marked in the early, rather than in the late stages. Values for hemoglobin as low as 5 grams per 100 cc. of blood are not uncommon. In one case, the red blood count dropped to 750,000 per cu. m.m. but, following resection, the blood count returned to normal. Aplastic bone marrow was not encountered in that series.

Crohn states that the anemia in regional ileitis is moderate, often progressive. Values of hemoglobin may average between 60 to 70 per cent but lower values are not unusual even in the absence of gross intestinal hemorrhage. He quotes one case in which the hemoglobin dropped to 32 per cent without melena.

Chemical Changes. **Tetany,** although it is an uncommon complication, is more apt to occur in diffuse cases of regional enteritis involving the upper jejunum and ileum. Crohn cites one case with typical carpopedal spasm which was seen after two resections for recurrent ileitis. Another patient developed typical tetanic convulsions with a blood calcium of 3.4 mg. per cent. **Amyloidosis** too, is a rare complication of regional enteritis. The first reported case of amyloidosis in association with uncomplicated regional enteritis was described by Cohen and Fishman in 1949 (3). The authors were unable to discover any specific initiating or precipitating factor for the amyloidosis other than the regional enteritis. Olsan and Sussman have had two other cases of amyloidosis secondary to ileitis or associated with it (4). Systemic amyloidosis secondary to ileitis is extremely rare. It is of interest that amyloidosis does not occur often in spite of the chronicity and long extent of the disease.

OTHER CHANGES AFFECTING VARIOUS ORGANS—WITH LOCALIZING EFFECTS

Arthritis. In the 600 cases of regional ileitis studied by Van Patter (2), polyarthritis of the rheumatoid type was observed in 27 (4.5 per cent) of the cases and involved particular extremities and their small joints. The spinal column was

occasionally involved and although the joints were painful, the process did not result in the incapacitation of any patient. When the intestinal disease is controlled, the arthritis usually disappears. Thus, the degree of severity of the arthritis may reflect the activity of the ileitis. Exacerbation of joint symptoms after resection "invariably heralded recurrence of the intestinal lesion," according to the above authors.

Skin Lesions. **Erythema Nodosum.** This was seen initially in five of 600 cases of regional ileitis (2). Its presence also reflects the degree of activity of the intestinal disease. Erythema nodosum accompanied recurrence of the ileitis following resection in two cases. **Pyoderma Gangrenosum.** Although this is a well-known complication of ulcerative colitis it was seen in only one case in he study made by Van Patter.

Gastric Secretory Changes (1). Gastric acidity is usually unaffected in regional ileitis. At times, the curve of secretion may be low. Achylia gastrica is extremely rare.

Eye Changes. Thus far, we have been unable to find any cases with eye changes, in regional ileitis in contrast to chronic ulcerative colitis, where eye changes are not infrequent.

Clubbing. This may occur in ileitis on occasion just as it does in ulcerative colitis and may subside when the underlying disease process subsides.

Pylephlebitis and Multiple Liver Abscesses. These are rarely seen both in regional ileitis and chronic ulcerative colitis. In a study of 1,000 cases of chronic colitis, Bargen (5) encountered only four cases of liver abscess and two cases of phlebitis. These are striking observations when one considers the blood and drainage supply of the intestinal tract.

COMPARISON WITH ULCERATIVE COLITIS

Thus far, to my knowledge, a greater variety and number of extra-enteric manifestations have been reported in ulcerative colitis than in regional enteritis. In this connection, it is interesting to note Bockus' statement that the "clinical mimicry of ulcerative colitis by regional enteritis is common" (6). Since both disease entities have underlying inflammatory disease processes, we should expect similar complications in both. However, eye complications, such as iritis, uveitis, conjunctivitis, and corneal ulceration are apt to occur during the course of chronic ulcerative colitis (7) but I have failed thus far to find any reports of eye complications in regional ileitis.

These facts are of great interest since both diseases are associated with inflammatory processes, frequently run protracted courses and are characterized by systemic manifestations, often with widespread and important pathologic changes in other parts of the body. It may be that these changes in the eye and other organs occur but have not been singled out for mention in the literature as some may be part of a general nutritional or vitamin deficiency. It may be that as further studies of more cases of ileitis are carried out, these and other complications to be described will come to light in greater number. The same could apply to the liver, pancreas and kidney, there being quite an extensive literature on

changes in these organs reported in chronic ulcerative colitis but not in regional ileitis. Fatty infiltration of the liver, cirrhosis of the liver, hepatic insufficiency, hepatic thrombosis, pylephlebitis and liver abscesses are among the changes noted in ulcerative colitis (8–16). In the pancreas, gross atrophy, interstitial or acute edematous pancreatitis, fibrosis and acinar dilatation have all been found in chronic ulcerative colitis (17–20). Fatty infiltration of the liver is commonly associated with pancreatic disease in ulcerative colitis. Again, none of these changes have been reported in chronic ileitis, to my knowledge. In the genito-urinary tract, the following conditions have been noted in chronic ulcerative colitis; nephrosis, pyelitis, cystitis, nephrolithiasis, glomerulitis, tubular necrosis, degeneration and calcium deposition, acute pyelonephritis (21–24).

The renal changes noted in chronic ulcerative colitis apparently have not been observed thus far in regional ileitis.

Amyloidosis usually occurs in patients with ulcerative colitis who have very marked perirectal infections and deep pelvic abscesses (25). The association with ulcerative colitis, however, is rare (26) with the first case probably being reported by Moschkowitz in 1936 (27). Two more cases were recently described by Mandelbaum and Bryk bringing to only about seven the total number of authentic cases of amyloidosis associated with chronic ulcerative colitis that have ever been reported (28). There is usually a persistent albuminuria and obvious chronic suppuration present (26).

The therapy of regional enteritis has gone through many phases since the early days when the disease was first described as a clinical-pathologic entity (29). It may be that the modern-day treatment of patients with ileitis does not allow time for some of the changes reported in chronic ulcerative colitis to develop. Early recognition of ileitis probably leads to better therapy (using blood and plasma infusions, antibiotics, chemotherapy, parenteral vitamins, steroids, in-bed treatment, surgery, etc.). Again, a greater number of chronic ulcerative colitis cases have been observed, described and necropsied over many years, so that changes in the pancreas, liver and kidney and other organs would be more apparent than in regional ileitis. Further interest and studies along these lines to determine whether similar changes occur in regional ileitis is obviously indicated.

SUMMARY AND CONCLUSION

1. The extra-intestinal manifestations of regional ileitis are described and discussed.

2. A comparison is made with the extra-intestinal manifestations of ulcerative colitis.

3. Further studies of the extra-enteric manifestations of regional ileitis, both clinical and pathological, are indicated.

REFERENCES

1. Crohn, B. B.: Regional Ileitis. Grune and Stratton, 1949, New York.
2. Van Patter, W. N. Bargen, J. A., Dockerty, M. B., Feldman, W. H., Mayo, C. W., and Waugh, J. M.: Regional Enteritis. Gastroenterology, 26: 347, 1952.

3. Cohen, H., and Fishman, A. P.: Regional Enteritis and Amyloidosis. Gastroenterology, 12: 502, 1949.
4. Olsan, E. S., and Sussman, M. L.: Non-specific Entero-colitis. Amer. J. Roentgen., 60: 471, 1948.
5. Bargen, J. A., Jackman, R. J., and Kerr, J. G.: Studies on the Life Histories of Patients with Chronic Ulcerative Colitis (Thrombo-ulcerative Colitis), with Some Suggestions for Treatment. Anal. Int. Med., 12: 399, 1938.
6. Bockus, H.: Gastroenterology, Vol. 11, 172. W. B. Saunders Co., Phila., Pa.
7. Ricketts, W. E., and Palmer, W. L.: Complication of Chronic Non-specific Ulcerative Colitis. Gastroenterology, 7: 55, 1946.
8. Bargen, J. A.: Diseases of the Liver Associated with Ulcerative Colitis. Ann. Int. Med., 39: 285, 1953.
9. Kleckner, M. S., Jr., Stauffer, M. H., Bargen, J. A., and Dockerty, M. B.: Hepatic Lesions in the Living Patient with Chronic Ulcerative Colitis as Demonstrated by Needle Biopsy. Gastroenterology, 22: 13, 1952.
10. Logan, A. H.: Chronic Ulcerative Colitis: A Review of 117 Cases. Northwest Med., 18: 1, 1919.
11. Tumen, H. J., Monoghan, J. F., and Jobb, E.: Hepatic Cirrhosis as a Complication of Chronic Ulcerative Colitis. Ann. Int. Med., 26: 542, 1947.
12. Comfort, M. W., Bargen, J. A., and Morlock, C. A.: The Association of Chronic Ulcerative Colitis (Colitis Gravis) with Hepatic Insufficiency: Report of Four Cases. Med. Clin. N. Am., 22: 1089, 1938.
13. Brooke, B. N.: Ulcerative Colitis and Its Surgical Treatment. E. & S. Livingstone, Ltd., Edinburgh-London, 1954.
14. Hoffbauer, F. W., McCartney, J. S., Dennis, C., and Karlson, K.: The Relationship of Chronic Ulcerative Colitis and Cirrhosis. Ann. Int. Med., 39: 267, 1953.
15. Jones, G. M., Bagenstoss, A. A., and Bargen, J. A.: The Liver in Chronic Ulcerative Colitis. Proc. Soc. Staff Meet. Mayo Clin., 25: 251, 1950.
16. Landsbury, J., and Bargen, J. A.: Association of Multiple Hepatic Abscesses and Chronic Ulcerative Colitis. Med. Clin. N. Am., 16: 1427, 1933.
17. Ball, W. P., Bagenstoss, A. H., and Bargen, J. A.: The Pancreas in Chronic Ulcerative Colitis. Proc. Staff Meet. Mayo Clin., 25: 256, 1950.
18. Ball, W. P., Bagenstoss, A. H., and Bargen, J. A.: Pancreatic Lesions Associated with Chronic Ulcerative Colitis. Arch. of Path., 50: 347, 1950.
19. Warren, S., and Sommers, S. C.: Pathogenesis of Ulcerative Colitis. Amer. J. Path. 25: 657, 1949.
20. Clarke, C., and Hadfield, G.: Congenital Pancreatic Disease with Infantilism. Quart. J. Med., 17: 358, 1924.
21. Jankelson, I. R., McClure, C. W., and Sweetsir, F. N.: Chronic Ulcerative Colitis II: Complications outside the Digestive Tract. Rev. Gastroenterology, 9: 99, 1942.
22. Lindahl, W. N., and Bargen, J. A.: Nephrolithiasis Complicating Chronic Ulcerative Colitis after Ileostomy. J. Urol., 46: 183, 1941.
23. Schlicke, C. P., and Bargen, J. A.: Fulminating Ulcerative Colitis; Critical Analysis of 20 Cases. Minn. Med., 23: 348, 1940.
24. Jensen, E. J., Bagenstoss, A. H., and Bargen, J. A.: Renal Lesions Associated with Chronic Ulcerative Colitis. Amer. J. Med. Sci., 219: 281, 1950.
25. Bargen, J. A.: Chronic Ulcerative Colitis. Publication #101 Amer. Lecture Series, Chas. C. Thomas, 1951, Springfield, Ill.
26. Jensen, E. J., Bargen, J. A., and Bagenstoss, A. H.: Amyloidosis Associated with Chronic Ulcerative Colitis. Gastroenterology, 15: 75, 1950.
27. Moschcowitz, E.: The Clinical Aspects of Amyloidosis. Ann. Int. Med., 10: 73, 1936.
28. Mandelbaum, I., and Bryk, D.: Idiopathic Chronic Ulcerative Colitis and Amyloidosis. J. Mount Sinai Hosp., 22: 24, 1955.
29. Crohn, B. B., Ginzburg, L., and Oppenheimer, G. D.: Regional Ileitis: A Pathological and Clinical Entity. J.A.M.A., 99: 1323, 1932.

NON-SPECIFIC GRANULOMATOUS DISEASE OF THE STOMACH AND DUODENUM

ALEXANDER RICHMAN, M.D.

New York, N. Y.

The presentation of the concept of regional enteritis has been followed by wider recognition of the disease as originally described, and of its presence in other parts of the gastro-intestinal tract. In the past several years, papers have appeared describing granulomatous inflammatory disease involving the esophagus, stomach, duodenum, jejunum and colon. Various names have been applied, depending upon the segments involved and jejunoileitis and ileocolitis have been well recognized, and are dealt with elsewhere in this symposium. More recently, numerous reports have appeared in which the disease has been present in the stomach and duodenum, and it is this group of cases with which this communication is concerned, and for which we are using the descriptive term, non-specific granulomatous disease of the stomach and duodenum.

Even before the original report on regional enteritis, the European literature contained references to non-specific granulomatous disease of the gastrointestinal tract including the stomach (1). Mock (2) described several cases of granuloma of the sigmoid, stomach, omentum and ileum in 1931, which were due to penetrating foreign bodies, diverticulitis, strangulated herniae and retained sutures. He felt that trauma was the most likely etiologic agent. The underlying pathological process was that of granuloma with heaping up of granulation tissue, giant cells, ulceration, necrosis and fibroblastic proliferation.

The recognition of diffuse jejunoileitis followed early upon the first report of regional enteritis. However, despite these and other reports, no references appear to the occurrence of this process in areas proximal to the jejunum until 1939, when Shapiro (3) reported two cases of regional enteritis involving the terminal duodenum and proximal jejunum. Ragnotti described a similar case in the same year (4). In 1946, Menzel and Boving (5) analyzed two cases involving the duodenum and jejunum. Janus (6) followed with one case of duodenal and jejunal granulomatous disease. Ross (7) described a case involving the stomach, small intestine and colon in 1949. Comfort (8) analyzed three cases of gastro-duodeno-jejunal granulomatous disease and others have reported ten additional cases. These represent a total of twenty documented cases in the literature to 1954, and are summarized in Table I.

ETIOLOGY

No new facts have been developed to cast any light on the mystery of the etiology of these or the much larger group of cases of regional enteritis. In fact, we can still say that in order to make the diagnosis of non-specific granulomatous disease, a definite etiologic factor must be missing. Of the twenty reported cases, there were no specific etiologic factors, such as syphilis, tuberculosis, amebiasis or

From the Department of Medicine and the Gastrointestinal Clinic, The Mount Sinai Hospital, New York, N. Y.

TABLE I

Twenty cases of gastro-duodeno-jejunal granulomatous disease

No.	Age	Sex	Site of Involvement	Author	Date
1	50	M	Duodenum; jejunum	Ragnotti, E. (4)	1939
2	—	—	Terminal duodenum, proximal jejunum	Shapiro, R. (3)	1939
3	—	—	Terminal duodenum, proximal jejunum	Shapiro, R. (3)	1939
4	38	F	Duodenum; jejunum	Menzel, W. & Boving, R. (5)	1946–7
5	62	F	Duodenum; jejunum	Menzel, W. & Boving, R. (5)	1946–7
6	22	M	Duodenum; proximal jejunum	Janus, W. L. (6)	1948
7	21	F	Stomach, small intestine and colon	Ross, J. R. (7)	1949
8	30	M	Duodenum	Case records of Mass. General Hospital (9)	1949
9	31	F	Duodenum; jejunum	Comfort, M. W., et al. (8)	1950
10	22	M	Stomach; duodenum; small intestine	Comfort, M. W., et al. (8)	1950
11	36	M	Stomach; duodenum; jejunum	Comfort, M. W., et al. (8)	1950
12	27	M	Duodenum; jejunum; ileum	Carlisle, J. and Judd, E. (10) (10)	1952
13	34	F	Stomach; duodenum	Brown, C. H. and Sims, J. R. (14)	1952
14	24	F	Stomach; duodenum; ileum	Brown, C. H. and Sims, J. R. (14)	1952
15	23	F	Stomach; ileum; colon	Martin, F. and Carr, R. (11)	1953
16	48	M	Esophagus; stomach; duodenum; jejunum	Heffernon, R. & Kepkay, P. (12)	1954
17	20	M	Stomach; duodenum; ileum	Richman, A., Zeifer, H., Winkelstein, A., Kirschner, P. and Steinhardt, R. (13)	1954
18	34	M	Stomach; duodenum; ileum; colon		
19	9	M	Stomach; small intestine		
20	39	M	Duodenum; jejunum	Roberts, S. E., Martin, W. J., Beahrs, O. H. (15)	1954

other parasitic infestations, amyloidosis, or sarcoid. The age range was from nine years to sixty two years. Eleven of the patients were male, seven female, and the sex of two others was not recorded.

Of the various etiologic factors in ileitis, only three bear discussion. The first is that the presence of this process in different segments of the gastrointestinal tract may represent a generalized reaction to stress on the part of the tract. Just as some individuals may react with peptic ulcer, others with ulcerative colitis, so others may respond with a reaction in different parts of the gastrointestinal tract. The stimulus may be stress only, but one must postulate an underlying predisposition in the gastro-intestinal tract which renders it vulnerable.

Since granulomatous inflammation is the outstanding anatomical characteristic suggesting reaction to a foreign body, the ingestion of foreign bodies has been

considered as a possible factor. In fact, one of the few successful laboratory methods of producing the disease is to feed ground glass to animals (16) and the suggestion has been advanced that tooth paste containing silicon dioxide may provide the material for the production of the disease in humans.

There is a possibility that some noxious element in the gastrointestinal stream is concentrated to a sufficient degree and then deposited in different sections of the tract evoking a foreign body reaction. At the present time this is purely a hypothesis and no evidence has as yet been advanced in substantiation (17).

PATHOLOGY

When proximal granulomatous inflammation is encountered at the operating table, the involved portions of the stomach and duodenum are diffusely thickened. The serosa is engorged and reddened and the surrounding lymph nodes are uniformly enlarged. The disease in the stomach may be so advanced as to simulate a tumor. Incision over this area will verify the absence of a tumor, but the walls may at times be very thick and dull grey in color, and are overlaid by an acutely inflamed mucous membrane with thickened folds and small ulcerations. The duodenum is frequently converted into a semi-rigid tube. The periduodenal tissues and pancreatic capsule may be inflamed and edematous.

Review of the microscopic reports available in the literature and our own cases has revealed two distinct microscopic patterns. Six cases presented the picture of a typical granulomatous inflammation with fibrosis and infiltration by plasma cells and giant cells. Three cases showed gastritis and duodenitis without tubercles, epithelioid cells and giant cells, but with considerable thickening and fibrosis of the submucosal layers.

In sections of the stomach, shallow ulcers extend to the muscularis mucosa with destruction of this muscularis mucosa. The base of the ulcer is covered by fibrinopurulent exudate. Beneath the exudate there is granulomatous inflammation with giant cells. In the adjacent mucosa, there are many polymorphonuclear cells. In the mucous glands and in the interstitial tissue there are increased numbers of plasma cells and lymphocytes. Dilated focal collections of lymphocytes are present in the submucosa.

Of major interest is the absence of fistulization between the stomach and adjacent structures. Apparently, despite the presence of superficial and deep ulcerations, there is no tendency to perforation into the omentum, small or large bowel, liver or pancreas. However, in these cases in which ileal disease accompanies the duodenal process, fistulization has been noted between loops of ileum and large bowel.

CLINICAL PICTURE

The clinical picture of combined granulomatous disease will vary according to that area in which the process has begun. If ileitis is present, initially, the well known syndrome of lower abdominal pains, diarrhea, fever, weight loss, rectal suppuration will dominate the picture and precede the upper gastrointestinal symptoms.

The development of disease in the esophagus is heralded by symptoms such as heartburn, and retrosternal pain, as described by Heffernon (12). This may progress to severe dysphagia due to narrowing of the inflamed esophagus. Comfort (8) has outlined a group of symptoms encountered in five patients with gastric disease. These included continuous and intermittent upper abdominal pains made worse by the ingestion of food, associated with loss of weight and strength, nausea, vomiting and diarrhea. Evidences of malabsorption were noted. Physical examination will reveal varying degrees of undernutrition and anemia. Lymph nodes have been felt in the neck, groins and axillae. Splenomegaly and hepatomegaly are not infrequently encountered, making the differential diagnosis a problem.

Endoscopic procedures have been reported. Esophagoscopy in one case in which X-rays had shown a polypoid mass in the lower esophagus, revealed inflammation in this area. Gastroscopy has demonstrated diffuse superficial gastritis with multiple areas of superficial ulceration. This is the picture of superficial gastritis, and is not necessarily pathognomonic of the granulomatous disease.

There are no unusual laboratory features which are of diagnostic value. Secondary anemia, leukopenia and elevated blood sedimentation rates are frequently present. There is evidence of disturbed liver function, although this may be encountered in later stages of the disease in which undernutrition is present. The stools have shown occult blood in several cases, due to bleeding from the ulcerations. Gastric analysis has revealed no particular elevation of hydrochloric acid and in long standing cases, hypoacidity and anacidity may be present. Occult blood has been demonstrated in the gastric contents.

Comfort (8) has emphasized the presence of deficient absorption. His cases showed macrocytic anemia, hypolipemia, hypoproteinemia, hypocalcemia, hypoprothrombinemia, and a flat oral glucose tolerance curve.

RADIOLOGIC FEATURES

On radiologic examination the single case in which the esophagus was diseased showed slight dilatation of the esophagus above the distal third (12). In this region, a polypoid mass about 2 cm. in diameter was demonstrated within the esophageal lumen with disappearance of the normal esophageal mucosal pattern adjacent to the mass.

In the gastric cases, the radiologic appearance has usually been that of pyloric obstruction. A variably dilated stomach has been demonstrated proximal to a prepyloric area of constriction in which the normal mucosal pattern is not discernible (Fig. 1). A peculiar stippling of the mucosa of the stomach has been noted. The appearance may be indistinguishable from carcinoma, especially if the duodenal bulb shows no abnormality. In others, the duodenal bulb may be deformed, show mucosal thickening, or even be obliterated. The second portion of the duodenum may be narrowed and rigid, with complete loss of the normal mucosal architecture. Small ulcerations are sometimes identifiable.

When the more distal parts of the duodenum and the jejunum are diseased,

FIG. 1. Rigidity and constriction of the prepyloric region of the stomach in non-specific granulomatous disease.

the bowel may be converted into a rigid tube with loss of the usual mucosal pattern. Obstruction of segments proximal to the involved area is not uncommon. Occasionally the appearance may be indistinguishable from that produced by pancreatic tumors and by retroperitoneal masses. When the terminal ileum is diseased, the radiographic picture is similar to that seen in localized regional enteritis (Fig. 2).

DIFFERENTIAL DIAGNOSIS

The positive diagnosis of non-specific granulomatous disease of the stomach and small intestine is not simple, since it will depend upon exclusion of diseases with granuloma producing qualities. Despite the most painstaking efforts to exclude these processes, a definite diagnosis may require surgical exploration in most cases.

Syphilis of the stomach is very rare, paralleling the diminishing incidence of venereal disease. The presence of a positive serological test and the fairly characteristic X-ray appearance of a linitis plastica leather bottle type of stomach should help to differentiate. None of the cases which the author treated or re-

FIG. 2. Constriction of the terminal ileum with rigidity and coarsening of the mucosal pattern. Small bowel slightly dilated proximal to this area.

viewed showed a positive Wassermann test. Tuberculosis must always be considered in the differential diagnosis, but is rarely encountered in the stomach. The negative chest film and the absence of tubercle bacilli in the sputum and the gastric washings will be of value. Carcinoma of the stomach may present the most common diagnostic problem. Despite careful radiography, gastroscopy, gastric biopsy and cytologic studies, clarification may depend upon surgical exploration.

Lymphomatous disease, such as Hodgkin's disease and lymphosarcoma may

present the same picture involving the stomach and bowel, clinically and radiographically as granulomatous disease. Usually, the radiographic features are those of a mass with distortion of the mucosa, but obstruction is rare. In these instances, a lymph gland biopsy, gastric cytology or a chest film may help to differentiate. Failing these aids, exploratory operation may be required. Argentaffine tumors of the stomach and small intestine are extremely rare. They always present as a mass with evidence of obstruction and the diagnosis can be made only by operation. Boeck's sarcoid involving the stomach has been reported (18). The presence of the disease in the lungs, lymph glands and skin may help in differentiation. Amyloidosis of the stomach may be primary or part of a generalized infiltration secondary to suppurative disease or to multiple myeloma. The clinical picture should help to differentiate, but even with clearly defined amyloidosis, one case of amyloid infiltration simulated carcinoma so closely that exploration was required for clarification. Eosinophilic granuloma of the stomach may be suspected in patients with a mass and a very high eosinophilia in the peripheral blood.

Carcinoma of the pancreas and retroperitoneal tumors may produce a clinical and radiographic picture requiring differentiation. Pancreatic function tests, cytologic studies and peripheral lymph node biopsy may help to distinguish these, but the diagnosis again will depend on exploration. The various familiar types of gastritis would not seem to be related to the syndrome of non-specific granulomatous disease of the stomach. None of the cases of superficial or atrophic gastritis, as identified by the gastroscope, seem to have progressed to thickening of the deeper layers with formation of a mass. Where a mass has been present in association with this type of gastritis, a specific underlying disease such as carcinoma or a penetrating peptic ulcer has been identified. However, hypertrophic gastritis may produce a mass by virtue of its involvement of the mucosa and submucosa, but this gastroscopic picture has not been noted in any of the cases of non-specific granulomatous disease.

CLASSIFICATION

On the basis of three of the author's own cases, and of seventeen cases reported by others, a review of the clinical pattern permits classification into four groups:

Group 1. Distal disease followed by proximal disease (Cases 7, 17, 18, 20; Table I). This group includes four cases with typical regional enteritis or a history compatible with this disease who subsequently developed disease of the stomach or duodenum. One patient suffered from regional enteritis for five years, a second for two years, and a third for one and one half years, before the stomach was involved.

Group 2. Proximal disease followed by distal disease (Cases 10, 12; Table I). This group is composed of two cases who were operated upon because of upper gastrointestinal symptoms (i.e. pain, nausea, and vomiting) and were discovered to have granulomatous disease of the stomach and duodenum. Subsequently, the development of lower abdominal pain and diarrhea led to the discovery of ileitis.

Group 3. Proximal and distal disease occurring simultaneously (Cases 15,

19; Table I). There were two cases in whom nausea, vomiting, and diarrhea existed at the onset of the disease, and in whom disease was discovered in the stomach and in the ileum.

Group 4. Disease limited to the stomach and duodenum (Cases 1 to 6, 8, 9, 11, 13, 14, 16; Table I). This group was made up of eleven cases, and is the most common. One patient in this group suffered from esophageal disease at the same time. There are no follow-up reports to indicate the subsequent development of distal disease in the ileum, but it will be of interest to watch for this in the later course of these patients.

MANAGEMENT

It is tempting to formulate a program of treatment for these cases. Unfortunately, the diagnostic problem is complicated and the experience limited so that each case will be treated symptomatically. The major symptom requiring energetic therapy is gastric distention and pyloric obstruction. In the reported cases, this has been uniformly resistant to a conservative regimen of gastric lavage and antispasmodics, and surgical intervention has been necessary.

Simple gastrojejunostomy is indicated. In those cases in which a high gastric acidity has been demonstrated, a vagotomy would seem advisable to avoid the possibility of gastrojejunal ulcer. Excision of involved portions of the duodenum in these patients, many of whom are debilitated and are poor risks, would seem unwarranted since the disease process may be uninfluenced and the anastomosis be involved at a later date. The anatomical problems in this area in which the pancreas and the common bile duct are so intimately related, will prevent anything more than the by-passing operation of gastroenterostomy. It is extremely important that the surgeon be certain that the anastomosis is being made through healthy gastric and intestinal tissue, and frozen sections of the areas to be joined are advisable before completing the anastomosis.

Subtotal gastrectomy for lesions limited to the stomach and first portion of the duodenum would appear feasible in patients whose general condition is satisfactory. However, transection and suturing of a diseased duodenal stump may precede duodenal stump blowouts with serious consequences and even fatality, as in one reported case (11). Resection for massive hemorrhage may be required regardless of the operative difficulties and the possible complications.

The medical management of this condition has not been too rewarding as illustrated by the necessity for surgery in most of the reported cases. Treatment includes rest when indicated and supportive measures such as a high caloric diet, rich in vitamins. Hematinics are indicated for secondary anemia. Sedatives and antispasmodics should be used, including atropine and phenobarbital. The anticholinergic drugs such as banthine and antrenyl have not proved to be of value in any of the author's cases of duodenal ulcer with pyloric obstruction, and in fact, have served to aggravate the retention in many cases. For that reason, their use is not recommended in the pyloric obstruction associated with granulomatous disease of the stomach and duodenum.

Intestinal antiseptics such as sulfasuxadine and the broad spectrum antibiotics including aureomycin, terramycin, and erythromycin have been used with

benefit. Cortisone and ACTH should be of value, as evidenced by a good clinical response in one case. However, the possibility of perforation and bleeding in the course of hormonal treatment warrants caution.

SUMMARY

A review of twenty reported cases on non-specific granulomatous disease of the stomach and duodenum indicated that this syndrome may occur in association with regional enteritis or as an isolated entity. The etiology is obscure. Of interest in the pathologic features is the absence of fistulization. The major symptoms are those of pyloric and duodenal obstruction. Surgery has been required for definitive diagnosis and treatment in most cases, and presents some important problems in management due to the location of the disease and the difficulty of making anastomoses through diseased tissue. There is no specific medical management other than symptomatic therapy, but the use of corticotropin and ACTH has proved of some value.

REFERENCES

1. Braun, H.: Ueber Entzündliche Geschwülste des Netzes. Arch. Klin. Chir., 63: 378, 1901.
2. Mock, H. E.: Infective Granuloma. Surg., Gynec. and Obst., 52: 672, 1931.
3. Shapiro, R.: Regional Ileitis: A Summary of the Literature. Amer. Jour. of Med. Sciences, 198: 269, 1939.
4. Ragnotti, E.: Regional Enteritis with Two Cases. Arch. Ital. di Chir., 56: 237, 1939.
5. Menzel, W., and Boving, R.: Jejunitis Necrotans. Artzliche Wachenschrift, 1–2: 421, 1946.
6. Janus, W. L.: Regional Jejunitis. Radiology, 50: 532, 1948.
7. Ross, J. R.: Cicatrizing Enteritis, Colitis and Gastritis. Gastroenterology, 13: 344, 1949.
8. Comfort, N. W., Weber, H. M., Baggenstoss, A. H., and Kiely, W. I.: Non-specific Granulomatous Inflammation of the Stomach and Duodenum; Its Relation to Regional Enteritis. Amer. J. Med. Sciences, 78: 616, 1950.
9. Case Records of the Massachusetts General Hospital. New Eng. J. Med., 240: 692, 1949.
10. Carlisle, J. C., and Judd, E. S.: Regional Enteritis, Involving the Duodenum: Report of a Case. Proc. Staff Meet. Mayo Clin., 27: 569, 1952.
11. Martin, F. R. R., and Carr, R. J.: Crohn's Disease Involving the Stomach. Brit. Med. Jour., 1: 700, 1953.
12. Heffernon, E. W., and Kepkay, P. H.: Segmental Esophagitis, Gastritis, and Enteritis. Gastroenterology, 26: 83, 1954.
13. Richman, A., Zeifer, H. Winkelstein, A., Kirschner, P., and Steinhardt, R.: Chronic Non-specific Granulomatous Inflammation of the Stomach, Duodenum and Intestine. Gastroenterology, (To be published).
14. Brown, C. H., and Sims, J. R.: Regional Enteritis Involving the Duodenum: Report of Two Cases. Clev. Clin. Quart., 21: 95, 1954.
15. Roberts, S. E., Martin, W. J., and Beahrs, O. H.: Regional Enteritis Involving the Duodenum: Report of Case. Proc. Staff Meet. Mayo Clin., 29: 424, 1954.
16. Chess, S., Chess, E., Olander, G., Benner, W., and Cole, W. H.: Production of Chronic Enteritis and Other Systemic Lesions by Ingestion of Finely Divided Foreign Material. Surgery, 27: 22, 1950.
17. Crohn, B. B., and Janowitz, H. D.: Reflections on Regional Ileitis—Twenty Years Later. J.A.M.A., 156: 1221, 1954.
18. Scott, N. M., Smith, V. M., Cox, P. A., and Palmer, E. D.: Sarcoid and Sarcoid-like Granulomas of the Stomach. A.M.A. Arch. Int. Med., 92: 741, 1953.

ANORECTAL COMPLICATIONS IN REGIONAL ILEITIS

SYLVAN D. MANHEIM, M.D., F.I.C.S.

New York, N. Y.

Despite the fact that 22 years have elapsed since the description of regional ileitis by Crohn, Ginzburg and Oppenheimer (1), little is known of the etiology of the disease and in many cases therapy is unsatisfactory. Despite the newer therapeutic agents such as cortisone, ACTH and the antibiotics, the disease steadily progresses and anorectal complications occur with comparative frequency. In many instances, the diagnosis is not suspected until a perianal abscess or fistula develops.

The occurrence of abdominal wall fistulae in association with regional ileitis is well known and has been reported frequently, but there has been little attention called to the perirectal and perianal fistulae. This type of fistula is fairly common. Penner and Crohn (2) in 1938 reported 110 cases of regional ileitis, with 18 per cent of the cases showing anorectal fistula, while Jackman and Smith (3) in 1943 reported an incidence of 31.6 per cent of perianal abscess or fistula in a series of 114 cases. Of these 114 patients, eight came to the Mayo Clinic only because of the anal fistula and had no intestinal symptoms until a much later date.

Anorectal fistulae may occur as a direct extension from the diseased segment of ileum or by infection through the crypts of Morgagni. It is conceivable that fistulous tracts from the ileum to the perirectal tissues can form just as fistulae form between loops of intestine or between intestine and bladder or intestine and abdominal wall. Infectious material can seep downward along the planes of the pelvic fascia through the puborectalis portion of the levator ani muscle and cause either a perirectal, perianal or ischioanal abscess. The abscess may then open spontaneously or be incised with a resulting fistula.

Attempts have been made to visualize the tract by injections of a radiopaque substance with little success. The long tortuous fistulae from the ileum to the anorectum are uncommon.

The short straight simple fistula is most commonly seen. These are probably due to infection arising in the crypts of Morgagni. The infection may be due primarily to the deposits of infectious material in the crypt or it may arise as a secondary infection in a traumatized crypt due to the diarrhea. Fistula-in-ano occurs rather commonly in diarrheal conditions of various origins and may originate in a fissure-in-ano or in a torn valve which forms the crypt. The infection then travels laterally along the fascial planes around the anal canal. These fascial planes surround the three bellies of the external sphincter muscle and are derived from the conjoined tendon of the puborectalis muscle. If the infection travels between the deep and superficial portions of the external sphincter, the resulting abscess will be in the ischio-anal space. If the infection travels along the

From the Department of Surgery, The Mount Sinai Hospital, New York, N. Y.

superficial and subcutaneous external sphincters, the resulting abscess will be in the perianal space. As soon as the abscess opens or is incised, the incomplete fistula has been converted into a complete fistula.

The treatment of the anorectal complications in regional ileitis falls into two categories.

1) *Abscess.* Any abscess in the anorectal area must be incised early. Conservative treatment such as sitz baths, warm packs, antibiotics, and ointments, should never be used. These infections spread under the subcutaneous tissues and the longer one waits, the more severe and widespread the infection.

2) *Fistula.* There is no hard and fast rule as to the treatment of fistulae associated with regional ileitis. It must be remembered that the cure of a fistula in most cases requires surgical division of one or more portions of the external sphincter. In some cases, the internal opening may be situated high in the anal canal and the cure of the fistula would then require division of the entire external sphincter. This procedure may result in partial or complete incontinence or it may result in a decided weakness of the sphincter without incontinence. In the presence of a chronic diarrhea, this can be a very distressing condition. It is certainly far better for a patient with chronic diarrhea to be left with a draining sinus rather than with a partially or completely incontinent sphincter. In this type of case it is important that constant drainage from the fistula be established.

The patient must be seen frequently and the fistulous tract probed in order that the external orifice be kept open and draining. If the external opening of the fistula should close, an abscess will reform.

Fistulectomy should not be done until such a time as the ileitis becomes inactive or is cured by abdominal surgery. Any anorectal surgery may cause an acute exacerbation of the ileitis. Healing of the anorectal wounds is slow, the perianal skin becomes markedly excoriated and the patient is in constant discomfort.

Just as in ulcerative colitis, perianal infections may result in multiple fistulae which may threaten health and well being to such an extent that a diversion of the intestinal contents may become a necessary expedient. This is particularly true in cases of recurrent ileitis following unsuccessful short-circuiting intestinal operations. In this situation, the perianal abscesses and fistulae with spreading infection may force the performance of a diversionary ileostomy after which the perianal infections usually subside.

This also applies to rectovaginal fistulae, which complicate regional ileitis quite often. Any attempt to repair a rectovaginal fistula in the presence of diarrhea and disease in the intestinal segments is doomed to failure unless the original pathologic process is resected or diverted by an ileostomy.

It is important to remember that perianal abscess or fistula-in-ano may be the very first indication of regional ileitis. There are many patients who develop abscess and fistula and have no intestinal symptoms or the intestinal symptoms may be so minimal that they are obscured by the main complaint (anal abscess and fistula. For this reason it is imperative that in any case of fistula, a careful history must be taken to detect the slightest intestinal or abdominal symptoms. Sigmoidoscopy must be performed in every case of fistula so that early changes in

the appearance of the mucosa can be detected. If there are any abdominal or intestinal symptoms associated with anorectal fistula, barium enema and gastrointestinal x-ray series are indicated. The combination of anal abscess or fistula and any vague intestinal disturbance in a young adult should direct suspicion to the possibility of regional ileitis.

REFERENCES

1. Crohn, B. B., Ginzburg, L., and Oppenheimer, G. D.: Regional Ileitis; A Pathologic and Clinical Entity. J.A.M.A., 99: 1323, 1932.
2. Penner, A., and Crohn, B. B.: Perianal Fistulae as a Complication of Regional Enteritis. Ann. Surg., 108: 867, 1938.
3. Jackman, R. J., and Smith, N. D.: Some Manifestations of Regional Ileitis Observed Sigmoidoscopically. Surg., Gynec. and Obst., 76: 444, 1943.

REGIONAL ILEITIS IN CHILDREN

HERMAN ANFANGER, M.D.

White Plains, N. Y.

Regional ileitis in children has been mentioned on many occasions in the literature but usually in a casual and minor manner. Storrs and Hoekelman (1) in 1953 reviewed the literature and were able to find only 25 cases of acute ileitis and three cases of chronic ileitis in children. They added eight more cases of acute regional ileitis and were impressed by the fact that six of eight children who had a lengthy follow-up ranging from three to thirteen years were completely cured. They therefore suggested that acute regional ileitis might in itself be a specific entity, rather than an early stage of chronic regional ileitis. The object of this study is to report 11 more cases of regional ileitis beginning before the age of 14 years. All of these cases, however, went on to develop the slowly progressing chronic pattern and, in seven, varying degrees of intestinal obstruction occurred, necessitating surgical intervention.

These cases were obtained from two sources. Admissions to The Mount Sinai Hospital during the past five years were reviewed and six such cases discovered. The remaining five cases were obtained from the personal records of Dr. B. B. Crohn, one of the original discoverers of this entity (2). At present, he has personally seen and followed the astounding number of over 600 proven cases. These 5 cases found and presented are by no means the total number of cases of regional ileitis found in children in his files but were culled from close examination of only 50 histories taken at random.

Van Patten et al (3) in a monograph reviewing 600 cases from the Mayo Clinic noted that 85 cases or 14 per cent of the series began under the age of 15 years. They showed the following breakdown for age of onset:

Age at Onset	*Number of Cases*
4 years	2
5–10 years	21
11–15 years	62
	85

It may be estimated that approximately 10 to 15 per cent of all cases of regional enteritis begin in childhood. One needed only to take careful histories of several patients to realize that intestinal symptoms had been present, often for many years, before the overt picture of ileitis became manifest.

The symptoms that were noted most often during the early and usually undiagnosed periods consisted of vague, intermittent abdominal cramps, moderate to severe in character and diarrhea alternating at times with constipation. Anemia, loss of weight and, occasionally fever were often early symptoms. It thus becomes quite evident that, except for real obstructive manifestations, the

From the Department of Pediatrics, The Mount Sinai Hospital, New York, N. Y.

symptoms of early ileitis are almost exactly the same as those seen later in the course of the disease. Diarrhea as such is rarely as severe, as that of ulcerative colitis. It may be, that in regional ileitis, with the large bowel intact for the most part, most of the liquid of the abnormal stools is reabsorbed as it passes through the colon.

A mass in the right lower quadrant is an infrequent finding in children, mainly because they have not had the disease long enough, for it takes several years before enough matting together of intestinal loops occurs in association with encapsulated perforations.

It is of interest that in this study, there were encountered several instances of perirectal fistulae which were treated many years before the definite diagnosis of regional ileitis was confirmed.

The etiology of regional ileitis is still unknown. The Shigella or Flexner dysentery organism has been incriminated in the past but has not been proven to be so in practically recent studies. In fact, it has been stated that the diagnosis cannot be made unless stool cultures are repeatedly negative. Viral studies have as yet been fruitless. However, as noted by Crohn and Janowitz (4), "It is hard to explain the intermittent character of the disease with free periods up to several years, in the presence of persistent virus infection".

Although allergic manifestations involving the intestinal tract are common in infancy, they usually disappear with the onset of late childhood. Certainly there does not seem to be enough evidence in most cases to explain regional ileitis on an allergic basis.

The term acute ileitis has been applied more frequently to young children than to adolescents. It may be that in young children with thin loops of bowel, the edema, which is an invariable part of the disease, produces more narrowing and therefore earlier obstructive symptoms. In the adolescent the same degree of edema would not be sufficient to produce significant symptoms and might therefore be missed.

The question of mesenteric adenitis in relation to regional ileitis is interesting, but as yet not adequately explained. Hadfield (5) in 1939 recognized the presence of lymphatic obstruction in this disease and tried to differentiate pathologically between a primary and secondary type of lymphatic obstruction. Warren and Sommers (6) first described focal lymphatic endothelial proliferation and stressed its significance as a cause of secondary lymphatic obstruction.

Erskine (7) studied pathologically 31 cases of appendicitis and noted that in 33 per cent there was inflammation of the terminal ileum and regional mesenteric adenitis as noted by the surgeons. The author therefore felt that in some cases the mesenteric lymphadenitis was primary and appendicitis and regional ileitis secondary. Segar and Rosenak (8), in reviewing cases of non-tuberculous lymphadenitis, were impressed with the fact that mesenteric glands at the ileocolic angle were most often involved and hyperplastic. Perhaps it is because the fecal flow is at its lowest ebb at this point that greater bacterial concentration in the stool occurs and therefore greater chance of bacterial seepage into the lymphatic system. Once lymphatic obstruction is present, the venous pressure rises. This

in turn would produce more engorgement of mucous membrane and decreased resistance to any toxic agent. Perhaps this type of vicious cycle may be instrumental in the progress of the disease.

Intussusception as a complication of this disease is unknown. This is very likely due to the fact that edema and thickening develop very early and are quickly followed by adhesions between the loops of bowels. The question of family history has been discussed by Crohn and Janowitz (4) who noted the occurrence 11 times in over 600 cases studied. They concluded that there was not enough evidence to consider this disease to be familial in character. It is interesting that in Case 8 (Table I), the patient was one of identical twins and he alone had the disease.

Early in the knowledge of this disease it was felt that appendectomy should not be performed during the acute stage lest chronic abdominal wall fistulae develop. This complication rarely occurs directly, although appendectomy as such has no effect on the course of the disease.

The roentgen findings in regional ileitis in children are similar to those seen in adults and have been very adequately described by Marshak et al (9). These findings are diagnostic in themselves. The X-ray picture closely follows the pathological changes and have been divided for purposes of classification into stenotic and non-stenotic phases.

The management of ileitis in children is also similar to that in adults. It is treated from a medical and surgical viewpoint. Medical management should always be tried first unless the findings of an acute surgical abdomen are overwhelming. The medical management in each case has to be individualized since the etiology is obscure. Improving nutrition is essential in all cases since all patients manifest evidence of malnutrition. Adequate caloric and electrolyte intake must be stressed. Diet should be high in protein and carbohydrate, but low in fat to prevent bloating and foul stools. Hemoglobin should be checked frequently and kept at adequate levels. If necessary, repeated transfusions should be given. Vitamins also should be supplied adequately.

Antibiotics and sulfonamides also should be tried. Although no specific bacteria have been incriminated, perhaps by reducing the total number of bacteria locally in the intestinal tract, some irritating substances are removed from the involved area and allow for some healing. Non-absorbing sulfonamides such as sulfasuxidine, sulfaguanidine and sulfathalidine have repeatedly produced temporary improvement. The broad spectrum antibiotics and streptomycin also have been shown to be valuable in this disease.

Corticotropin and cortisone have been tried, however, there is a growing feeling that, as in ulcerative colitis, they are not of permanent value. Perhaps the anti-inflammatory action of steroids is offset by their opening up of new areas of invasion by omnipresent bacteria. In conclusion, medical management should be continued until the following complications occur: (a) failure to maintain a reasonable state of health; (b) intestinal obstruction; (c) fistulae involving sigmoid and bladder; (d) anal and rectal complications of stricture and incontinence.

TABLE I

Case	Age at Onset & Symptoms	Status, Operation, Age	Result
1. A. A.	12—vague abdominal pains.	Appendectomy at 12 yrs. Ileocolic resection at 16 yrs. Ileojejunal resection at 25 yrs.	Unimproved.
2. Ada A.	11 intermittent abdominal pain.	Exploratory—Diagnosis of Tuberculous Ileitis at 13 yrs. Ileocolostomy at 14 yrs. Resection of 6 ft. ileum at 21 yrs. Secondary resection 1½ ft. ileum at 27 yrs.	Unimproved.
3. S. A.	11 abdominal pain.	Rectal abscess at 14 yrs. X-ray evidence of terminal ileitis, narrowing	Improved temporarily.
4. M. A.	14—Diarrhea and abdominal pain.	Ileotransversostomy at 24 yrs. Obstruction symptoms at 27 yrs. Removal of entire ileum and part of jejunum at 31 yrs.	Weight gain; Improved after surgery.
5. D. A.	14—Diarrhea, cramps, 20 lb. weight loss in 1 year.	Obstructive phenomena. Diffuse ileojejunitis, duodenitis and possible gastric involvement at 18 yrs. Ileotransversostomy at 18 yrs.	Improved after surgery.
6. M. K.	14—Abdominal cramps, constipation.	Ileotransversostomy at 20 yrs.	Improved after surgery.
7. L. S.	10—Bloody diarrhea, weight loss, fever, nonspecific abdominal pain.	Gastro-intestinal series at 12 yrs. revealed diffuse jejunitis.	Follow-up 3 yrs Intermittent symptoms with weight loss.
8. J. R. (Identical twin)	11—Weight loss, fever, diarrhea, clubbing of fingers.	X-ray evidence of ileojejunitis at 11½ yrs. Terminal ileum fully distensible. EEG: abnormal bursts in diencephalic area.	Medically unimproved.
9. T. H. (Omphalocele at birth. Ileocolostomy at 3 days of life.)	7½ yrs.—Abdominal periumbilical pain 1–3 times daily, irregular	Admitted with hematemesis and Melena at 8 yrs. X-ray evidence of filling defects in terminal ileum with adherent loops. Resection of ileum, cecum, colon. Ileotransversostomy (6 wks. after 1st admission).	Improved after surgery.
10. R. R.	12 yrs.—intermittent abdominal pain for 1 yr. with diarrhea. Intermittent abdominal pain for 8 yrs.	Anal fistula at 17 yrs. Appendectomy at 18 yrs. X-ray revealed ileitis at 20 yrs. Ileotransversostomy at 20 yrs.	Improved after surgery.
11. P. S.	12 yrs.—abdominal cramps for several months. Upper G.I. series neg. 15 yrs.—Recurrence thought to be chronic appendicitis.	X-ray evidence of involvement of stomach, duodenum, jejunum and ileum at 16 yrs.	Treated medically. Improved temporarily.

The type of surgical procedure performed depends primarily upon the extent and degree of stenosis and fistula formation. As can be seen, even in the few cases presented in this paper (Table I), resection is not a cure. Recurrences of stenosis, even after resection, take place in 20 to 30 per cent of such cases.

CONCLUSION

Regional ileitis beginning in children under 14 years of age occurs more often than commonly believed. In a careful study of about 75 cases admitted to The Mount Sinai Hospital in the past five years and in the personal files of Dr. B. B. Crohn, 11 such instances were uncovered. Although first hospital admissions occur most often during adolescence, careful history will bring to light many persistent low-grade symptoms that have been present for years. The outlook of regional ileitis in children is no better than in adults. It is a chronic, slowly progressive disease that usually goes on to stenosis and fistula formation.

REFERENCES

1. Storrs, R. C. and Hoekelman, R. A. Acute Regional Enteritis in Children. New Eng. Jour. Med., 248: 320, 1953.
2. Crohn, B. B., Ginzburg, L. and Oppenheimer, G. D.: Regional Ileitis—A Pathological and Clinical Entity. J. A. M. A., 99: 1323, 1932.
3. Van Patten, Ward N. et al. Regional Enteritis. Gastroenterology, 25: 347, 1954.
4. Crohn, B. B. and Janowitz, H. D.: Reflections on Regional Ileitis Twenty Years Later. J. A. M. A., 156: 1221, 1954.
5. Hadfield, G.: The Primary Histological Lesion of Regional Ileitis. Lancet, 2: 773, 1939.
6. Warren, S. and Sommers, S. C.: Cicatrizing Enteritis (Regional Ileitis) as a Pathological Entity. Am. J. Path., 24: 475, 1948.
7. Erskine, E. B.: The Pathological Relationship of Mesenteric Adenitis, Ileitis and Appendicitis. Am. J. Clin. Path., 11: 706, 1941.
8. Segar, L. H., and Rosenak, B. D.: Non-Tuberculous Mesenteric Lymphadenitis in Childhood. Am. J. Digest Dis., 42: 356, 1935.
9. Marshak, R. H., Friedman, A. I., Wolf, B. S., and Crohn, B. B.: Roentgen Findings in Ileojejunitis. Gastroenterology, 19: 383, 1951.

THE ROENTGEN FINDINGS IN REGIONAL ENTERITIS

RICHARD H. MARSHAK, M.D. AND BERNARD S. WOLF, M.D.

New York, N. Y.

Inflammatory lesions of the small intestine producing radiological changes are being recognized with increasing frequency. By far, the most important of these, both in frequency and in clinical implications, is the entity which has come to be known as regional enteritis. As originally described in 1932, this ailment was thought to affect solely the distal ileum. Numerous subsequent investigations have amply demonstrated that the intrinsic pathology of terminal ileitis may be seen in any portion of the small intestine, and, on occasion, even in the stomach.

Seven hundred and fifty patients with regional enteritis were studied over a period of one to twelve years and this provided the opportunity for serial roentgen investigations. Although many of the specific roentgen features of this disease have been described previously, this study will report the roentgen findings from the earliest alterations detectable radiologically to the late stenotic stage as well as the roentgen changes characteristic of the site of involvement. It is impossible to state whether earlier changes different from those described below exist or can be recognized as most of the patients are examined radiologically when the disease process is already well established. It has been possible, however, to show the early changes in recurrences following side-tracking operations and these changes are similar to those noted in the intestinal segments less severely involved by regional enteritis.

ROENTGEN FINDINGS IN REGIONAL ENTERITIS

Several investigators have divided the roentgen findings in this disease into acute, subacute and chronic stages (1). Since the classical form of regional enteritis is that of a low grade inflammatory process with episodes of acute exacerbation, it is difficult to identify such a clear-cut pattern. Acute granulomatous regional enteritis has been described, but the determination of the precise time of onset of this disease is unusually difficult. What is described as acute regional enteritis may be the more active phase of this chronic illness (2).

Proximal and distal extension of the disease process, despite repeated roentgen examinations extending over a period of many years, was not observed. The maximum length of involvement was determined on the initial roentgen studies. This is not true after exclusion operations when recurrent disease is frequent.

One of the prominent features of this disease is the development of stenosis with obstruction. Therefore, roentgenologically, the cases may be divided arbitrarily into stenotic and non-stenotic groups (3, 4). It is impossible to classify these groups as early and late, since the majority of cases may continue without stenosis for many years. Again, division into active and inactive seems inappropriate, as the patient with long segments of stenotic bowel may also exhibit

From the Department of Radiology, The Mount Sinai Hospital, New York, N. Y.

considerable evidence of clinical activity, manifested by fever, diarrhea and abdominal pain.

Non-stenotic Phase. The roentgen findings closely parallel the pathological features. The earliest mucosal alterations are blunting, flattening and thickening of the valvulae conniventes. The folds are arranged in a fairly regular symmetrical parallel fashion and as progression occurs, may become thicker, irregular and partially fused (Fig. 1A). The bowel lumen becomes irregular in width. These changes are due to the inflammatory submucosal and mucosal thickening. When ulceration occurs a more characteristic pattern is produced. Longitudinal streaks of barium recognizable as ulcerations appear (Fig. 1B). As the thick, blunted folds of mucosa are further destroyed, cobblestoning may be noted (Fig. 2A). This specific pattern is more common in the jejunum, probably because of the thicker valvulae in this region. Ulceration continues at the expense of the intervening islands of mucosa, replacing the cobblestone pattern by an irregular network of interlacing streaks of barium. The appearance at this stage has no uniformity or symmetry and is hazy and reticulated. Denudation of the mucosa is usually incomplete, leaving behind islands of inflamed mucosa which produce multiple smooth defects of varying size (Fig. 2B). Their prominence is increased by the narrowing of the bowel lumen which is due to beginning cicatricial contraction that occurs at this stage. Finally, one may see the radiologic image of a uniform, rigid, castlike tube filled with barium and presenting no mucous membrane pattern. This is similar to ulcerative colitis and represents the stage when scarring and regeneration of an atrophic mucosa is progressing (Fig. 3A). As scarring proceeds, the transition to the stenotic phase occurs. An uncommon but striking finding is the presence of large inflammatory polyps (Fig. 4A). Ordinarily the polyps are much smaller. Carcinomatous transformation of these polyps has not been observed. Coincident with changes in the mucosa, other characteristic roentgen features occur. The bowel lumen reveals varying degrees of narrowing (Fig. 1A). Early, the submucosal thickening and associated spasm are responsible for the narrowing of the lumen. Later, as fibrosis occurs, the narrowing is more marked and leads finally to the stenotic stage (Fig. 4B). In the early stages, rigidity of the contour and mucosal pattern is incomplete. Some flexibility or dynamic activity is evident in the change in contour and mucosal pattern during successive roentgenograms (Fig. 1A). Later, the roentgen appearance is fixed and unvarying (Figs. 3A–4B). Pliability is lost. Also early in this disease, the normal serpentine or coiled pattern of the loops of small bowel disappears. The diseased segments appear to be straightened and rigid (Figs. 1A, 2B). This finding is probably due to loss of flexibility of the bowel wall and mesentery, as well as longitudinal shortening due to spasm.

Frequently, the loops of intestine appear to surround a mass (Fig. 5A). Although this may be due to an abscess resulting from perforation, more often it is secondary to the indurated mesentery, associated with the marked increase in the mesenteric fat and the enlarged lymph nodes. The silhouette of the intestine may be hazy. This is due to the fact that the intestine is diffusely ulcerated, contains exudate and excessive secretions and the barium does not adhere to the

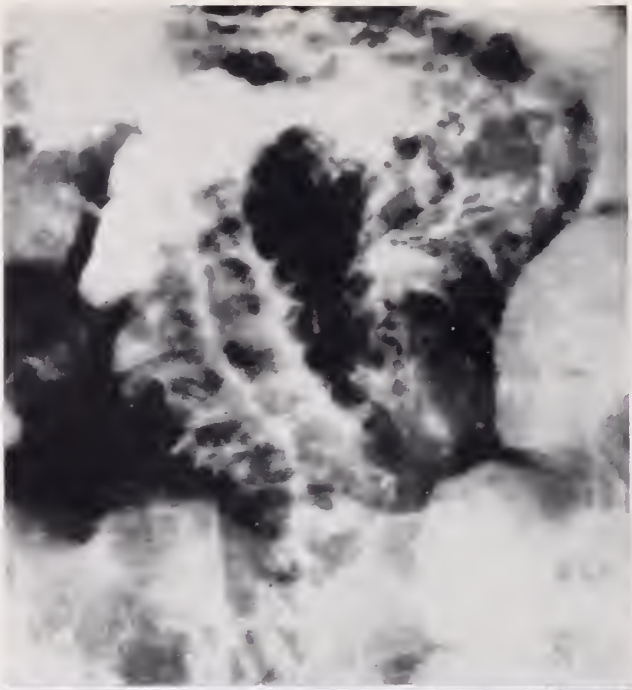

FIG. 1B

FIG. 1A

FIG. 1A. The folds are thickened, blunted and in some areas fused. The contour is irregular. There is rigidity and separation of the loops of intestine. The intestinal loops appear straightened or uncoiled. Diagnosis: Non stenotic type of regional enteritis.

FIG. 1B. Longitudinal streaks of barium indicating ulceration are seen. The contour is irregular, with some rigidity and separation of the loops of intestine. Diagnosis: Nonstenotic type of regional enteritis.

Fig. 2A

Fig. 2B

Fig. 2A. A cobblestone pattern is noted. In other areas the folds are thickened and blunted. The loops of intestine are moderately rigid and somewhat separated. Diagnosis: Non-stenotic type of regional enteritis.

Fig. 2B. There is rigidity, separation of the loops of intestine, numerous small filling defects due to inflammatory polyps, and eccentric skip areas. Diagnosis: Non-stenotic form of ileojejunitis.

FIG. 3A

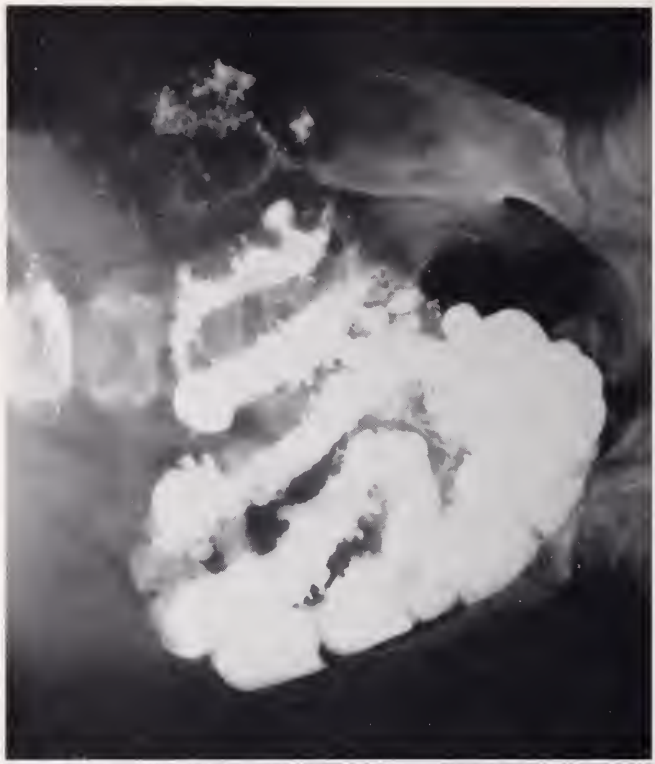

FIG. 3B

FIG. 3A. The loops are rigid and markedly separated. The mucosal pattern appears castlike. Several small filling defects are noted due to inflammatory polyps. Diagnosis: Nonstenotic type of ileojejunitis.

FIG. 3B. The diseased loops of intestine are moderately rigid and separated. The folds are thickened and blunted. Pseudodiverticula are present. Diagnosis: Non-stenotic type of regional enteritis.

FIG. 4A

FIG. 4B

FIG. 4A. Large filling defects. There is a moderate degree of rigidity with areas of narrowing. The loops are separated. Diagnosis: Non-stenotic type of ileojejunitis.

FIG. 4B. Some patient as in figure 4A ten years later. At this time the lumen of the intestine is narrowed. The filling defects previously described are not as prominent. There is no evidence of an inflammatory mass. Diagnosis: Stenotic phase of ileojejunitis.

FIG. 5A FIG. 5B

FIG. 5A. The mucosa is cast-like with inflammatory polyps. The affected loop is rigid and narrowed with an associated inflammatory mass. Diagnosis: Early stenotic stage of ileojunitis.

FIG. 5B. The distal jejunum and proximal two-thirds of ileum show long areas of narrowing alternating with areas of dilatation. The mucosal pattern in the stenotic areas is reticulated. The loops of intestine are widely separated and rigid. Diagnosis: Stenotic phase of ileojejunitis.

walls. Despite the increase in intestinal content, the barium mixture remains fluid and homogeneous. Neither agglutination, clumping or formation of masses of barium is found in regional enteritis, as contrasted with the findings in the so-called sprue pattern. Segmentation such as is characteristic of spure has not been observed. When unequivocal segmentation occurs, the diagnosis of regional enteritis should be suspect. Skip areas (Fig. 2B), that is, segments of normal intestine intervening between diseased segments, represent another characteristic feature. The length of a skip area may vary from a few inches to several feet. The extent of involvement on a roentgenogram may be quite accurately determined in most cases, since the transition of disease to the normal intestine is fairly abrupt. An outpouching of the mucosa between the thickened folds (Fig. 3B) occurs in some cases, creating an appearance suggesting large diverticula. This is peculiar in that it seems to affect one side of the intestine and not the other. These pseudodiverticula probably represent small eccentric skip areas.

Stenotic Phase. In the stenotic stage, many of the rigid loops described previously become constricted to a remarkable degree. These stenotic segments resemble rigid pipestems (Figs. 5A, B and 6A, B). This appearance is due to a marked thickening and contraction of the wall of the small intestine. The stenosis may extend through 1 or 2 cm. or over long segments. With severe narrowing, dilatation of the proximal intestine may be marked. In many instances, it is difficult to state whether or not intrinsic disease is present in a dilated area. Very often disease is present when a loop of dilated intestine exists between two points of constriction. On the other hand, when there is a single area of constriction with proximal dilation, disease may not be present in the dilated segment. However, because of retained secretions, secondary inflammatory changes, tension ulcers and muscular hypertrophy, the appearance of the dilated loops may be confused with the alterations seen in regional enteritis. This distinction is of great importance when considering surgical therapy. Many cases have not undergone operative intervention because the surgeon was of the opinion that the entire intestine was involved. Extreme dilatation of the intestine for long segments is rarely associated with intrinsic granulomatous disease.

Many of the roentgenographic phenomena observed in the non-stenotic phase of the disease are again noted in the stenotic phase. The mucosal pattern is usually reticulated or cast-like. Small filling defects, inflammatory polyps, irregularly distributed throughout the diseased segments, are noted. Skip areas and wide spacing between the segments of intestine are more striking (Figs. 5A, B and 6A, B).

The loops are rigid and maintain a constant position from film to film. Fistulae, usually involving the distal ileum, are frequent (Fig. 9A). Occasionally, these are very diffcult to demonstrate, especially when dilated loops of intestine produce overlapping. The fistulae may extend to and penetrate the abdominal wall.

In general the roentgen findings in regional enteritis are as described, however, there are certain characteristics which are peculiar to the area of involvement.

Ileum. The most frequent site of involvement of the small bowel with regional enteritis is the terminal ileum (Figs. 7A, B). Five hundred and six cases revealed



Fig. 6A

Fig. 6B

Fig. 6A. The entire small intestine is involved with alternating areas of constriction and dilatation. There is separation of loops of intestine. The mucosal pattern in some areas is cast-like and in others reticulated. The intestinal loops appear to surround masses. Diagnosis: Stenotic phase of regional enteritis.

Fig. 6B. Long rigid narrowed segments resembling pipe stems with a large inflammatory mass. Diagnosis: Stenotic phase of regional enteritis.

FIG. 7A

FIG. 7B

FIG. 7A. "String sign" in regional enteritis.
FIG. 7B. Same patient as 7A, a few minutes later, illustrating distensibility. Note also, spasm of cecum.

Fig. 8B

Fig. 8A

Fig. 8A. Terminal ileitis with numerous sinuses and fistulas. Some of these extended into the urinary bladder.
Fig. 8B. Terminal ileitis with large fistula between terminal ileum and ascending colon.

involvement of the distal nine to twelve inches of terminal ileum. One hundred and twenty six patients had involvement of the entire ileum (Fig. 9A).

The string sign which has come to be identified as the pathognomonic roentgen manifestation of regional enteritis is most frequently noted in this region. It has been described as a thin, linear shadow, suggesting a frayed cotton-string in appearance. (Fig. 7A). The cause of the string sign is incomplete filling due to irritability and spasm associated with marked ulceration and may be seen in both the non-stenotic and stenotic phase of this disease. Repeated spot films will demonstrate the fact that some distensibility is still present in this segment (Fig. 7B). The bowel proximal to the string sign may or may not be dilated depending on the stage of the disease. In the non-stenotic phase the proximal intestinal lumen is generally not dilated despite the marked narrowing associated with the string sign, indicating the importance of spasm in producing this characteristic appearance. This spasm is usually inconstant. When persistent, temporary proximal dilation can occur with symptoms of obstruction. In the stenotic phase there is constant proximal dilatation which may be accentuated by spasm secondary to ulceration. Despite the narrowing complete intestinal obstruction is rare. The recognition of the fact that the string sign does not always indicate marked fibrosis and stenosis is important as exclusion operations during the stage of marked ulceration and activity have been followed by a high degree of recurrence.

Because of the marked ulceration, fistulae and perforation (Fig. 8A), thickening of the mesentery and separation of the loops of bowel are more frequent in the distal ileum than in the remainder of the small bowel. A possible explanation of the marked ulceration in the distal ileum may be the higher bacterial content in this area. Deformity of the cecum and ascending colon is not unusual with involvement of the terminal ileum. The deformity is most often due to the intense inflammatory process in the mesentery and to fistulae arising from the terminal ileum and extending into the right side of the colon (Fig. 8B). In most of the cases, the granulomatous inflammatory process ends abruptly at the ileocecal valve.

Regional enteritis involving the terminal ileum does not always produce marked ulceration. There are many instances where the inflammatory process is minimal. In these patients the roentgen findings reveal slight rigidity, slight lack of distensibility and slight serration of the contour of the bowel.

Ileojejunitis. One hundred and two cases of ileojejunitis were studied. The distal half of jejunum and proximal half of ileum are characteristically involved (Figs. 2B, 3A, 4A, B). Skip areas are frequent. Large inflammatory polyps may be noted (Fig. 4A). Ulceration is not as marked as in the terminal ileum and fistula formation is less frequent. Because of the extent of involvement operative intervention until recently has been rare and long follow-up of the natural course of the disease has been possible. The transition from the non-stenotic to the stenotic stage could be observed and in the average case the interval was approximately four to five years.

In the last five years nine patients with extensive involvement of the small

Fig. 9B

Fig. 9A

Fig. 9A. Entire ileum involved with regional enteritis. Lesion unchanged during 8 year observation.
Fig. 9B. The mid-jejunum is involved with alternating areas of constriction and dilatation. One loop of jejunum is greatly dilated. Diagnosis: Stenosing jejunitis.

bowel had massive resections of varying segments of jejunum and ileum. Four patients are well. Two patients have electrolyte and nutritional disturbances that are difficult to control. One patient developed ulcerative colitis and two patients developed recurrent lesions in the distal bowel.

It is of interest that many of these patients with extensive involvement of the intestinal tract and despite numerous episodes of partial intestinal obstruction, can maintain an adequate nutritional status. This group of cases was reported in detail in a previous communication (3).

Jejunum. Twelve cases isolated to the jejunum were studied. In every patient there was marked stenosis. Three types of stenosis have been recognized: A single area of stenosis with proximal dilatation, a second form with two areas of narrowing and marked dilatation of the bowel between, simulating a closed loop obstruction (Fig. 9B) and a third type with multiple stenotic segments and intervening dilatation of the intestinal loops (Figs. 10A, B). The length of stenosis has been short, varying from one to three inches. Ulceration is minimal. Fistula formation is uncommon and the thickening of the mesentery is not as marked as in the remainder of the small bowel. Side-tracking operations have been successful in every case but one, again pointing to the fact that recurrences are more frequent when the operation is performed in the presence of marked ulceration and fistula formation. Isolated jejunitis in the non-stenotic stage has not been observed. These patients apparently have minimal symptoms for many years and are not investigated until partial obstruction supervenes.

Duodenum. Four cases were studied and the findings in the duodenum are essentially similar to those in the jejunum (Fig. 11A). Moderate stenosis is present and the ulcerated areas are seldom deep or marked. Two of these patients have an associated terminal ileitis.

Recurrent Ileitis. Following sidetracking operations for regional enteritis, recurrent disease in the new terminal ileum is not infrequent. Recurrent disease is most frequent during the first year. However, many years may elapse before recurrence takes place. Recurrences also appear to be more frequent in those patients where the initial lesion reveals marked ulceration with fistula formation.

In the cases where operation is performed because of stenosis, the recurrence rate appears to be less. The length of the lesion has no effect on the recurrence rate. In general, the recurrent lesion acts similarly to the original process. The colon is rarely invaded and the usual site is the new terminal ileum (Figs. 12A, B).

Healing in Regional Enteritis. While spontaneous remissions and clinical improvement following a variety of operative and conservative therapies is frequently observed, there is not a great deal of information demonstrating radiological and pathological healing. Patients who undergo re-exploration following ileocolostomy can show a remarkable degree of healing of the involved segments of bowel and mesentery. The ulcerations may disappear and the fistulae close. Demonstration of improvement without operation is rare in this series. Three cases, however, have been observed where remarkable roentgen changes indicating healing occurred (Figs. 13A, B). Despite these instances of improvement, the large majority of cases demonstrate the disease to be progressive (Figs. 4A, B).

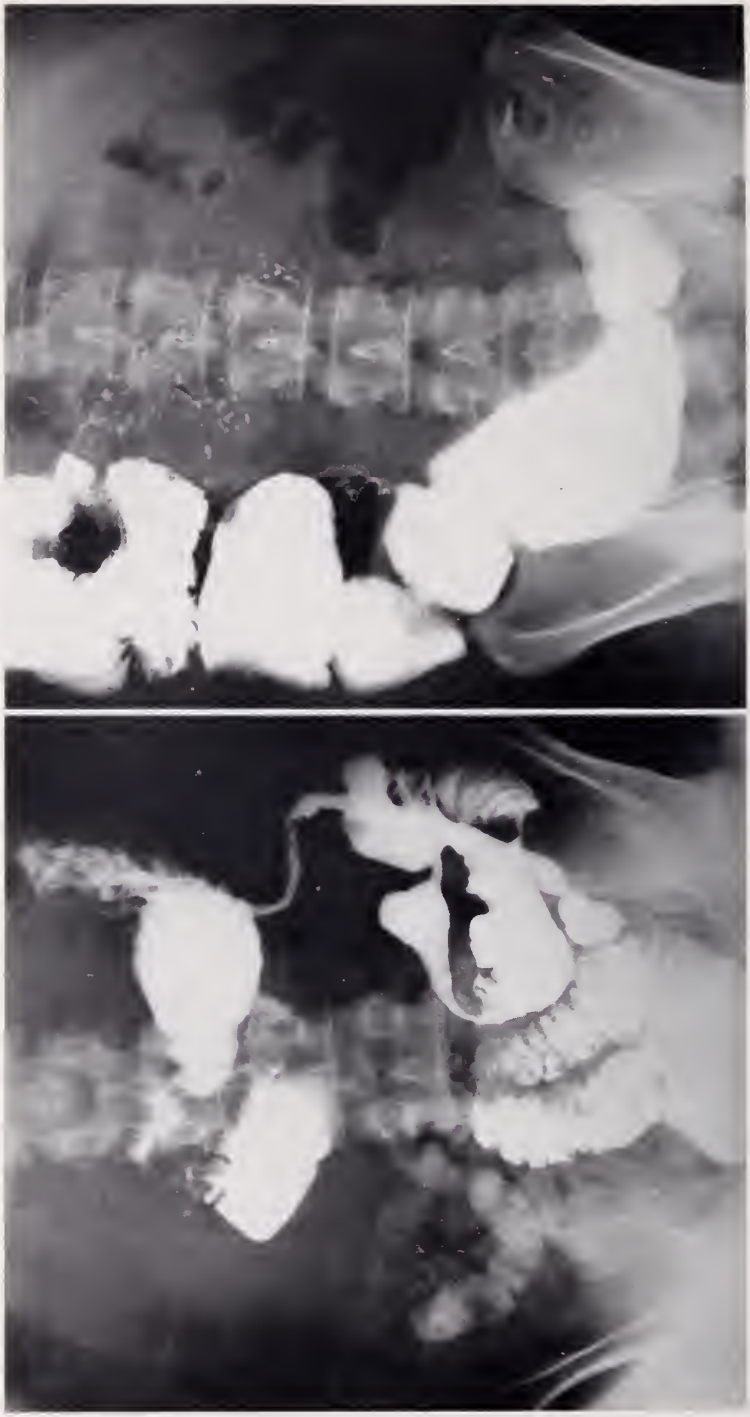

FIG. 10A

FIG. 10B

FIG. 10A. Constricted segments starting at ligament of Treitz alternating with areas of dilatation in jejunum. There is considerable dilatation of the duodenum. The mucosal pattern in constricted areas appears cast-like. Diagnosis: Stenosing jejunitis.

FIG. 10B. Greatly dilated segment of jejunum proximal to an area of narrowing in distal jejunum. Diagnosis: Stenosing jejunitis.

FIG. 11A FIG. 11B

FIG. 11A. Regional enteritis involving the second portion of the duodenum. The terminal ileum was also involved.
FIG. 11B. Regional enteritis involving the stomach. The terminal ileum was also involved.

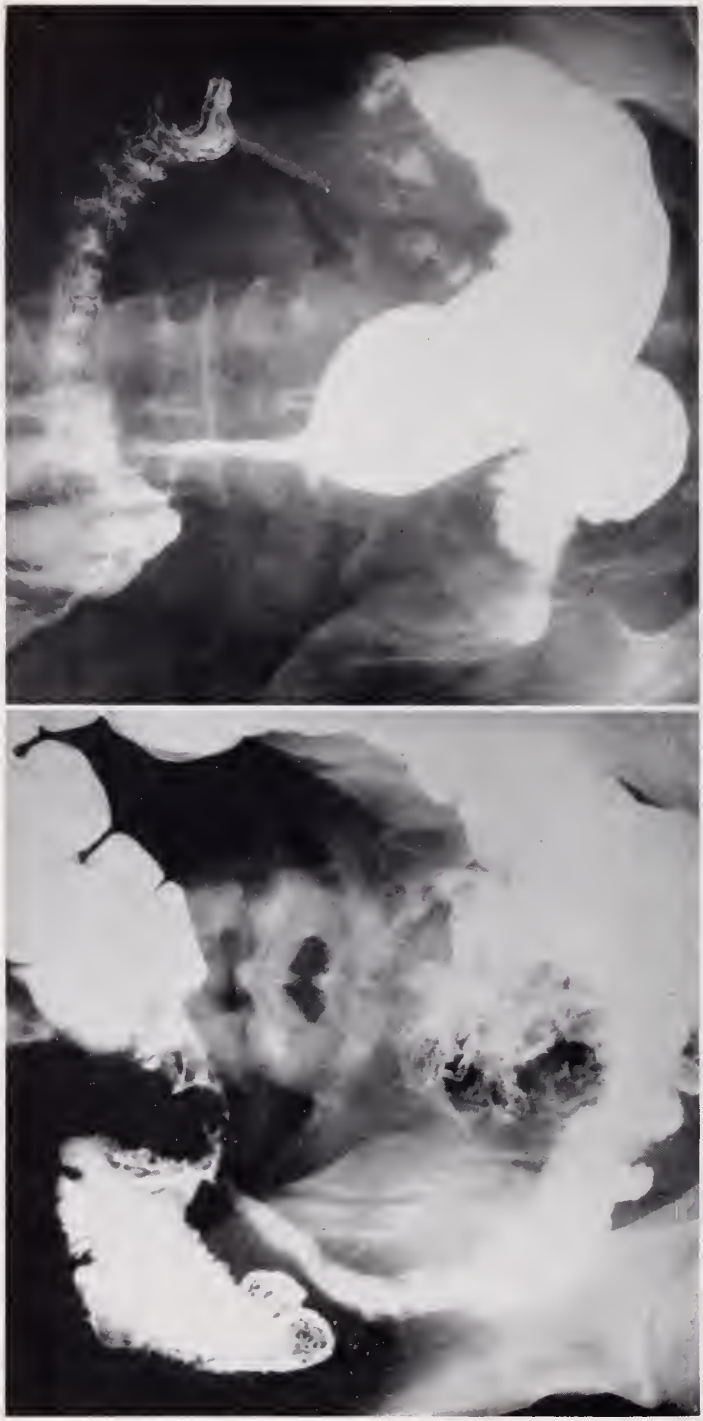

FIG. 12A

FIG. 12B

FIG. 12A. Recurrent ileitis involving the new terminal ileum. The deformity of the proximal transverse colon is due to an adhesion.
FIG. 12B. Recurrent ileitis with marked stenosis and proximal dilatation.

FIG. 13A

FIG. 13B

FIG. 13A. Terminal ileitis.
FIG. 13B. Same patient, one year later. Note marked improvement in the appearance of the terminal ileum. The findings at this time are minimal.

Many years, however, may elapse before stenosis supervenes. It should be pointed out that secondary changes may occur in patients who are clinically improved, notably stenosing lesions and permanent loss of the normal small intestinal structure. These changes are due to healing with scar formation.

ROENTGEN FINDINGS IN ILEOCOLITIS

The combination of regional enteritis and universal ulcerative colitis occurring simultaneously is uncommon. Twenty cases have been observed in this series, of combined regional enteritis and right sided (segmental, regional) ulcerative colitis in which the ileum, cecum, ascending colon and varying lengths of transverse colon have been involved. The radiological changes in the colon are those usually seen in non-specific universal ulcerative colitis and the small intestinal changes have been characteristic of regional enteritis. In four cases, the cecum and ascending colon, involved in continuity with the ileum, demonstrated alterations which were similar to the ileal changes in that stenosis was a conspicuous feature (Fig. 14A). Three of these cases showed the pathological changes of chronic ulcerative colitis, and the fourth case revealed extensive granulomatous changes in the colon. In this latter instance there is the possibility that the granulomatous process in the colon originated in the ileum.

Inflammatory disease of the ileum is frequently associated with right sided (regional, segmental) ulcerative colitis and was observed in approximately forty per cent of these cases. There has been considerable divergence of opinion regarding the interpretation of the pathological alterations in the ileum and colon in this disease. Until recently, the changes observed have been considered to be those of non-specific ulcerative colitis, with backwash involvement of the ileum; however, in the past year, several reports have been published stressing the granulomatous nature of this form of colitis (5). The radiological appearance of the involved colon is similar to that seen in non-specific universal ulcerative colitis and is usually in continuity with the lesion in the ileum. In general, the roentgen findings in the ileum simulate those in the colon but are less marked (Fig. 14B). The length of affected ileum varies from four to thirty centimeters. In most cases, the ileum is incompletely distensible and reveals alterations in mucosal pattern and contour consisting of thickening of the mucosal folds, irregularity of the contour of the bowel lumen and increased secretions. In the more severe cases, cobblestoning and finally a cast-like pattern due to further ulceration and denudation of the mucosa occurs. Occasionally narrowing of the lumen due to spasm may be so severe that it may be difficult to distinguish from the "string sign" of regional ileitis. The lack, however, of fistula formation, of proximal small intestinal dilatation, and of evidence of mesenteric thickening, are differentiating features. Whether or not the disease in the ileum is due to "backwash" or an intrinsic part of the disease process, has not been conclusively determined. The importance of demonstrating the extent of ileal involvement should be stressed in those patients in whom surgical procedures are contemplated. It is likely that some cases of recurrent disease are due to unrecognized inflammatory disease that is not resected or excluded.

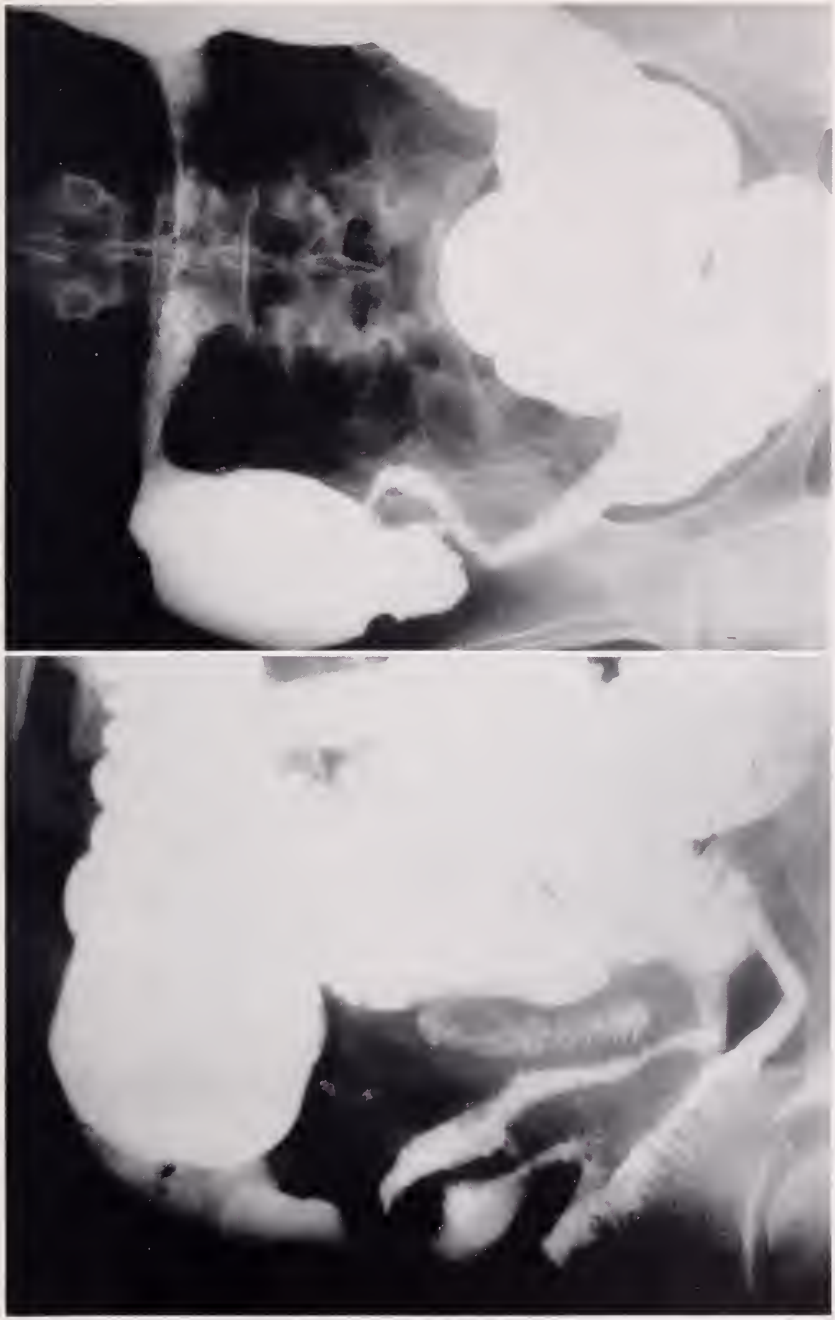

FIG. 14A

FIG. 14K

FIG. 14A. Combined disease. Terminal ileitis with right-sided ulcerative colitis. The possibility of extension of the granulomatous process from ileum into colon cannot be excluded.

FIG. 14B. Right-sided ulcerative colitis with involvement of the ileum (back-wash ileitis?).

FIG. 15A

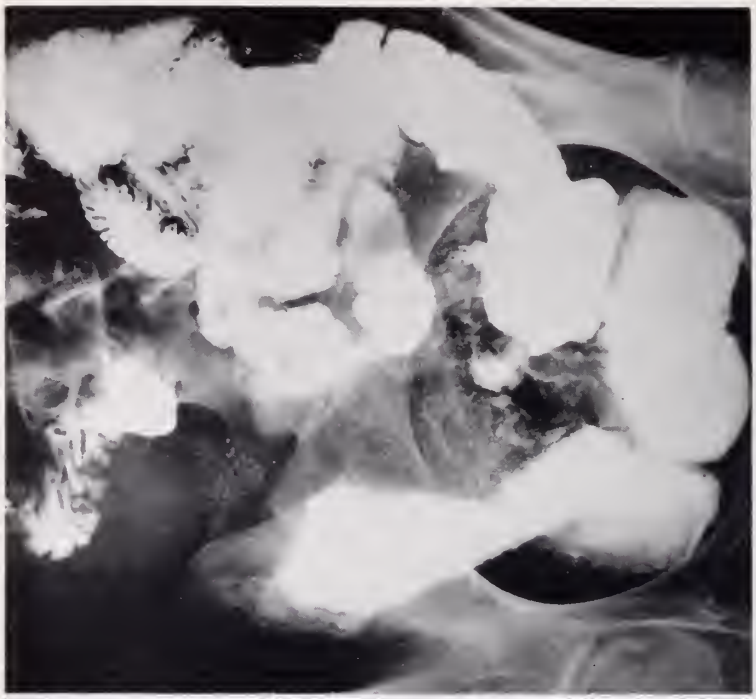

FIG. 15B

FIG. 15A. Status post-ileosigmodostomy with recurrent disease in rectum, sigmoid and adjacent ileum.
FIG. 15B. Status post-colectomy for ulcerative colitis with ileostomy. Inflammatory disease involving distal ileum (non-granulomatous).

The frequency of involvement of the distal ileum in universal non-specific ulcerative colitis in our cases is sixteen per cent. The involvement of the ileum is usually minimal in extent and severity, and has been considered to be due to "backwash" through an incompetent ileocecal valve. On occasion, such ileitis may be severe and extend backward for varying lengths in continuity with the affected colon or may occasionally exhibit skip lesions. Fistulae are uncommon. Microscopically the lesion is similar to that in the colon. The radiological appearance of the affected ileum is that of an incompletely distensible segment of bowel with varying degrees of ulceration of the mucosa. The rigidity and narrowing associated with regional ileitis is rarely observed.

Inflammatory disease of the ileum may occur after ileocolostomy for right-sided ulcerative colitis or combined disease. Recurrences have been noted despite the fact that biopsy of the anastomosed loop of ileum at the time of operation reveals no evidence of inflammatory disease. Recurrences have occurred usually first in the colon, followed by involvement of the ileum. The recurrent lesion in the ileum may or may not be granulomatous, usually depending on the initial lesion. Inflammatory disease of the ileum can also occur after terminal ileostomy for universal ulcerative colitis, even with a normal terminal ileal segment demonstrated microscopically at the time of operation. In this group of cases, stomal difficulty with partial or complete intestinal obstruction is frequently encountered. The roentgen findings in most cases, consist of thickening and blunting of the mucosal folds, some rigidity of the bowel wall and dilatation of the lumen (Fig. 15B). Excessive secretions are usually present. Resection of the affected ileum in these cases reveals a non-specific inflammatory process of the mucosa with ulceration and some fibrosis of the remaining coats of the bowel wall. The pathological changes usually associated with regional enteritis are not present. The alterations observed may be secondary to obstruction at the stoma, however, the possibility that intrinsic non-granulomatous inflammatory disease in the bowel wall may be the primary reason for the obstruction, cannot be excluded.

SUMMARY

1. The most common non-specific inflammatory lesion of the small bowel is regional enteritis.

2. Regional enteritis may affect any portion of the small bowel; however, it most commonly involves the terminal ileum. Since stenosis is such a prominent feature of this disease, the roentgen findings have been divided into the non-stenotic and stenotic stages. The roentgen changes from the earliest alterations to the late stenotic stage as well as the changes characteristic of the site of involvement are described.

3. The length of involvement is usually determined on the initial examination. Proximal and distal extension without operation is uncommon.

4. The large majority of cases demonstrate the disease to be progressive; however, many years may elapse before stenosis supervenes. Resolution without operation in regional enteritis is infrequent.

5. Regional enteritis extending into the colon is uncommon.

6. Recurrent ileitis following sidetracking procedures with and without resection of the diseased bowel occurs frequently. Again, the new terminal ileum is involved without involvement of the colon.

7. The combination of regional enteritis and right sided ulcerative colitis was seen twenty times in this series of cases. In general, the roentgen findings were characteristic of the two diseases.

8. Non-specific ulcerative colitis may involve the distal portion of ileum, and the small intestinal lesion must then be differentiated from regional enteritis.

REFERENCES

1. Sussman, M. L., and Wachtel, E.: Granulomatous Jejuno-ileitis. Radiology, 39: 48, 1942.
2. Armitage, G., and Wilson, M.: Crohn's Disease. Brit. J. Surg., 38: 182, 1950–51.
3. Marshak, R. H., Friedman, A. I., Wolf, B. S., and Crohn, B. B.: Roentgen Findings in Ileojejunitis. Gastroenterology, 19: 383, 1951.
4. Marshak, R. H., and Wolf, B. S.: Chronic Ulcerative Granulomatous Jejunitis and Ileojejunitis. Amer. J. Roentgenology, Radium Therapy and Nuclear Medicine, 70: 93, 1953.
5. Neuman, H. W., and Dockerty, M. B.: The Pathology of Regional (Segmental) Colitis. Surg., Gynec. and Obst., 99: 572, 1954.

THE SURGICAL TREATMENT OF REGIONAL ENTERITIS

LEON GINZBURG, M.D.

New York, N. Y.

The pathology of regional enteritis was originally derived from a study of specimens surgically resected at the Mount Sinai Hospital, mainly by the late Dr. A. A. Berg. These operative procedures were initially undertaken for such diverse conditions as recurrent intra-abdominal abscesses, intractable intestinal fistulae, chronic intestinal obstruction and chronic enteritis associated with intra-abdominal masses. Preoperatively these clinical manifestations had been variously attributed to such underlying causes as appendicitis, intestinal tuberculosis, lymphosarcoma, colonic neoplasm or non-specific granuloma of the bowel. Only after prolonged study did it become clear that the widely dissimilar clinical pictures noted above were really complications of a non-specific granulomatous disease involving segments of small intestine.

As knowledge of the disease became more widespread regional enteritis was more frequently suspected as the cause of obscure intra-abdominal and intestinal symptoms. Diagnostic accuracy rapidly increased, due in large part to more intensive radiological study of the small bowel. Thus it became possible in many instances to ascertain the presence of regional enteritis at relatively early stages of the disease and before the onset of complications. During this period, operation was usually undertaken as soon as the diagnosis was radiologically established, regardless of the severity of the symptoms, on the apparently logical assumption that the disease would thus be cured before complications developed. For reasons inherent in the nature of this complex disease, which will be discussed below, these hopes were not realized and numerous surgical failures were encountered. At present, 25 years later, operation is again to a considerable extent being performed for the same indications that dictated surgery before the nature of regional enteritis was understood.

A proper evaluation of the possibilities and limitations of surgical therapy in regional enteritis, requires a consideration of some of the pathological features and natural history of the disease. The visible primary lesions in the bowel are a series of mucosal ulcerations involving predominantly the mesenteric aspect of the small intestine. These ulcers may slowly penetrate or perforate through the layers of the bowel wall or remain contained within it. Two types of symptoms may develop which may be classified as the *perforative* and *nonperforative*. Although, for purposes of clarity, these will be discussed independently, it must be emphasized that both types may and do coexist.

When perforation occurs it is usually into the cellular tissue between the leaves of the mesentery, which explains why perforation into the free peritoneal cavity is so extraordinarily rare. As a rule the perforations are rapidly localized into mesenteric abscesses which may remain small, drain partially back into

From the Department of Surgery, The Mount Sinai Hospital, New York, N. Y.

the bowel or be almost completely resolved by the great resisting powers of the mesenteric peritoneum. At times the walls of these intramesenteric abscesses become adherent to adjacent viscera and spontaneously perforate into them, forming internal fistulae. In other instances, such abscesses may perforate against parietal or pelvic peritoneum forming intra-abdominal abscesses which require operative drainage. Such drainage is usually followed by the development of recurrent intractable external intestinal fistulae because of the persistence of the underlying intestinal disease. Since the actual perforation is usually small and the course of the tract tortuous, fecal discharge is usually scant; the indication for the operation, is as a rule, recurrent local infection and purulent discharge. Before the nature of the disease was understood, ill advised attempts at local repair of the internal openings or the performance of tube ileostomies, frequently resulted in profuse intestinal drainage, but this is rarely seen today.

In rare instances, instead of remaining localized, the infection may spread through the cellular tissue of the mesentery and produce retro-peritoneal infections which may mimic perirenal, supra-levator or psoas abscesses. Generally speaking, the perforative form of the disease will require operation in a high proportion of cases, in order to remove, or to promote healing of the underlying intestinal pathological process and thus remove the source of recurrent or spreading infection.

Those cases in which the ulcers do not cause perforation may be divided into the obstructive and the non-obstructive types. The obstructive variety which is by far the rarer of the two, results from actual cicatrization in the bowel wall and appears to some extent to be associated with a decrease in the activity of the ulcerative process, a most significant phenomenon from the surgical standpoint. Such stenosis may be tubular, involving a segment of bowel, or annular, involving only a few centimeters of intestine. Clinically, it presents itself as a chronic intestinal obstruction with acute exacerbations, although at times, it may suddenly manifest itself as an acute intestinal obstruction. The obstructive type of the disease will almost invariably require surgery for its relief, a simple matter if only a single segment of bowel is involved. When, however, the pathological process involves a number of widely separated segments, it may at times be necessary to limit surgery to the area of obstruction, disregarding the other areas of involvement, unless the obstructions are multiple.

The most difficult problems from the standpoint of surgical intervention are presented by the non-obstructing, non-perforating types of the disease which present the clinical picture of a chronic enteritis with acute or subacute exacerbations. Frequently, rather extensive segments of bowel are involved and "skip" lesions are common. At times the underlying pathology consists of a diffuse segmental ileojejunitis whose very extensiveness precludes the possibility of successful surgical intervention. In the literature cases of massive resection or exclusion have been reported in such instances, leaving the patient at times only a small residue of functioning small bowel. Some of these have

been regarded as successful. Imitation of such heroic procedures has apparently not been very widespread. The few cases of this type which the author has seen, have not been very satisfactory, either from the standpoint of prevention of new disease or maintenance of nutrition. Analogies drawn from results obtained by extensive resection for trauma, strangulation, or neoplasm, are probably not warranted. In such instances, the remaining small bowel is quite surely normal, whereas in diffuse ileojejunitis, such normalcy cannot be taken for granted even though there are no gross evidences of disease. It is interesting to note that even in cases of localized distal enteritis, where operation may result in great general improvement and marked relief of abdominal symptoms, moderate diarrhea may nevertheless persist indefinitely.

Thus we may say that in cases where the symptoms are purely enteric, operation should be undertaken only if the symptoms are severe, uncontrollable by any other means, and the disease involves a relatively localized continuous segment of bowel.

There are certain other features of the disease which merit discussion because of their surgical implications. One is the extent of bowel involvement. This may vary from a single lesion a few inches in length limited to the distal ileum, to four to five feet in continuity. "Skip" lesions may be closely juxtaposed or separated by many feet of normal bowel. They may be relatively few in number or be present at practically all levels of the small bowel. In general the smaller the segment of bowel involved, and the fewer the "skip" lesions, the better the prognosis.

Experience tends to show that the disease in its more diffuse forms is probably multicentric in origin from the beginning. The belief held in some quarters that extension to previously uninvolved segments is the result of spread via the lymphatics, does not seem valid. After all, spread to a point six feet from the main lesion, with apparently normal bowel in between, would be a rather capricious form of lymphatic extension. Such a hypothesis would demand a very radical resection to remove the involved mesentery with its contained nodes. Since the mesentery frequently becomes shortened as a result of chronic inflammation, large vessels at the root of the mesentery may be inadvertently secured, resulting in the necessity for very extensive bowel resection.

Another feature of regional ileitis that has been noted over the years is the tendency for typical disease to develop on the *ileal side* of an ileocolic anastomosis. Repeatedly the most proximal segments of resected specimens, or sections of bowel removed just distal to the site of an ileocolostomy, have been reported as grossly and microscopically normal. Nevertheless, in a considerable number of such cases, definite radiological evidence of disease involving the anastomosed segment of small bowel eventually became apparent. Even when the anastomosis is made as far as two feet proximal to the last visible area of disease, protection against such occurrences cannot be guaranteed. The colonic side of the anastomosis very rarely shows evidence of disease.

Poor results following surgery are, in the overwhelming number of instances, due to the appearance of new disease *at* or *proximal* to the ileocolic anastomosis.

This may follow either exclusion or resection. Originally some of these were probably due to insufficient exploration prior to the actual performance of surgery which resulted in failure to detect lesions already present. Today in the hands of experienced surgeons this rarely should be the case. In a much smaller number of cases, the development of lesions in the colon *distal* to the anastomosis are responsible for surgical failures. At times these take the form of a segmental, usually hypertrophic, colitis. However, there have been instances where the entire large bowel has become the seat of a typical diffuse ulcerative colitis. At times intractable anal fistulae develop after surgery and serve to impair the end result. Such a development, after a period of well-being following operation, may herald the appearance of new disease activity in the small bowel.

A very important factor in the surgical management of the disease is the tendency toward spontaneous remissions. This is most marked in the acute phase of the disease. Patients with acute distal ileitis who have been operated upon because of an erroneous diagnosis of acute appendicitis, have had at times permanent relief of symptoms or prolonged free intervals; some as long as ten years. Even in the more chronic forms of the disease, clinical remissions occur, although no radiological evidence of improvement may be noted.

OPERATIVE TREATMENT OF ILEITIS

Originally, localized distal ileitis was treated by ileocolic resection. Before the present era of antibiotics, blood banks, intestinal intubation and improved anesthesia, this procedure was accompanied by a mortality rate rarely under twenty per cent and at times considerably greater. In order to reduce the mortality, recourse was had to a two stage operation, the primary one consisting of an ileocolostomy with exclusion. Secondary operation revealed that recession of the active inflammatory process was present in the excluded loop in almost all cases. The routine second stage procedure was therefore abandoned and performed only on those few occasions where there was evidence that healing had *not* taken place in the excluded loop. The results following ileocolostomy with exclusion proved to be as good as that obtained following resection and were achieved with a negligible mortality. With both procedures, recurrence of symptoms proved to be due to the development of areas of previously uninvolved bowel at, or proximal to the anastomosis. Today, in the average case, both techniques can be applied with low mortalities. However, in complicated cases such as secondary bladder fistulae, multiple abdominal wall fistulae and large intra-mesenteric abscesses, the exclusion procedure is probably still the safer. Experience has shown that when a marked degree of obstruction is present, resection is to be preferred, otherwise the excluded cicatrizing area may go on to complete obstruction with accumulation of intestinal secretion proximal to it. Incidentally, obstruction rarely requires operation as an emergency. Intestinal intubation will almost invariably result in relief of the acute obstruction, making subsequent operation easier and safer. The author routinely passes a Miller-Abbott tube or one of its modifications prior to operation, in order to assure that the loop used in an ileocolostomy with exclusion is *proximal* to the disease.

At times adhesions and internal fistulae result in a confusing maze of small intestine which makes accurate delineation of the course of the small bowel difficult if exploration is commenced at the ileocecal angle. Where an intestinal tube has been passed, exploration can be started proximal to the lesion, the guide being the tip of the tube. Ileocolostomy in continuity without exclusion is mentioned only to be condemned unqualifiedly, and, in the author's opinion, should never be employed in the treatment of regional ileitis.

As has been noted above, there is considerable tendency for disease to develop in the anastomosed segment of small bowel following either resection or exclusion. For this reason a relatively wide side-to-side anastomosis appears to be preferable to one employing the end of the small intestine in the fashioning of the ileocolic stoma. Such a wide lateral anastomosis is less likely to develop mechanical obstruction should it become the seat of disease.

The results following operation are not as good as was originally believed. Recurrence, or more accurately speaking extension, is noted with greater frequency the longer the period of observation. This should, however, not blind us to the fact that even in such cases, prolonged periods of palliation occur. In some large series the incidence of unsuccessful results has been as high as sixty per cent. At the Mount Sinai Hospital it is estimated at present to be approximately twenty five per cent. However, some patients with recurrence are still much better off than they were originally. Frequently, although diarrhea continues, the patients are generally better and have gained weight and strength. Others have become free of the septic symptoms due to perforation, although they continue to have enteritic symptoms.

A special problem of management is posed by those cases of distal enteritis who are operated upon because of an erroneous diagnosis of acute appendicitis or some other acute intra-abdominal condition. A picture simulating acute peritonitis may be produced by two types of intestinal lesions. In the first, there appears to be an acute flare-up of disease in the bowel wall, and strictly limited to it. Such cases are probably best served by refraining from immediate surgery, since resolution appears to occur in a considerable number of instances. On other occasions, the acute symptoms appear to be associated with the development of acute intramesenteric inflammation associated with perforation of the bowel. In such cases ileocolostomy with exclusion may be indicated if the patient is not severely distended and not too acutely ill.

REGIONAL ENTERITIS LOCALIZED TO THE JEJUNUM

The foregoing discussion has been devoted largely to regional enteritis involving the ileum and the mixed forms involving the ileum and the jejunum. Regional *jejunitis* is a much less commonly encountered form of the disease and, in its early phases, more difficult of detection. Over the years, however, sufficient experience gradually has been accumulated to warrant certain tentative statements concerning its surgical aspects. The perforative type of the disease, with its resulting abscesses and fistulae, apparently is quite rare in regional jejunitis. This may, of course, be due to the differences in structure and physi-

ology of the upper and lower small intestine. The author is, however, inclined to attribute the great disparity in frequency of perforative complications to differences in the bacteriology of the intestinal contents at these different levels. Meleny has repeatedly emphasized that the terminal ileum contains the greatest number of living organisms of any part of the intestinal tract; greater even than the colon where some of the bacteria are dead. The more proximal the segment of small bowel, the lesser is the number of viable organisms. Absence of perforation in regional jejunitis may therefore well be due to a diminished tendency to secondary infection to complicate the primary disease. In any event, abscess and fistula formation have not served as an indication for surgical intervention in regional jejunitis in any case that the author has encountered or heard of.

On the other hand, obstruction in regional jejunitis has been the occasion for a relatively greater percentage of operations than in the more distally located forms of the disease. Furthermore, in contradistinction to distal ileitis where the obstructing lesion is practically always single, it is not uncommon for multiple segments of obstruction to be present in regional jejunitis, with segments of varying lengths of uninvolved bowel between them. Obstruction both at the distal and proximal limits of such a segment of bowel prevents free retrograde as well as forward passage of intestinal contents, a partial closed loop type of obstruction ensuing. This results in the development of truly extraordinary dilatation of the obstructed loop which may attain dimensions comparable to the stomach. The author has encountered at operation as many as three or four such enormously dilated pouches. At other times the multiple obstructions are more closely spaced with only a few inches of uninvolved bowel between them. In such instances the alternate outpouchings and constrictions produce a picture that resembles a string of pork sausages.

The type of operation employed depends on the distance of the most proximal lesion from the ligament of Treitz. When sufficient bowel is present distal to that point to permit an anastomosis, resection of the diseased segments together with the intervening obstructed bowel is indicated. When disease is limited to a single lesion resection is indicated. Because of the marked disparity in the diameter of the proximal and distal luminae, a side to side anastomosis would appear to be preferable; care being taken not to leave a blind end especially on the proximal side. The author has resected as much as six feet of jejunum with immediate good results. Most of these patients have been operated upon too recently to permit statements concerning ultimate results.

When the disease extends to or is limited to the very proximal jejunum and terminal duodenum, resection becomes a very difficult and dangerous procedure. In such cases a retrocolic duodeno-jejunostomy in continuity is indicated, if the second and third portions of the duodenum are uninvolved. The distention which develops from the long standing obstruction results in hypertrophy and dilatation of the duodenum making the procedure technically simple. When the disease extends to the more proximal duodenum, either by continuity or in the form of "skip" lesions, gastroenterostomy will furnish some relief, but it is not too satisfactory a procedure.

Operation for the non-obstructed types of regional jejunitis is not common. Single segments of disease do not give rise to marked symptoms until some degree of obstruction occurs. Furthermore, it is only in the past few years that radiological diagnosis has been possible when only the more superficial mucosal layers of the bowel are involved.

RECURRENT OR PROGRESSIVE DISEASE

As has been noted above, progression of the disease usually involves the ileal side of an entero-colostomy, but it is found sometimes proximal to that point. Diagnosis of a recurrence frequently is made by a barium enema or meal administered for follow-up purposes. The establishment of a diagnosis in this manner should not be regarded as an indication for further surgery. As a matter of fact, a great many of such patients with easily identifiable disease have relatively few symptoms and maintain a relative state of well-being. As in primary cases, operation will have to be done if obstructive or perforative complications occur. In the absence of such manifestations, only those cases with severe intractable symptoms and wth evidence of continued infection or profound anemia should be re-operated upon. Secondary operation varies as to whether an ileocolic resection or an ileo-colostomy with exclusion were performed primarily. If a previous resection has been done, it is probably just as simple to resect a further small segment of colon and stoma with diseased ileum and then to restore continuity by anastomosis. If the primary operation was an ileo-colostomy, there would ordinarily not be much point in resecting a number of feet of small intestine and a portion of the colon proximal and distal to the anastomosis. Under such circumstances, it is wisest to do a secondary exclusion dividing the ileum proximal to the diseased segment and making a new entero-colostomy more distally in the colon. Of course, if disease is found in the previously excluded loops, this will have to be resected.

ILEOCOLITIS AND POSTOPERATIVE COLITIS

As is pointed out in another article in this issue of the Journal of the Mount Sinai Hospital, there are many forms of such combined disease. No one rule can be laid down that would cover the treatment of such variegated clinical manifestations. Whenever possible, if both diseased ileum and colon are present, it is wisest to resect the terminal ileum and extend the resection in the colon to a point distal to the area of colonic disease. Continuity should be re-established by an ileocolostomy. In those cases where skip areas of localized colitis are associated with regional ileitis, it is probably also wise to resect in continuity from normal ileum to normal distal colon, rather than to attempt to do a segmental colon resection. The latter may lead to serious complications because of failure of healing of colon anastomoses.

SUMMARY

1. Regional enteritis should not be operated upon *ipso facto.*
2. In regional ileitis obstruction and the various complications due to perforation will require operation.

3. In the active enteric phase of the disease, operation should be performed only for localized disease which is severe and intractable or associated with fever and progressive loss of weight and anemia.

4. Massive resection for multiple lesions in ileojejunitis is still *sub judice.*

5. Resection or enterocolostomy with exclusion are equally effective in controlling disease already present.

6. Recurrence of symptoms after either operation is usually due to the appearance of disease on the ileal side of the ileocolic anastomosis.

7. In regional jejunitis obstruction, frequently multiple in character, is the most common indication for operation; usually resection.

8. Perforative complications in jejunitis are extremely rare.

9. The early inflammatory phase in regional jejunitis rarely requires operation.

10. Recurrent or progressive disease in the ileum should be operated only if perforation, hemorrhage, fever, or obstructive signs develop.

11. X-ray evidence of disease at the stoma in itself is not an indication for operation. Such findings may coexist with minimal symptoms.

12. No definite rule as to procedure can be given in either primary ileocolitis or any form of colitis following operation for regional enteritis.

13. Combined resections for regional ileitis and colitis should consist of ileocolic resection with ileocolic anastomosis distal to the colonic lesion.

14. Segmental resection of the colon for disease associated with regional enteritis is not a good procedure.

PROBLEMS OF REGIONAL ENTERITIS

HENRY D. JANOWITZ, M.D.

New York, N. Y.

This symposium indicates that a period in the study of this pathologic and clinical entity is drawing to a close. It is appropriate therefore, to assess our experience with it over a quarter of a century. As the complexity of the pathologic and clinical ramifications of the disease have become apparent, the full variety of compelling problems still to be faced has also become equally clear.

Summaries and full accounts of current information concerning regional ileitis appear frequently. The detailed statistical survey of the experiences at the Mayo Clinic by Van Patter and his coworkers (1) may be supplemented by the more impressionistic reflections of Crohn and the author (2) on the disease twenty years after its segregation. It is not the purpose of the present paper to repeat that material but rather to indicate the current problems.

PROBLEMS OF TERMINOLOGY

Nomenclature is vexing only in areas of inadequate knowledge. For that reason the problem of terminology in the entire field of inflammatory disease of the large and small intestines remains a thorny one. Presented originally under the term *terminal ileitis* (because the 14 primary cases were so localized) *regional ileitis* was soon substituted at the perspicacious suggestion of Bargen. With the prompt recognition of more widespread small bowel involvement, the use of the term *regional enteritis* for this form of chronic inflammatory lesions of the small bowel by Brown, Bargen, and Weber (3) represented a distinct advance in appropriate naming. *Chronic cicatrizing enteritis* emphasizes only one feature of the pathologic anatomy, while *chronic ulcerative enteritis* stresses a relatively superficial aspect of its pathology. *Segmental enteritis* has much to support it, but has the defect of confusing, or perhaps the advantage of identifying it with segmental or regional colitis.

Ileocolitis was coined to denote the increasing awareness that inflammatory disease of the colon and ileum can coexist. When the combination of regional ileitis and chronic ulcerative colitis was recognized, the term *combined disease* for this clear-cut combination appeared somewhat surreptitiously in the literature. And more recently the term *nonspecific enterocolitis* has been proposed for still another and subtle variant of combined inflammatory disease of the small and large bowel (4). The term *coloileitis* might be reserved for that involvement of the terminal ileum which so frequently accompanies chronic ulcerative colitis, and which is usually referred to as *backwash ileitis*.

It seems to this reviewer that no firm committments need be made prematurely, but that for convenience and in order to indicate the areas of agreement the term

From the Department of Medicine and the Gastro-Intestinal Clinic, The Mount Sinai Hospital, New York, N. Y.

regional enteritis is the most satisfactory one for indicating the general nature of the granulomatous inflammatory disease of the small bowel this symposium is devoted to. *Regional ileitis*, *jejunitis*, or *ileojejunitis* are appropriate subgroups to indicate more clearly the areas of involvement. *Combined disease* clearly refers to the combination of ulcerative colitis and regional enteritis. *Regional enterocolitis* or *ileocolitis* should be reserved for granulamatous disease of the small and large bowel (if such an entity does in fact exist).

PROBLEMS OF ETIOLOGY AND PATHOGENESIS

The air of unreality that surrounds the preceding account of present day nomenclature clearly arises from our ignorance of fundamental mechanisms of disease production in this area, and is reminiscent of the controversies that surrounded the discussion of pulmonary fibrosis prior to the discovery of the many etiological agents capable of eliciting that pathological reaction in the lung, or of those unknown agents capable of producing "cirrhosis" of the liver.

Although non-caseating tubercle-like granulomata are characteristic if not pathognomonic histological features of regional enteritis, the attempts to identify this disease with the known agents of other granulomata appear without avail. Known organisms including the tubercle bacillus and fungi have been carefully ruled out. The clinical feature of regional enteritis and sarcoidosis are quite different. The concept of a sensitization phenomenon being involved is so general and nonspecific as to allow of its neither being ruled in or out at present. Similarly, the identification of regional enteritis with ulcerative colitis, and the ascribing of a psychosomatic origin for both seems a premature way of disposing of the problem of etiology of this unknown disease.

To be more profitable, speculations regarding the pathogenesis of the disease process should be rooted in the known facts of the natural history of the disease. Three such facts are paramount: (a) The vast majority of patients have the initial lesion in the terminal ileum (up to 80 per cent in some series); (b) diversion of the fecal stream by short circuiting operations leads in the majority of instances to regression of the process in the excluded areas of the intestine; and (c) recurrent lesions in the overwhelming number of cases are again localized in the new "terminal" ileum. These facts suggest that the noxious agent is present in the intestinal stream. They also suggest that the agent or agents may be water-soluble, may be concentrated as the intestinal contents are propelled through the small bowel, and may become absorbed by the lymphatics of the ileum which are so rich in the region of the ileocecal valve. Here they may set up their characteristic proliferative sclerosing endolymphatic reaction.

Significant, although limited experimental attempts to reproduce the disease have indicated that lesions simulating regional enteritis can be produced by lymphatic blockage (5). In connection with the hypothesis proposed above, the studies of Chess and co-workers (6) are of great interest. These authors have produced convincing intestinal and regional lymph node lesions by feeding animals finely divided silicates in large doses. These experiments indicate that materials present in the intestinal stream may enter the ileal lymphatics and

set up productive inflammatory reactions. To this may be added the evidence regarding the tissue reaction to products of lipolysis, especially stressed by Cooke and others. The time appears to be drawing close for a renewed experimental attack on the pathogenesis of the disease in terms of an endogenous intestinal reaction.

IMPLICATIONS OF PATHOLOGY

The details of the histopathology of regional enteritis are the subject of another communication in this series of papers and need not be discussed at this point. However, certain implications from the author's point of view deserve comment. Just as the attempt to read etiological significance into the inflammatory granulomatous process has not yielded significant results, so also are there limitations to drawing etiological conclusions from the fact that regional enteritis is pathologically distinct from other inflammatory diseases of the small and large bowel. The cumulative weight of pathologists' study continues to justify the original demarcation of regional ileitis as a "pathologic" entity, and its separation from chronic ulcerative colitis on pathologic grounds continues to be justified. This does not permit, however, any very firm etiological deductions.

Particularly confusing is the problem, again touched upon elsewhere, of how frequently granulomatous involvement of the colon coexists with granulomatous enteritis. In the author's experience this is relatively rare, yet a high incidence of granulomatous reaction of the colon has been reported in other series of cases. Certainly, the ability of the colon to react by granulomatous inflammation cannot be gainsaid. The characteristic difference between ulcerative colitis and granulomatous ileitis cannot be ascribed to this presumed inability of the colon to so react.

The tendency toward repair in the histopathology manifested by a fibrotic reaction should be commented on; a tendency seen most clearly in the bypassed bowel, and in the stenosis which occurs in ileitis, diffuse ileojejunitis, and in jejunitis.

THE CLINICAL PROBLEM

The clinical features which suggest the possibility of granulomatous enteritis have become increasingly better known since the original syndrome was described. The classic features include low grade fever, abdominal pain, frequently, although not invariably, the presence of mild diarrhea, secondary anemia, and progressive weight loss, together with the development of a mass in the right lower quadrant. The development of a fistula between loops of involved gut and the formation of rectal fistulae round out the typical case. The most significant addition to our clinical description of the illness has been the progressive realization that the granulomatous process may involve every segment of the small bowel and even the duodenum and stomach on rare occasions.

Large gaps exist in our knowledge of the natural history of the disease, especially of the untreated disease. Although world-wide in distribution, and occurring at all ages with no clear-cut sex difference, the actual incidence of the

disease is not known. Asymptomatic carriers certainly exist since on rare occasion ileal disease has been discovered when a barium enema was done in the course of a routine X-ray study. The relation of the acute variety of terminal ileitis seen at times in children to the chronic cicatrizing form is also unknown.

In regard to the problem of localization, there still remains the perplexing question of whether the disease is diffuse at first and localizes only later. The hypothesis of widespread initial lesions does not fit the known clinical facts but might explain the high incidence of recurrence following operation even though biopsy at the site of resection or by-pass may be entirely negative.

There is some evidence upon which to answer the question of spontaneous extension or regression of the chronic disease. Extension proximally in the small intestine following clinical diagnosis and radiographical delimitation must occur with extreme rarity in the absence of operative intervention judging from the author's experience. Extension into the colon does occur by way of fistulae and in rare instances after anastomotic operations. The question of spontaneous healing presents a greater problem. The tendency for the acute form in children to heal in most instances has indeed thrown some doubt on the identity of this variety with the chronic form (7). By and large spontaneous healing appears to be the exception. Clinical remissions, when they occur, are not accompanied by radiographic evidence of subsidence of the pathologic process. Yet the potentiality of healing is shown in the regression of lesions of the by-passed intestine. Indeed in ileojejunitis or jejunitis the development of intestinal obstruction secondary to fibrotic stenosis is typical.

From the diagnostic point of view, once the disease is suspected on clinical grounds, radiography, in most instances, substantiates the diagnosis. The roentgenographic findings are discussed in full detail elsewhere in this issue. The only comment that need be made here is that with the increasing awareness of regional enteritis, there has been a tendency recently towards meagerness of differential diagnosis. Not all small bowel disease is regional ileitis. The differential diagnosis possibilities should include ileocecal tuberculosis, carcinoid tumors, endometrial implants, lymphosarcoma, intestinal lipogranulomatosis (Whipple's disease) and (milk) allergy.

In assessing the pathophysiology of this disease, it is striking that in the localized form whether in the jejunum or in the more frequent ileal location, the amount of small bowel dysfunction is slight. In the diffuse form with widespread involvement of the absorbing surface of the small intestine, however, many of the clinical manifestations of the malabsorption or sprue syndrome may be present on occasion. Anemia of the megaloblastic type, especially when duodenum and jejunum are involved, hypoproteinemia with edema, hypoprothrombinemia, profuse diarrhea, steatorrhea, electrolyte alterations including clinically overt tetany may all be marked and may mimic ideopathic sprue closely.

The relations between regional enteritis and ulcerative colitis have been touched upon already in this discussion, but deserve some further comment. Leaving aside the "backwash" superficial ulceration of the ileum in chronic ulcerative colitis, and the rare instance of granulomatous disease of the ileum

which extends into the large bowel, true *combined disease* as defined above coexists in about 5 per cent of patients with regional enteritis. The pathological differences between these two illnesses and the characteristic history of the typical forms of each prevent any easy identification of the two diseases. Yet their coexistence cannot easily be dismissed as coincidental, and especially the occasional development of small bowel disease after ileostomy for chronic ulcerative colitis. It seems wise at present not to prejudge the issue by insisting on the unity of all inflammatory diseases of the small and large bowel.

THE THERAPEUTIC PROBLEM

In the absence of specific therapy for regional enteritis, the therapeutic approach to the disease was surgically oriented from the beginning. "The restitution to complete health in thirteen out of fourteen cases as the result of the radical resection of the pathologic process or a short circuiting operation speaks vehemently in favor of the surgical methods as the logical successful therapeutic procedure", so reads the original report (8). With the increasing recognition that the rate of recurrence is a function of the length of follow up, and with increasing numbers of recurrences, the approach to therapy is now in a disillusioned phase.

We are sorely lacking in convincing studies on the natural history of the non-surgically treated patient followed for a sufficiently long period of time. Until this information is assembled, we will not be in a position to evaluate accurately the contribution that surgical therapies are capable of making. The one wholesome feature of the swing away from surgery is that we may be able now to secure such information.

The available medical therapeutic measures are strictly supportive. Maintenance of nutrition, or correction of nutritional deficiencies, control of pain and diarrhea, and psychiatric assistance all must be employed. Sulfonamides of the succinylsulfathiazole, phthalylsulfathizole group have a place, perhaps in the control of secondary bacterial invaders, and are useful in handling some external fistulae, especially the perirectal ones. The effect of cortisone and corticotropin in localized regional ileitis has been on the whole disappointing, although long term studies are not yet available. In the patients with absorption difficulties due to widespread involvement, however, these compounds and especially hydrocortisone have a useful adjuvant role. Systematic use of a long term sanatorium regimen of rest and support, similar to the tuberculosis programs of the pre-chemotherapeutic era have been advocated, certainly deserve a trial, but have not been reported.

The surgical aspects of this problem are authoritatively discussed in this symposium, here the problems from the gastroenterologists' point of view are presented. The detection of a lesion roentgenographically is in itself no indication for surgery; however, certain complications are clear indications. These include cicatrizing stenosis with obstruction, mass formation and fistulization of the small bowel either to other loops, bladder, or vagina. In view of the tendency for recurrence, the feeling has been gradually crystallizing that operation should

not be performed when the lesion is not clearly delineated or defined, but should rather be deferred until the pathological process appears to be "burnt out" or approaching the fibrotic sclerotic stage, although it is admittedly difficult to make this decision from clinical or roentgenographic criteria. On the other hand, continued activity of the disease, together with progressive clinical deterioration of the patient despite supportive measures, may precipitate the need for surgical intervention.

The massive extirpation of diffuse disease constitutes a continuing experiment the final results of which are still to be evaluated, and, in this reviewer's opinion, remains as a trial to be conducted only by those prepared to study completely and follow carefully this therapeutic experiment.

Finally, the palliative aspects of surgery must also be considered in their proper perspective. An operation which is followed by recurrence in some cases only after five, ten, or even nineteen years has a place in the management of a baffling clinical problem.

REFERENCES

1. Van Patter, W. N., Bargen, J. A., Dockerty, M. B., Feldman, W. H., Mayo, C. W., and Waugh, J. H.: Regional Enteritis. Gastroenterology, 26: 347, 1954.
2. Crohn, B. B., and Janowitz, H. D.: Reflections on Regional Ileitis, Twenty Years Later. J.A.M.A., 156: 1221, 1954.
3. Brown, P. W., Bargen, J. A., and Weber, H. M.: Chronic Inflammatory Lesions of the Small Intestine (Regional Enteritis). Am. J. Digest. Dis. and Nutr., 1: 426, 1934.
4. Cooke, W. T., and Brooke, B. N.: Nonspecific Enterocolitis. Quart. J. Med., 24: 1, 1955.
5. Reichert, F. L., and Mathes, M. E.: Experimental Lymphedema of the Intestinal Tract and its Relation to Regional Cicatrizing Enteritis. Ann. Surg., 104: 601, 1936.
6. Chess, S., Chess, D., Olander, G., Benner, W., and Cole, W. Hr: Production of Chronic Enteritis and Other Systemic Lesions by Ingestion of Finely Divided Foreign Materials. Surgery, 27: 221, 1950.
7. Storrs, R. C., and Hoekelman, R. A.: Acute Regional Enteritis in Children. New Eng. J. Med., 248: 321, 1953.
8. Crohn, B. B., Ginzburg, L., and Oppenheimer, G. D.: Regional Ileitis: A Pathologic and Clinical Entity. J.A.M.A., 99: 1323, 1932.

PEDIATRIC PROFILES*

Henry Koplik

Almost every physician, the world over, is familiar with "Koplik's spots" as a sign of incipient measles, yet very few know who Henry Koplik was, when he lived, and what he stood for in the history of pediatrics. No American active during the last decade of the nineteenth century and the early years of the twentieth century did more for the advancement of pediatrics in the United States than Henry Koplik. Though his name will be carried down the years by



Henry Koplik
(1858–1927)

his discovery of the pathognomonic sign of measles, his fame will rest not only on that discovery but on two other very important contributions—his founding the first baby health station and his emphasis on the laboratory in connection with clinical medicine. That his importance was recognized during his lifetime is well illustrated by the estimates of two of his contemporaries. Dr. J. J. Walsh opens his biographical sketch of Koplik in *The History of Medicine in New York*, published in 1919, as follows: "Henry Koplik, M.D., eminent New York phy-

* Reprinted from The Journal of Pediatrics, *46:* 119, 1955.

sician, has had an enviable career. As a foremost specialist in diseases of children in this country, and former president of the American Pediatric Society, Dr. Koplik enjoys a reputation not only co-extensive with this country, but one that extends to Europe as well. As an exponent of Preventive Medicine, as discoverer of what has since been known as the 'Koplik's Spots,' and as the founder in America of the first milk depots known to the profession as the 'Gouttes de Lait,' out of which grew the universal idea of milk depots now in existence throughout the world, and as head of the Good Samaritan Dispensary for fifteen years, the largest pediatric clinic ever conducted in America, Dr. Koplik has had a career not easily paralleled in the lives of contemporary medical men, not only for its broadly beneficent and humane character, but as well for the distinctions attained in his chosen field of practice." In an obituary, written in 1927 for the New York Academy of Medicine, Dr. Emanuel Libman wrote: "Personally Dr. Koplik was a man of distinguished appearance and dignified bearing. Whenever he discussed a presentation at a meeting, all eyes were at once turned to him, and all realized that they would hear a carefully worded and authoritatively expressed statement, based upon his own experience and his own views. In more intimate contacts one was impressed and attracted by his sparkling mind, his great knowledge and his goodly store of anecdotes and humorous stories. He was himself the kind of man concerning whom numerous anecdotes spring up. Some of these will no doubt be preserved."

Henry Koplik was born in New York City on October 28, 1858. He received the degree of A.B. from the College of the City of New York and M.D. from the College of Physicians and Surgeons of Columbia University in 1881 where he won the Harsen Prize awarded only to students of exceptional ability. Following an internship at Bellevue Hospital in New York he spent several years studying abroad in Berlin, Vienna, and Prague. This was long before Abraham Flexner made his famous trip to Europe, whence he brought back so many ideas that helped to revolutionize medical education in the United States. Koplik, too, was greatly influenced by his European training and later in life made numerous trips abroad during the summer months, visiting hospitals and clinics and exchanging views with the many great European pediatricians of that era, bringing back to America many of the innovations he had seen abroad.

On returning from his student years to New York in 1886 he started to practice and the following year was appointed attending physician to the Good Samaritan Dispensary, located in the lower east side of Manhattan, one of the most crowded slum districts of the city. Here he built up an extremely large outpatient clinic which became famous with its wealth of material as a model for the dispensary care of infants and children. With the financial help of prominent philanthropists, he started there what we now know as a baby health station. Not only were the infants examined, both the well and the sick, but proper formulas were prescribed and distributed to the mothers. It is interesting to read in the newspapers of the day and see what great publicity this novel form of prophylactic medicine received. When a drive was on for more funds for this rapidly growing institution, the Sunday edition of the *New York World*

in June, 1899, devoted almost an entire page to pictures and descriptions of the clinic. The accompanying table, quoted from a leaflet distributed to obtain financial aid, is interesting to show the rapidity with which the new idea took hold and how the clinic grew.

Record of first ten years' work of milk depot of Good Samaritan Dispensary

Year	Bottles Supplied	Children Supplied
1889	7,000	137
1891	44,111	574
1892	57,371	700
1893	70,068	976
1894	70,705	720
1895	75,550	932
1896	96,311	766
1897	155,989	1,064
1898	298,674	1,204

From six to eight bottles of milk a day were dispensed per infant, depending on the doctor's orders. Six bottles sold for eight cents; the deposit on the bottle was three cents and on the rubber stopper was one cent. About 200 free bottles were dispensed daily and on Saturdays the number ran as high as 2,000. When one considers that the milk had to be kept refrigerated, that the formulas had to be prepared, that the bottles had to be cleaned and sterilized, and that careful records had to be kept of the financial side of the enterprise as well as of the medical condition of the child, one stands in awe of the man who could successfully manage such an undertaking. He must have been a genius at organization. Koplik has told the story of the foundation of this clinic in an article published in 1914 under the title "The History of the First Milk Depot or Gouttes de Lait With Consultations in America" (J. A. M. A. **50:** 1574, 1914).

It was also at the Good Samaritan Dispensary that the enanthem on the buccal mucosa of measles cases was discovered. The description of the pathognomonic "spots" first appeared in the *Archives of Pediatrics* published in New York in 1896 in an article entitled "The Diagnosis of the Invasion of Measles. From a Study of the Exanthem as it Appears on the Buccal Membrane." Herein a long and careful description of the sign and its great significance as a diagnostic aid was clearly set forth, but curiously enough, the medical profession did not seem to realize its importance. A second article in the *Medical Record* in 1898 and then a third one in the *Medical News* in 1899 finally aroused physicians; publications here and abroad corroborated Koplik's findings and confirmed the great value and significance of his discovery. Under the title "Some Pediatric Eponyms. III. Koplik's Spots," W. R. Bett (Brit. J. Child. Dis. **28:** 127, 1931) gives an interesting account of this struggle for recognition.

Koplik's articles on his sign exemplify one of his most striking character traits, namely, his indomitable perseverance and his forcible will to carry through any undertaking he had once begun, regardless of whatever obstacles and difficulties might stand in his way.

Mrs. Bierman, Dr. Koplik's daughter, tells an amusing story of how, when her mother took her and her two brothers to Europe on a German steamer, one of the boys took sick and she asked the ship's doctor to have a look at him. This very pompous young physician demonstrated to her some lesions in the boy's mouth which he told her were "Kopliksche Flecken," a recently discovered sign of measles. There was considerable excitement when the doctor was told that the boy was the son of the discoverer.

Koplik's interest in the laboratory as an aid in the practice of pediatrics was probably acquired in Europe, for early in his career in New York he established a laboratory at his own expense in the Good Samaritan Dispensary. Here he not only did clinical pathology for the sick patients but also carried on original bacteriological research. Among one of his findings was that of a small bacillus obtained from the sputum of whooping cough cases and grown on media enriched with human blood. This he believed was the etiological agent of pertussis and was published as such in 1892. Referring to this, Emanuel Libman, himself an expert bacteriologist, says, "At that time differential immunologic methods were not available, and for that reason a strict comparison with the organism of Bordet-Gengou cannot now be drawn. The bacillus of Koplik seems, however, to conform to that of Bordet and Gengou." In the days when this work was done, there were not many children's dispensaries in America where clinic and laboratory worked so closely hand in hand. Libman also says, "Because of his [Koplik's] interest in scientific pursuits, he early attracted the attention, admiration and support of such men as Adami, Jacobi, Osler and Welch." In the early part of his career he was very close to Jacobi. In fact, the latter entrusted to him much of the preparatory work for his classical monograph on diseases of the thymus.

As a clinician Koplik was a real master. He could size up a case in a few minutes, and when he had finished his physical examination, there was rarely anything that had escaped his acute senses. At a time when there was no x-ray to control clinical findings, the physician was much more dependent on auscultation and percussion in making diagnoses of intrathoracic conditions than he is today and he therefore became much more expert in the use of these diagnostic means. His delicate percussion of a young infant's chest was performed with the artistry of a pianist, and I recall his particular skill in diagnosing in the very young the presence of empyema, then a very common disease.

After some years as adjunct visiting physician to the children's wards of the Mount Sinai Hospital, Koplik was appointed attending pediatrician, a position he held for twenty-five years. His conducting of this service, where as intern and later as house physician I first had contact with him, gave one an excellent insight into his character and habits. In the hospital Dr. Koplik was a medical czar. His will was law and he brooked no interference. The men on the house staff were literally afraid of him, yet they respected his medical ability and his knowledge to such an extent that they welcomed the chance to work under him. Rounds were conducted with the greatest formality and woe to him who appeared late. He himself arrived at the hospital every day promptly at 8:30 in

the morning, wearing a frock coat and a high silk hat. Koplik was a handsome man with pointed beard, a moustache, and bushy eyebrows overhanging a pair of flashing dark eyes. In what looked like holiday attire he made quite an impression and inspired people with real awe. After donning a white coat, he would appear on the wards where nurses and doctors immediately rose and rounds proceeded with military-like precision. I cannot recall his praising anyone on his staff but he did not hesitate to criticize and "call us down" if we were lax in any procedure or made some error in the handling of a case. He could make you feel very, very small. On one occasion he stopped at an empty bed and asked where the baby was who had been in the bed on the previous day. The child had been moribund with a hopeless disease and the house physician reported that he had died during the night, to which Koplik replied, "Another death to your credit, Doctor," and moved on to the next bed.

The position of intern on the pediatric wards was an arduous one, for fifty years ago there were no technicians and all the clinical work was done by the interns. We had many cases of typhoid fever on the ward and Dr. Koplik made it a rule that during the height of the disease each child was required to have a blood count daily—quite a chore, which some of us performed by coming to the wards early and getting the counts done before breakfast. Our chief was meticulous about ward cross-infections and separated the beds of the typhoid cases from the remainder of the patients by movable stanchions connected by cords, so that their beds were roped off. In this way doctors and nurses were reminded to take the necessary precautions against spreading the disease.

How strict and rigid the ward routine was is well illustrated by the following incident: I was in charge of one of the pediatric dispensaries and one afternoon had a case admitted from the clinic to the ward for diagnosis. Next morning in the enthusiasm of youth, I went to the ward where I had recently been house physician, pricked the boy's finger, and took a blood spread to study at my leisure in my office. In some way Dr. Koplik was informed of this infraction of the rules and I was reprimanded by his saying to me in no uncertain terms, "I want you to know, young man, that every drop of blood in this ward belongs to *me*."

As is so often the case under such circumstances, there is bound to be a reaction at some time, when discipline breaks down and everybody has a good laugh. We had on the ward an infant suffering from tetanus who showed a typical "risus sardonicus." The child died and on the chart Dr. Koplik found a nurse's final note which even he could not take seriously: "The baby smiled and went to Heaven." As I recall, no one was reprimanded.

On his trips abroad during the summer Koplik investigated and reported in great detail the various measures used to prevent ward infections. New type of ward construction for children's hospitals in use in France and Germany that he approved of were introduced into America. He laid particular stress on the importance not only of the physical setup of the wards (cubicles, isolation rooms, etc.), but also of the necessity of having adequate and well-trained personnel. He constantly impressed his staff with the fact that every child must have a

most thorough physical examination *before* he was admitted to the ward. Fifty years ago gonorrheal vaginitis in infants and young girls was a common, highly contagious disease which tended to very rapid spread through the hospital. Koplik laid down the most rigid rules and regulations for its control and as a result was able to keep his wards fairly free from this disease.

Besides his papers on ward hygiene and disease control, Koplik's clinical publications covered a wide range of subjects—poliomyelitis, cerebrospinal meningitis, the etiology of empyema, sporadic cretinism, streptococcus osteomyelitis, mongolism, pylorospasm and congenital pyloric stenosis, chronic arthritis, pneumonia and typhoid fever. Libman refers especially to the great value of Koplik's studies and publications on diphtheria in which he emphasized the importance of the differential diagnosis of the cases resembling simple sore throats and their rapid bacteriological diagnosis. In 1902 he published a book, *Diseases of Infancy and Childhood*, of which he was very proud. It went through four editions and he spent a great deal of time and effort in keeping it up to date, spending many evenings in collecting new items and subjects to be incorporated into the next editions.

As the result of his prominence in New York medicine, his practice grew by leaps and bounds and he was busy every day, seeing large numbers of children in consultation both in his office and in the city and its environs. He lived and practiced in the same house, a brownstone high-stoop house on east Sixty-second Street, where on a Saturady he commonly saw forty to fifty patients. A day when he only saw fifteen to twenty patients was considered a "bad day." He never had a physician to help him in his office. On a day when the office was busy, it was not uncommon to see women sitting on the steps of the house, some of them nursing their babies, the waiting room being too small for the crowd. Taxi drivers anxious to pick up fares parked in front of the house like at a hack stand.

I had an amusing personal experience which perhaps partly helps to explain this huge practice. A woman, who I thought was a loyal patient of mine, told me that she had taken her son to Dr. Koplik, although the child was quite well. Surprised at this, I inquired why she had done this, and was told that the grandmother believed "that every New York child should be seen by Dr. Koplik at least once."

As a consultant, Koplik was very helpful to the physician. By his looks and bearing and by his authoritative way of speaking and discussing the case he inspired real confidence in the patient's family. Occasionally he would inject a note of sardonic humor as in an instance when I called him in consultation to see a very sick pneumonia patient. At the bedside he inquired whether I was giving digitalis, and when I answered in the affirmative, he asked what brand I was using. It told him that I was giving Squibb's digitalis, whereupon he said, "You should use Upsher-Smith's." When I replied that I had never heard of that brand, he answered, seemingly quite seriously, "It is only used in consultations." One never quite knew whether he was laughing with you or at you.

With the onus of his writing and lecturing, his hospital work, and his huge

practice, Koplik had little time for reacreation or family life. He had no hobbies at all and devoted his entire energy to his medical life. He was deeply devoted to his wife, who was a great help to him and was always at his beck and call. Their social life was very limited; they had only an occasional dinner party and rarely went to theaters or concerts. Of their children only one now survives, a daughter, Mrs. Rosalie Bierman, of Norwalk, Connecticut. The younger son died at college at the age of seventeen, after his father's death. The older son, Lewis, became a physician and had an interesting though, unfortunately, brief career. He taught for a time at Harvard Medical School, worked in pathology at the Mount Sinai Hospital, and having to give up practice on account of a heart attack, obtained a fellowship in public health at Johns Hopkins. He died at the age of thirty-eight.

In 1925, after leaving Mount Sinai Hospital, Henry Koplik gave his entire time to his practice and insisted on working in spite of a serious cardiac ailment which finally caused his death on April 30, 1927.

During his life Koplik had been elected to medical societies, both American and foreign. He was one of the founders of the American Pediatric Society and at one time was its president. His interest in child welfare resulted in his being appointed to many committees dealing with child health. "A source of great gratification to him was his appointment as a member of the Permanent Commission of the International Association of child welfare and gouttes de lait" (Libman).

In his will he bequeathed $10,000 to Mount Sinai for use in child care and $15,000 to Columbia University to found a scholarship for students of pediatrics.

Henry Koplik's place in the development of American Pediatrics is a significant one. His contributions were so varied that it is difficult to state which was of most value. Of great importance is the element of prophylaxis which he stressed in the conduct of his milk station. When one recalls how the infants of the poor were decimated by "summer diarrhea" and literally how many thousands of babies were saved by the clean milk and the prophylactic care they received at his hands, I think that this must be his chief claim to fame.

I wish to express my indebtedness to Dr. Koplik's daughter, Mrs. Rosalie Koplik Bierman, for putting at my disposition a collection of clippings and documents which were of value in compiling this article.

Murray H. Bass

ROENTGEN PELVIMETRY: EVALUATION OF THE PELVIC CAVITY

BERNARD S. WOLF, M.D.

New York, N. Y.

Roentgen pelvimetry has proved to be a useful tool in predicting the outcome of labor (1, 2). Its greatest success has been in recognizing difficulty at the inlet, i.e. in engagement. Predictions as to the capacity of the pelvic cavity, i.e. the "mid-pelvis" or "mid-plane", have been less reliable. The feasibility of engagement can be determined by trial or test labor with little danger to mother or fetus. Caesarean section and difficult forceps extraction due to mid-pelvic disproportion are, however, associated with greater infant and maternal morbidity. The effort to recognize and measure pertinent pelvic diameters within the pelvic cavity is therefore of considerable practical importance.

One of the chief stumbling blocks in correlating roentgen measurements with the clinical course of labor is the difficulty in determining the size of the pertinent fetal head diameters. Moreover, predictions as to head size based on observations made several weeks before term are unreliable. If difficulty is anticipated because of clinical findings, pelvimetry is usually requested prior to term. The adequacy of the particular pelvis must then be based on the assumption that the fetal head at term will be of average size and shape and of average moldability. It is also assumed that the forces of labor will be satisfactory, that the soft tissues will create no special problem and that the mechanism of labor will be optimum. These assumptions must be checked by clinical observations and perhaps roentgen methods (1), during the course of labor in particular problem cases. Antenatal roentgen pelvimetry may be considered successful if it can correctly predict that delivery per vaginam of an average fetal head is possible without excessive molding and without serious damage to the pelvic soft tissues.

Measurements of the various diameters described below were made by the telepelvimetry methods previously described (3). However, any of the standard methods of pelvimetry are equally applicable. An essential feature of the examination is the Chassard-Lapiné "outlet" view with the subpubic arch parallel to the film. With a target-film distance of 6 feet and a table-top film distance of two inches, the correction factor for the plane of the subpubic arch is 96 per cent. The use of a single correction factor for all cases is particularly suitable in this projection because of the short object-film distances involved. Correction factors for various target-film distances are easily calculated on the basis that the subpubic arch is, on the average, one inch above the table-top. For example, with a target-film distance of 4 feet and table-top to film distance of 2 inches, the correction factor may be taken as 94 per cent. Incidentally, the conventional X-ray table may be used to obtain the Chassard-Lapiné view by having the patient sit on the edge of the table and by off-setting the cassette in the Bucky tray. The Bucky tray may also be pulled out since the patient's legs must be

From the Department of Radiology, The Mount Sinai Hospital, New York City.

separated to allow her to bend over as far as possible. It is convenient to support the patient's feet on a wide stool. The lateral projection is usually taken with the patient standing. If this view is taken with the patient lying down, care is taken that the thighs are extended in order not to obscure the symphysis and the subpubic arch.

The average fetal head at term may be considered to have approximately equal bony biparietal and suboccipito-bregmatic diameters, each measuring 9.3 centimeters. A sphere, 9.3 centimeters in diameter, may thus be considered a geometrical representation of the well-flexed term fetal head. If the average scalp thickness of 3 millimeters is added, the sphere has a diameter of 9.9 centimeters. It seems likely that 3 to 4 millimeters of molding may not be objectionable. A sphere 9.5 centimeters in diameter would then represent a well-flexed, well-molded term fetal head. This figure places a lower limit to any pelvic diameter which must accept the full width of the fetal head. The actual diameters must be greater than this by the thickness of the maternal soft tissues which cannot be completely compressed or displaced beyond the bony limits of the pelvis. The "critical" values for specific pelvic diameters noted below are empirical, based on experience with primipara. In multipara with previously stretched soft tissues, the critical values are smaller by as much as 5 to 7 millimeters. These "critical" values are useful as guides or benchmarks. They must be conceived of as representing a transitional range from no difficulty in any case to difficulty in all cases. The width of the range, or the abruptness of the transition, varies, dependent on the specific diameter under consideration (4).

The pelvic cavity (Fig. 1) may be divided into upper and lower portions. The superior limit is the pelvic brim or true inlet. A plane through the lower margin of the symphysis pubis parallel to the brim may be used as an arbitrary demarcation between upper and lower portions. The inferior limit, or pelvic outlet, is a plane through the lower end of the sacrum and the points of attachment of the sacro-tuberous ligaments to the ischial tuberosities. The posterior boundary is the sacrum. The anterior boundary of the upper part of the pelvic cavity is the posterior surface of the symphysis. The anterior boundary of the lower part is the plane of the subpubic arch. This plane is determined by the pubic rami forming the upper part of the arch and is extended downward and backward as a straight line instead of following the ischial tuberosities. The ascending rami of the ischia forming the lower part of the subpubic arch are actually part of the anterior and inferior boundaries.

The boundaries of the pelvic cavity have been intentionally described in rather loose fashion since there is no general agreement as to the anatomical details. It is recognized that the bony brim of the pelvis is not in a single plane and that the sacral continuation of the iliopectineal lines is behind and above the brim. The "minimum antero-posterior diameter of the inlet" usually extends from the symphysis to the sacral promontory and lies above the bony brim. A critical value of 10.3 centimeters is useful for this minimum antero-posterior diameter. A suitable antero-posterior diameter of the superior portion of the pelvic cavity may be measured between the middle of the posterior aspect of

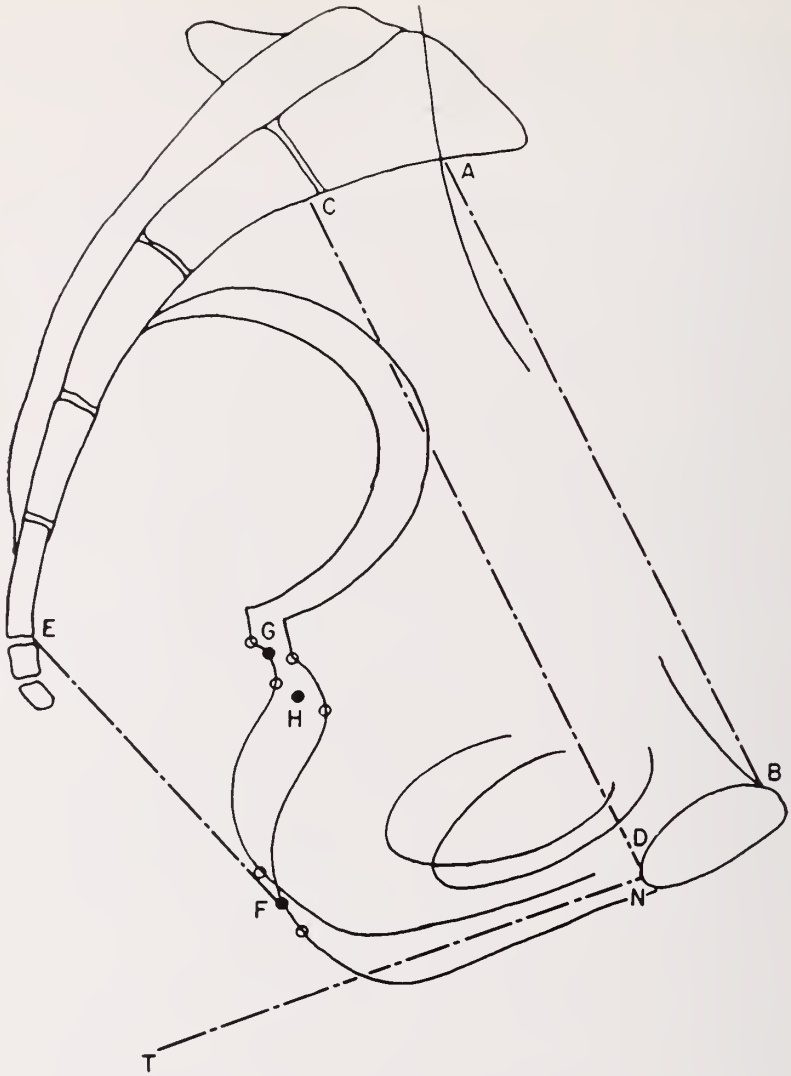

FIG. 1. Boundaries of the pelvic cavity. AB represents a plane through the bony brim or "true" inlet. CD is a plane parallel to AB through the lower border of the symphysis. EF is a plane through the lower end of the sacrum and lower margins of the ischial tuberosities. The lower margins of the tuberosities are chosen as the tangent points of lines drawn from E. Point F is the mid-point between the corresponding points of the two sides. (The use of such mid-points is necessary since the two sides of the pelvis rarely overlap exactly.) Point G is the "spine" point; point H the "notch" point. Line NT, or rather the plane indicated by this line is drawn through the antero-medial margins of the descending pubic rami—actually through the mid-points between the pubic rami of the two sides. The posterior aspect of the symphysis and this "subpubic" plane are the anterior boundaries of the pelvic cavity. The posterior boundary is the anterior aspect of the sacrum. The pelvic cavity may be considered to consist of upper and lower portions separated by the plane CD.

the symphysis and the upper sacral concavity along a line approximately parallel to the bony brim (Fig. 2). A critical value for this diameter is about 11.3 centimeters. Since this antero-posterior diameter extends into the upper sacral concavity, a "well-curved" sacrum as well as a posteriorly directed sacrum is indicated by a large value. The most useful transverse diameter applicable to this region is the so-called available or mid-transverse diameter of the inlet (5) (Fig. 3), also with a critical value of 11.3 centimeters. The shape of the upper

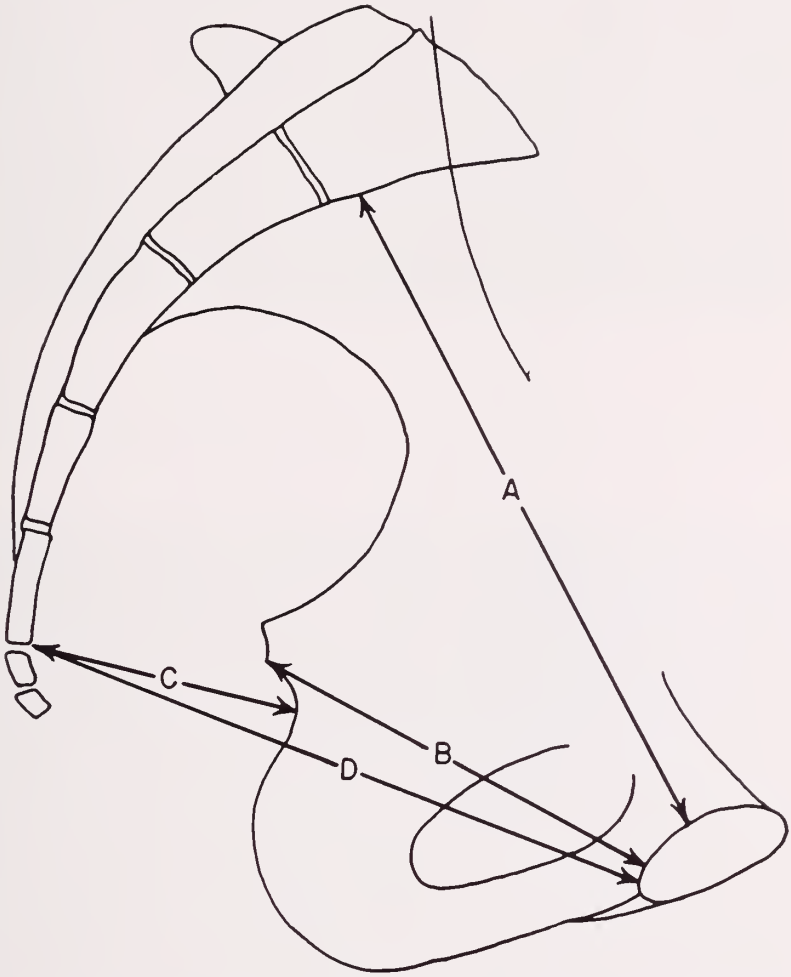

Fig. 2. Pelvic cavity measurements taken from the lateral projection. Line A is drawn from the mid-point of the posterior surface of the symphysis parallel to the true inlet. This diameter is the antero-posterior diameter of the superior portion of the pelvic cavity. Line B is drawn from the spines to the closest point of the symphysis. It is a first approximation of the space available in front of the spines. Line C is drawn between the notch point and the closest point of the lower sacrum—the notch-to-sacrum distance. This distance is used as an approximate measure of posterior space in the lower pelvis to determine whether more accurate measurement is required. Line D is the minimum distance between the lower sacrum and the lower symphysis—"the pubosacral" or "pubosacrococcygeal" diameter.

FIG. 3. Antero-posterior view of pelvis with patient supine, taken at a target-film distance of 6 feet. Spines and adjacent bony contours emphasized. The "mid-transverse diameter of the inlet" in this projection is located two to three millimeters behind the superior margins of the acetabula (5). This is sufficiently accurate for clinical purposes and is easily checked on the Thom's view of the inlet (3). The "internotch" diameter is the maximum transverse diameter in front of the spines (6, 7). The "white lines" or "linea innominata" converge inferiorly and would appear to converge more markedly at shorter target-film distances.

pelvic cavity is essentially the shape of the entrance to the pelvis as seen in the routine inlet or Thom's projection.

As indicated above, critical antero-posterior and mid-transverse diameters in the upper pelvic cavity are each 11.3 centimeters. In the lower portion of the pelvic cavity, similar critical diameters appear to be less—about 10.3 centimeters. The reasons for this are not entirely clear but presumably related to the circumstances that the bony ring of the lower pelvic cavity is incomplete and that flexion and molding of the head are more marked. A sphere 10.3 centimeters in diameter may be used as a geometrical approximation to the bony fetal head plus surrounding fetal and maternal soft tissues. To accept such a sphere, the minimum distance between the lower posterior surface of the symphysis and any part of the lower sacrum must be at least 10.3 centimeters. This minimum diameter is practically always to the lower end of the sacrum (Fig. 2, distance D). This antero-posterior diameter has therefore been called the pubosacrococcygeal diameter (6). A suitable mid-transverse diameter in the lower pelvis is difficult to select on ordinary antero-posterior projections of the pelvis. The so-called side walls (7), located at the brim posterior to the center of the pelvis, extend anteriorly as well as inferiorly. It is difficult to specify a particular level of the side walls which would be directly comparable from case to case. Moloy and Swenson (7) defined an "intertuberous diameter" or "the widest transverse diameter of the outlet" as the "widest diameter in the lower fore pelvis in front

of and below the ischial spines" (Fig. 3). Allen (6) believes that this diameter is a mid-plane rather than an outlet measurement and is the distance "between the flat opposing surfaces of the bodies of the ischia anterior to the bases of the spinous processes". For brevity, this diameter may be called the "internotch" diameter. This internotch diameter, however, is usually located too far forward to serve as a mid-transverse measurement. In the previous report on technique (3), it was pointed out that a transverse diameter could be identified and measured on the outlet view extending between the bodies of the ischia (Fig. 4). This was called tentatively the "intertuberous outlet" diameter. Further investigation has indicated that this diameter is larger than the "internotch diameter" by 2 to 5 millimeters and that it is located about one centimeter below and in front of the lesser sacrosciatic notches. We now prefer to call this diameter the "interischial diameter" and believe that it is a suitable mid-transverse measurement of the lower pelvis. In a small pelvis, the optimum position of this diameter is at the mid-point of the pubosacrococcygeal diameter. A critical value for this interischial diameter appears to be 10.3 centimeters, confirming its mid-transverse location. On this basis, the critical value for the internotch diameter may be as low as 9.8 centimeters.

The spines are a unique anatomical feature of the lower pelvic cavity and require special consideration. The bispinous diameter is an intercalated diameter located behind the center of the pelvic cavity in any borderline pelvis. The center of the head descends anterior to the spines (except in rare instances of marked anthropoid pelves). If the bispinous diameter is small, the fetal head—or the

FIG. 4. Chassard-Lapiné outlet view, taken at a target-film distance of 6 feet. The patient, in sitting position, bends forward so that the subpubic arch is parallel to the film. The "interischial diameter" is the minimum distance between the medially convex lines indicating the inner surfaces of the bodies of the ischia. It is a suitable mid-transverse diameter of the lower pelvic cavity.

10.3 centimeter sphere which represents it for geometrical purposes—must find additional room anteriorly. It is not possible, therefore, to evaluate the significance of any particular bispinous diameter without taking into consideration the space available in front of the spines (Fig. 5). From the lateral view, the minimum distance between the spines and the symphysis may be measured. This distance is a first approximation of the minimum space available in any particular case in front of the spines. With the bispinous diameter and the space anterior to the spines known, it is a simple mathematical problem to calculate the diameter of the largest circle which can pass through the required points. Calculations of this type may be represented in graphical form (Fig. 6). In actual practice, it is frequently inconvenient to resort to a calculation or graph to secure this information. It is not difficult, however, to construct a scale which will read directly the space required in front of the spines, in order that a circle of 10.3 centimeters will be accepted. This scale (Fig. 7) can be applied between the

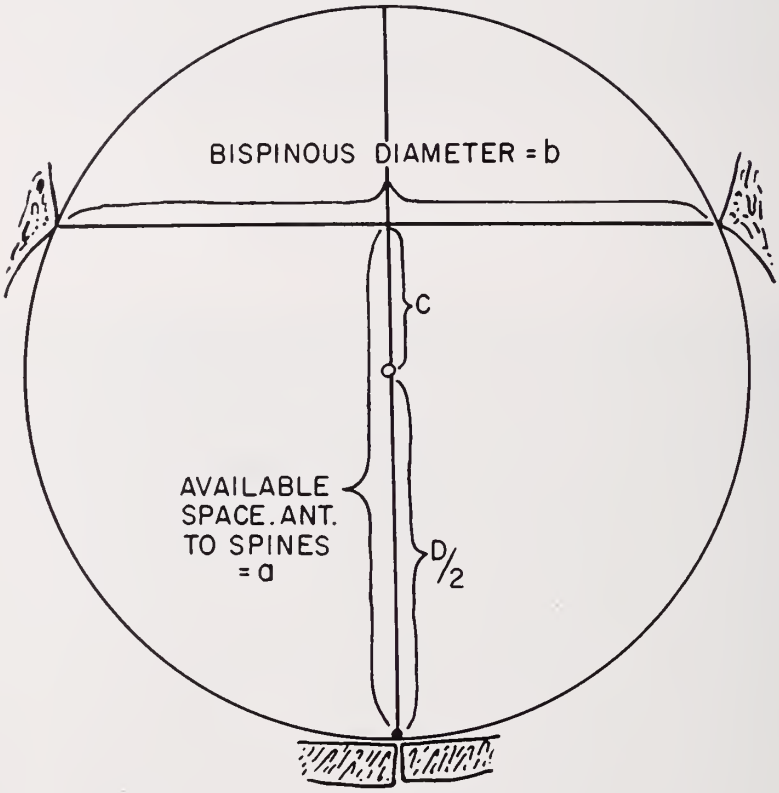

$$D = \text{DIAMETER OF CIRCLE} = a + \frac{b^2}{4a}$$

FIG. 5. Diagram indicating the geometrical relationships between the bispinous diameter (b), the space in front of the spines (a), and the diameter of the inscribed circle. The center of the circle is in front of the spines so that the available space anterior to the spines is the sum of the radius of the circle and the segment c.

spines as if one were measuring the length of the bispinous diameter and the space required for a 10.3 circle directly determined without actually recording the bispinous diameter itself. The difference between the required space found in this fashion and the available space is then an indication of disproportion. If 60 per cent of this difference is subtracted from 10.3, the diameter of the largest possible circle which will pass the level of the spines is obtained. This may be called "the available antero-posterior diameter at the level of the spines". If the graph is used, this value is obtained directly with slightly greater accuracy. If the available space is greater than the required space, the same procedure may be carried out—the available diameter will be greater than 10.3 centimeters by 60 per cent of the difference. The figure 60 per cent has no fundamental significance but arises from the nature of the algebraic expression.

The second feature of special importance in the lower pelvis is an evaluation of the rôle of the projecting lower end of the sacrum as related to the subpubic arch (8). As noted above, a critical value from sacrum to symphysis is 10.3 centimeters—the diameter of the standard head. Below the level of the symphysis, there is additional room anteriorly in the midline for protrusion of soft tissue and, more inferiorly, of the head itself. In order to evaluate the available space in front of the subpubic arch, it is necessary to take into consideration the width and shape of the subpubic arch at various levels. A method of doing this is described below. This method also permits a better estimate of the minimum dis-

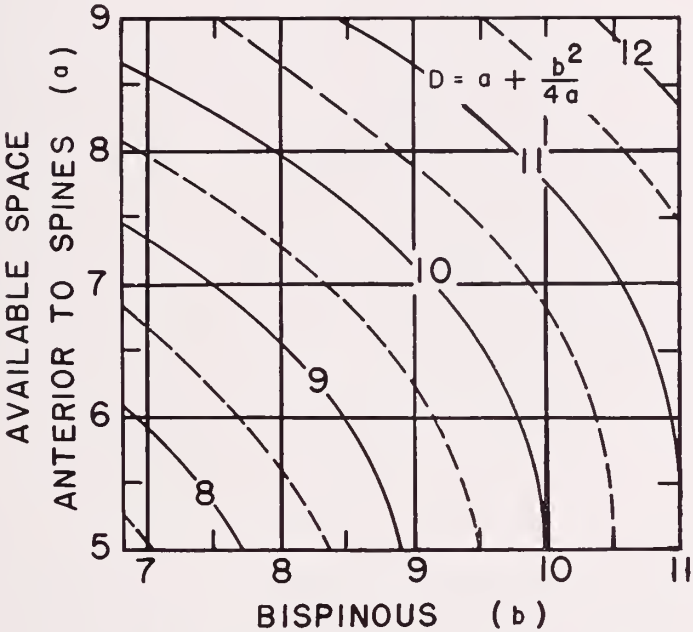

FIG. 6. Graph of the family of curves showing the relationship between the bispinous diameter (abscissa), the available space anterior to the spines (ordinate) and the diameter of the inscribed circle, indicated on the individual curves. This diameter may be called the "available antero-posterior diameter at the level of the spines." This should not be confused with the available space in front of the spines.

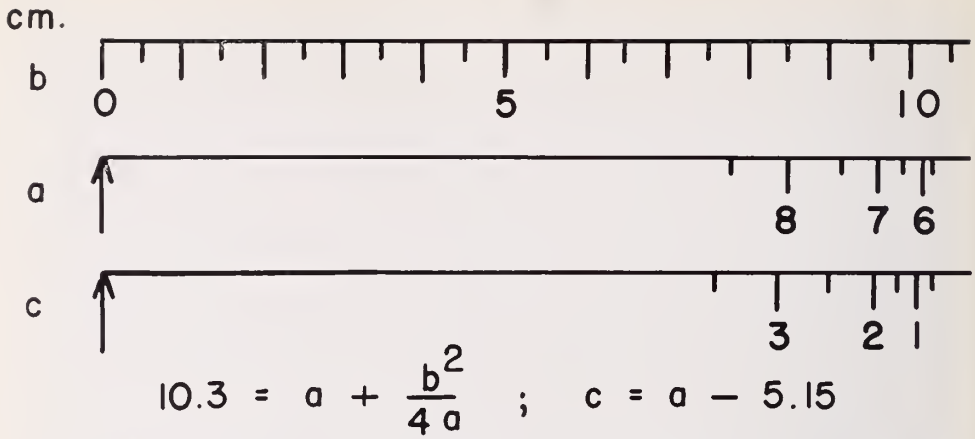

FIG. 7. Actual size. Scale "b" is an expanded (1.06 to 1) centimeter scale used to measure the bispinous diameter directly from the antero-posterior 6 foot film. Scale "a" is applied in the same fashion between the spines but gives the value of the space required anterior to the spines to accept a 10.3 cm. circle. Scale "c" is similar to "a", but 5.15 centimeters has been subtracted so that values of the segment c (Fig. 5) may be read directly. Scale "c" is not necessary (since it differs from scale "a" by a constant factor) but is convenient to use if the axis described below is constructed.

tance anterior to the spines. It should be noted, however, that the construction to be detailed is necessary only in problem cases. The decision to carry out the construction is based on the value of the minimum distance between the lower sacrum, usually the lower end of the sacrum, and the anterior margin of the lesser sacrosciatic notches—the "notch" point. If this notch-to-sacrum distance is less than 5.0 centimeters, the "axis" to be described is constructed. It should be emphasized, however, that this "notch-to-sacrum" distance may be considerably less than 5.0 centimeters without disproportion, if the subpubic arch turns out to be adequate.

The antero-medial bony margins of the inferior ischiopubic rami form the subpubic arch and set the anterior limit to the position of the fetal head at the different levels of the lower pelvis. The position of the center of the model 10.3 sphere when located as far forward as possible within the pelvis is indicative of the effect of the subpubic arch at any particular level. If the arch is wide at a particular level, more of the sphere can protrude beyond the arch and the center of the sphere may be located more anteriorly. If a line or axis joining these center points at the various levels could be constructed (Fig. 8), it would then be possible to determine whether the space posterior to the axis, to the sacrum, is adequate at all levels to accept one-half of the required diameter, i.e. one-half of 10.3 centimeters or 5.15 centimeters. The axis in question can be constructed with the use of simple geometrical theorems by transferring information from the outlet view to the lateral projection. The principle involved is demonstrated in Figs. 9A and 9B. At any selected point below the symphysis, the largest circle which can be inscribed within the arch is determined. This circle may be considered to be a circular cross-section of the sphere located within the pelvis. For

a fixed size of sphere, the size of the circle determines the position of the center of the sphere. The actual location of the center can be found by graphical or algebraic methods (Figs. 9A, 9B, 10). If this procedure is carried out at every level, the complete axis may be drawn. In actual practice (Figs. 11, 12, 13A,

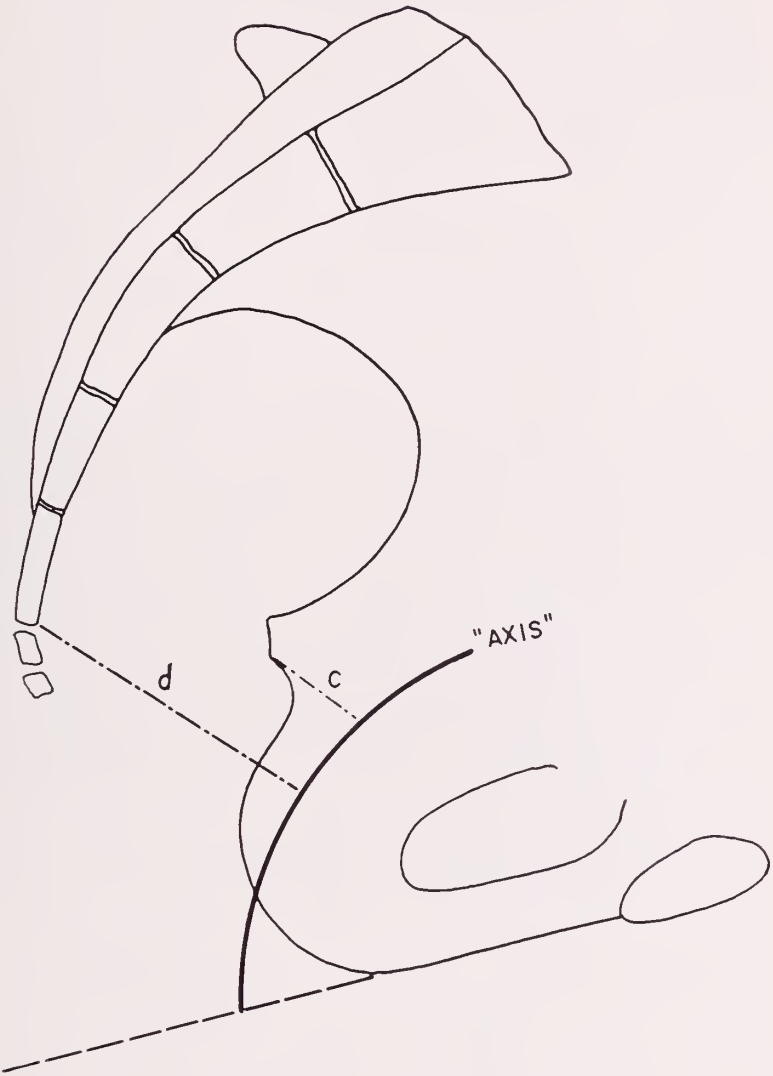

Fig. 8. An "axis" to be constructed which will indicate how far forward the center of a 10.3 centimeter sphere may be located at all levels of the inferior pelvic cavity. The minimum distance (d) from the sacrum to this axis must be at least one-half the diameter of the model 10.3 centimeter sphere, i.e. 5.15 centimeters. If not, bony obstruction to the passage of the average term head is anticipated. A better estimate of the minimum space available anterior to the spines is also obtained by determining the shortest distance between the spine point and the axis, distance (c.) This distance may be compared with the required value of c determined by using scale "c" of Fig. 7.

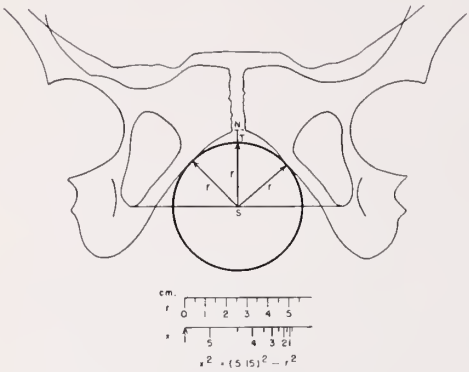

Fig. 9A

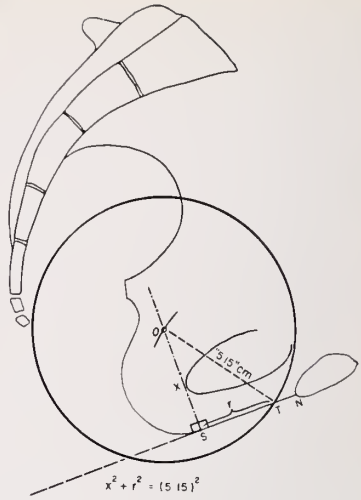

Fig. 9B

Fig. 9A. Outlet view; Fig. 9B Lateral view of same case. These figures demonstrate the principle involved in determining the location of the "axis". At any particular level of the subpubic arch (S), a circle may be inscribed (Fig. 9A) which is a feature of the arch per se. However, this circle also may be looked upon as a circular cross-section of a sphere within the pelvis which protrudes beyond the arch as far as possible at the same level (Fig. 9B). The level selected for illustration is that of the lower margins of the obturator foramina. This level can be found by inspection in both the outlet and lateral views. The distance X (Fig. 9B) is the distance from the center of the sphere to the subpubic arch along a line perpendicular to the plane of the arch. The distance X, the radius of the circle inscribed under the arch (r) and the radius of the pelvic sphere (5.15 centimeters) are related by the Pythagorean theorem. The axis point, point 0, may therefore be found by calculating the value of X. The location of 0 may be found graphically by finding the point T at a distance r from S and then by swinging an arc with radius 5.15 centimeters from T to the perpendicular line. The point of intersection is the axis point. It is also possible to derive a scale (insert, Fig. 9A) to measure r on the outlet view which will read directly values of X. Or—it is possible to preselect a convenient value of X, and thereby of r, and then determine the distance NS by fitting a circle with this value of r as its radius within the subpubic arch. This last method (see later) turns out to be most convenient in actual practice.

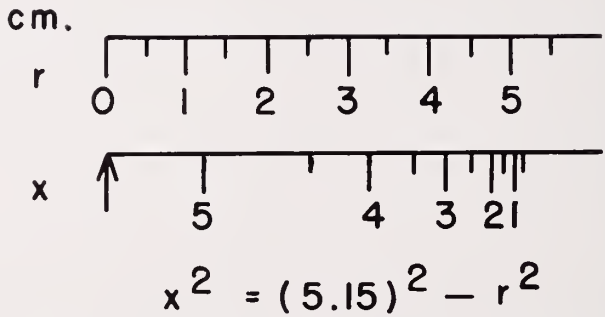

Fig. 10. Actual size of insert scales in Fig. 9A. Scale "r" is an expanded (1.06 to 1) scale which may be used to measure the radius of inscribed circles within the subpubic arch (4 foot target—film distance). Scale "x", applied to the distance r in the same fashion, gives the corresponding X value (Fig. 9B). This is a useful scale to have available for spot-checking selected points. To construct the axis, however, the method outlined below of using a transparent template is simpler.

13B), it is necessary only to determine three points—the lowest, the highest and a suitable point in-between. The complete axis is then drawn in free-hand fashion since there are no significant discontinuities in the curve.

After the axis described above is constructed, the minimum distance between the lower sacrum and the axis can be measured. If this distance is less than 5.15 centimeters, difficulty may be anticipated. The "inferior antero-posterior diameter" may be said to equal the sum of the minimum sacrum-to-axis distance and 5.15 centimeters. This value is equal to the diameter of the circle which can pass between the lower end of the sacrum and the subpubic arch at the most critical level. If this diameter is, for example, 10.1 centimeters and the term head is of average size, additional molding of about 2 millimeters may be necessary. Additional molding of 4 to 5 millimeters probably represents an extreme limit.

If the axis is constructed, a more accurate determination of the available space anterior to the spines may also be made. The minimum distance from the spines to the axis (segment c, Fig. 5 and Fig. 8) plus 5.15 centimeters is the smallest value of this space. It includes the possibility that the minimum space available may be below rather than at the level of the symphysis. It is convenient to read the required value of c directly from a derived scale (Fig. 7) to compare with the actual value of c. If 60 per cent of the difference is subtracted from 10.3, the available antero-posterior diameter at the level of the spines is obtained. If the available space is larger than the required space, the difference is added to 10.3 rather than subtracted.

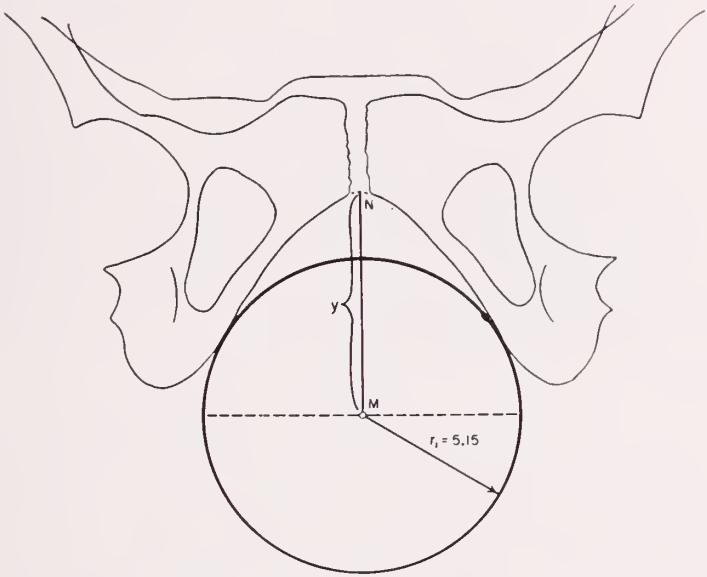

FIG. 11. Illustration of method of determining the "symphysis-biparietal" distance. The true diameter of the circle is 10.3 centimeters. The corrected value applied to the subpubic arch is expanded in the ratio of 1.04 to 1 because of magnification (6 foot technique). The distance NM or y is the symphysis-biparietal distance and is measured by using an expanded linear scale with the same correction factor (see template of Fig. 13).

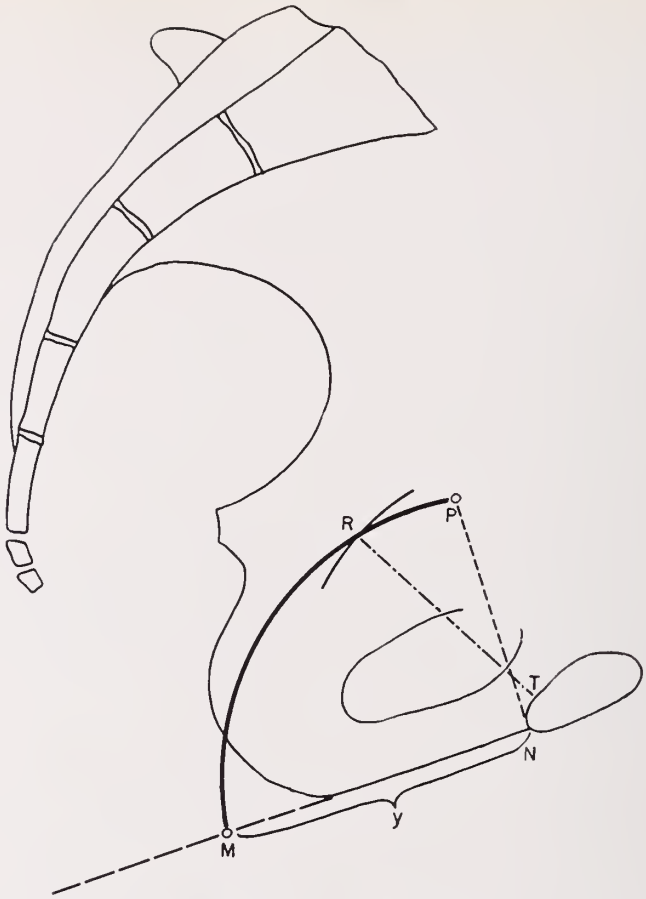

FIG. 12. The distance NM is the symphysis-biparietal distance determined as in Fig. 11 (Note—In laying off the distance NM or y, the magnification factor applicable to the latera projection must be used.) Point M is the lowermost point of the axis to be constructed. The uppermost point is a point, P, 5.15 centimeters behind the upper end of the subpubic arch, i.e., the lower end of the symphysis. Usually, however, the projecting posterior aspect of the symphysis, T, is more critical than its lower margin, N. The upper part of the axis, R, is therefore determined by swinging an arc of 5.15 centimeters (suitably expanded) radius from the lower posterior aspect of the symphysis.

DISCUSSION

The construction of the axis locating the most anterior possible positions of the center of a 10.3 centimeter sphere has been described in the illustrations in detail in order that the underlying principles might be made clear. The time and effort required in practice to perform the required steps are minimal if a transparent template is used (Fig. 14). An outlet view with the subpubic arch exactly parallel to the film is not always available. However, a certain latitude is permissible in this regard. In general, if the promontory is projected within the body of the symphysis or a centimeter above or below it, the construction can be made without correction. It is possible to make corrections for more unsatisfactory

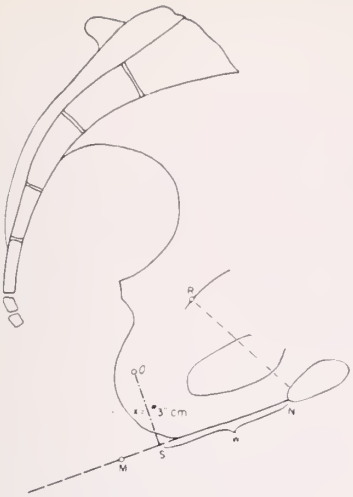

Fig. 13A

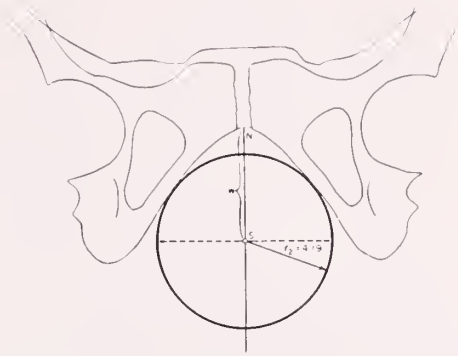

Fig. 13B

Fig. 13A, 13B. In order to find another point along the axis, the method (Fig. 9) of preselecting a value of X and thereby r and finding NS or w is adopted. A value of 3.0 centimeters for X is convenient since it is integral and determines a point in the critical region of the axis (Fig. 13A). If X is to be 3.0 centimeters, r must have a value of 4.19 centimeters (expanded length 4.36 cm.). A circle of this radius is applied to the subpubic arch, Fig. 13B, and NS or w measured. This procedure is similar to that used in determining the symphysis-biparietal distance. Point S is then located in the lateral projection, Fig. 13A, and the axis point found by measuring off 3 centimeters (on the expanded scale for the lateral projection) behind it along the perpendicular. The axis may then be drawn in free-hand fashion through M and 0 and tangent to the arc at R.

films but these are cumbersome and, in general, it is more desirable to repeat the projection. There is usually little difficulty in delineating the lower margin of the symphysis in the outlet view. The lucent band due to separation at the symphysis is frequently more easily identified than the adjacent bony margins of the pubes. The lucent band also serves as a guide to the location of the bony contours of the superior margins of the bodies of the pubic bones (Fig. 15A). There may be difficulty in recognizing the inferior margin of the symphysis in the lateral projection. If this occurs, the distances between the centers of the two template circles inscribed within the arch and the top of the symphysis or the lower margins of the obturator foramina or the lower margins of the ischial tuberosities may be measured (Fig. 15). "Lower" in this connection refers to the direction of the plane of the subpubic arch (Fig. 15B) and all distances including the height of the symphysis are measured in this plane. These landmarks are useful because they may be identified in both the outlet and lateral views.

Measurements made by different observers on the same set of films can be expected to vary, but rarely by more than a millimeter. For purposes of description and calculation, fractions of a millimeter have been included in several numbers quoted above but actual measurements are made only to the nearest millimeter. The overall accuracy of the method is probably not better than 5 per cent.

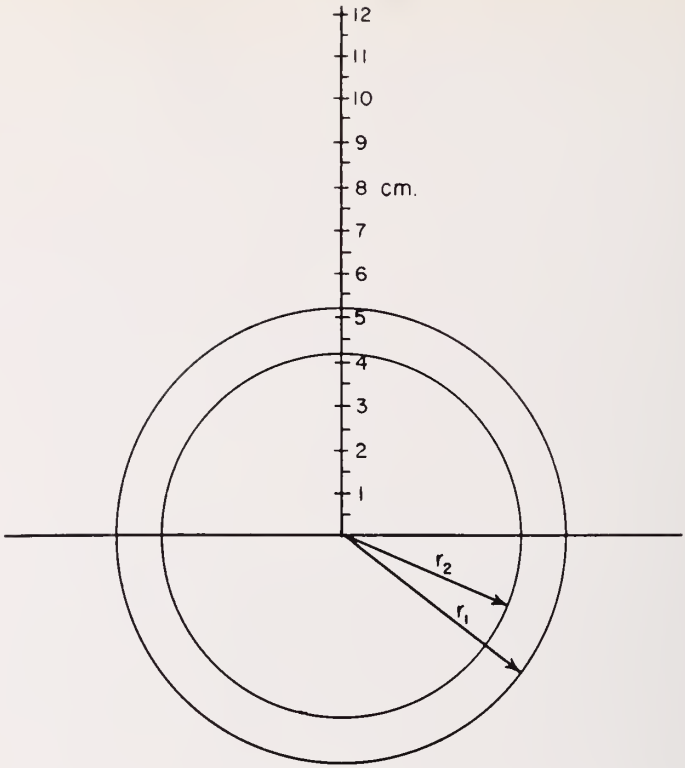

FIG. 14. Components of transparent template (not actual size) used as in Figs. 11 and 13B. Larger circle represents a circle with radius of 5.15 centimeters, the smaller a radius of 4.19 centimeters. In drawing the template, these values and the linear centimeter scale must be suitably expanded in order to permit direct application to the film. For a 6 foot target film distance, these lengths are expanded in the ratio of 1.04 to 1; for a 4 foot target-film distance, 1.06 to 1.

The measurements described are most useful in borderline but essentially gynecoid pelves. Marked abnormalities in shape of the lateral walls of the pelvis or obvious deformity or asymmetry require special consideration. Moreover, it should be emphasized that the critical values assume that the mechanism of labor will be such as to permit optimum head diameters to present to the smallest pelvic diameters. If flexion of the head is incomplete, an intermediate occipito-frontal diameter rather than the suboccipito-bregmatic diameter will present and may create unanticipated difficulty. For example, an interischial diameter of 10.3 centimeters is not satisfactory unless the biparietal diameter is presented to it or unless the head is markedly flexed. With transverse position and moderate flexion, this diameter must be at least 10.8 centimeters.

The axis construction takes into consideration a variety of structural features which, otherwise, must be described individually e.g.,—the height and obliquity of the symphysis, the height, width, shape and obliquity of the subpubic arch and the shape and position of the lower sacrum. The axis does not necessarily indicate the spontaneous course of the head as it descends in the pelvis but rather

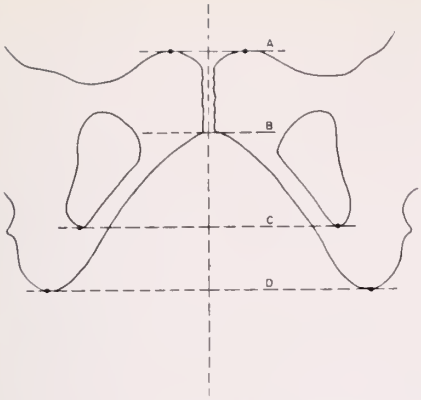

Fig. 15A



Fig. 15B

Fig. 15. Bony landmarks identifiable in both outlet and lateral projections. If the lower end of the symphysis cannot be delineated in a particular case on the lateral view, the location of the centers of the template circles may be related to the level of the top of the pubes (A), the lower margins of the obturator foramina (C), or the lower margins of the ischial tuberosities (D).

Fig. 15A, outlet view. Note that the highest bony point of the pubis is lateral to the symphyseal articulation.

Fig. 15B, lateral view. Distances measured on the outlet view are transposed to the lateral projection in the plane of the subpubic arch and its upward and downward extensions. Since it is more accurate to use points as near as possible to the arch, points B and A are more desirable than C or D. This is particularly true when a short target-film distance is used for the outlet view and when the subpubic arch is not placed parallel to the film at the time the outlet projection is taken.

its possible course if all available space is to be utilized. In borderline pelves, it is often necessary to direct the head into an optimum position by application of forceps. If the measurements are adequate, no actual disproportion is anticipated if the forceps are applied correctly.

No specific mention has been made of outlet measurements. However, the lowermost portion of the axis is, in reality, an evaluation of the outlet and indicates how far backward and downward the head may have to pass before it can be delivered. The maximum bony transverse diameter at this level is at the insertion of the sacro-tuberous ligaments on the tuberosities. It is not possible to measure this diameter satisfactorily since the points in question cannot be brought into profile. This diameter is, however, of little importance since the soft tissues behind the tuberosities may be stretched manually and thereby provide a larger transverse diameter.

Finally, it should be recalled that delay due to any particular diameter will be manifested above the level of the small diameter. For example, if the inferior antero-posterior diameter of the pelvis is small, delay in the downward progress of the head occurs above the level of the spines. Moreover, the shorter this diameter is, the higher in the pelvis is obstruction manifested.

SUMMARY

1. A series of measurements are described to assist in the evaluation of the capacity of the pelvic cavity in borderline cases.

2. These measurements may be obtained by any standard method of pelvimetry which includes an outlet view taken by the Chassard-Lapiné technique.

3. A suitable mid-transverse diameter of the lower pelvic cavity between the ischial bodies may be obtained from the outlet view. This diameter is of greater significance than any measurement made between the ischial tuberosities.

4. The bispinous diameter cannot be evaluated without consideration of the space available anterior to the spines. A method of combining these measurements to predict the available antero-posterior diameter at the level of the spines is presented.

5. The significance of a forward projecting lower end of the sacrum must be determined in relation both to the symphysis pubis and the subpubic arch. The minimum distance form the lower sacrum to the symphysis may be measured directly. The rôle of the subpubic arch may be evaluated by the construction of an "axis" described in the text. This axis represents the line or locus of centers of a 10.3 centimeter sphere, visualized as descending through the lower pelvic cavity and located as far forward as the subpubic arch will permit.

REFERENCES

1. Moir, J. C.: Measuring the Obstetric Value of the Pelvis: The Use of the "Graph Method" for the Interpretation of the Radiological Findings. J. Obst. and Gynaec. Brit. Emp., 56: 189, 1949.
2. Williams, E. R., and Phillips, L. G.: The Value of Antenatal Radiological Pelvimetry. J. Obst. and Gynaec. Brit. Emp., 53: 125, 1946.
3. Wolf, B. S., and Loevinger, R.: Practical Telepelvimetry. Radiology, 63: 220, 1954.
4. Allen, E. P.: Standardized Radiological Pelvimetry. IV. Interpretation of Pelvimetry. Brit. J. Radiol, 20: 205, 1947.
5. Moir, J. C.: The Use of Radiology in Predicting Difficult Labour. J. Obst. and Gynaec. Brit. Emp., 53: 487, 1946.
6. Allen, E. P.: Standardized Radiological Pelvimetry. I. Quantitative Aspects. Brit. J. Radiol., 20: 45, 1947.
7. Moloy, H. C., and Swenson, P. C.: Diagnostic Roentgenology; Ed. Ross Golden. Vol. 2, Chap. X, pg. 826 GG, Fig. 96-D. New York, Thomas Nelson and Sons, 1936.
8. Moir, J. C.: The Use of Radiology in Predicting Difficult Labour. J. Obst. and Gynaec. Brit. Emp., 54: 20, 1947.

RECURRENT DUODENAL ULCER WITH NORMAL PATENT STOMA, 33 YEARS AFTER GASTROENTEROSTOMY

JULIUS J. LEICHTLING, M.D. AND JOHN H. GARLOCK, M.D.

Gastroenterostomy was considered curative in the treatment of peptic ulcer for many decades after its introduction in 1881 (1). But it was soon determined that, as patients were followed for progressively longer periods of time, the incidence of jejunal or marginal ulcer increased markedly. Thus, Judd, in 1921, reported an incidence of 1.2% in 4,324 gastroenterostomies (2). By 1925, Lewisohn, emphasizing the importance of careful personal follow-up revealed a 34% incidence of gastrojejunal ulcer after gastroenterostomy (3).

Early sources make no mention of a recurrence of the original ulcer in the duodenum except in those instances where the gastroenterostomy was taken down or where the gastroenteric stoma became contracted and stenotic. Present standard textbooks of gastroenterology, surgery and surgical pathology, discuss gastrojejunal ulcer at great length but rarely, if at all, mention recurrent duodenal ulceration after gastroenterostomy (4, 5, 6). It has always been assumed that the original ulcer in the duodenum remains healed. Bockus mentions that a duodenal ulcer may remain active after gastroenterostomy if the pylorus remains the principle channel for the passage of food leaving the stomach (7). It is now well established that 60–70% of recurrences will have manifested themselves within 2 years after surgery. Even the longest follow-up studies have not taken into account recurrences beyond 20 years.

Ginzburg and Mage were among the first to study the specific types of ulcer recurrences following gastroenterostomy (8). They examined the resected specimens representing recurrences 6 weeks to 19 years following gastroenterostomy for duodenal ulcer. Where the stoma was efficient, 56 specimens revealed stomal or jejunal ulcerations, 6 showed lesser curvature gastric ulcers, and 2 contained active duodenal ulcers in addition to anastomotic ulcers. Isolated active duodenal ulcers were seen in 9 specimens in all of which the stoma was stenotic or mechanically inefficient. Large series of cases studied by others revealed similar types of recurrences, and in no instance was an isolated recurrent duodenal ulcer found in the presence of a non-ulcerated, patent stoma (9, 10). In view of this, it was deemed worthwhile to present the following case in which an active duodenal ulcer was resected and where the stoma was patent as demonstrated clinically, roentgenographically and after resection. This case is possibly unique in this respect; at least we have not been able to find a comparable example in the literature.

CASE REPORT

S. L., hospital #31337, a 70 year old white male was admitted to the private pavilion of Mount Sinai Hospital on October 30, 1954. Thirty-three years ago a posterior gastroenterostomy was performed for a duodenal ulcer. Except for the development of diabetes mellitus 18 years later, he remained without symptoms until 9 months before admission when he

had an episode of tarry stools and abdominal cramps which was treated conservatively and controlled with 3 pints of blood. He apparently never vomited or had epigastric discomfort until 3 weeks ago when he developed severe abdominal pain to the right of his right pararectus incision. There was no nausea, vomiting or tarry stools at this time. The pain was extremely severe for the past 3 days and was refractory to medical therapy with diet and alkalis.

Examination revealed an acutely ill elderly male in obvious severe pain. Pulse 100, blood pressure 114/72, respiration 28, normal temperature. There was marked tenderness along the right side of a wide right upper paramedian vertical scar. No muscle spasm or rebound tenderness was present.

Laboratory: Blood count revealed a Hgb. of 15.5 Grams and a WBC of 7,450 with 71% polys. Blood urea nitrogen was 22 mg. %; blood sugar 176 mg. % and the urine contained sugar but no acetone; stool examination showed no occult blood. Gastric analysis with histamine yielded 90 units of total and 70 units of free hydrochloric acid after 45 minutes X-rays taken on October 21, 1954 revealed a marked duodenal deformity with an apparently normal, functioning, gastrojejunal stoma (fig. 1). On November 3, 1955 a subtotal gastrectomy with excision of the jejunal portion of the old stoma, jejuno-jejunostomy, and posterior gastrojejunostomy was performed. The old gastroenterostomy stoma was 2.5 cm. in diameter and showed no ulceration. One-half cm. distal to the pylorus, a penetrating duodenal ulcer 1 by 2 cm. was disclosed and removed with the resected stomach.

Pathological report: Specimen consisted of a stomach, subtotally resected, measuring 13 cm. along the lesser curvature and 20 cm. along the greater curvature, and attached

FIG. 1. G.I. series demonstrating ulcer niche in the duodenum and patent gastrojejunosomy.

2 cm. rim of duodenum. The stomach is somewhat dilated and the rugae in the anterior wall are prominent. There is stomal opening 2.5 cm. (as determined at surgery) in diameter in the posterior wall of the stomach 12 cm. from the pyloric ring and 7 cm. from the proximal line of resection. The surrounding mucosa is thickened and reddened and is rolled over the margins of the stomal opening. On the serosal side a 5 mm. rim of jejunum is attached to the stomal margin. The anastomosis is well healed and appears old. Separately received is a 6 cm. segment of jejunum with a 2.5 cm. opening on one wall. The mucosa of this segment is somewhat reddened but no ulcerations are seen. 0.5 cm. distal to the pylorie ring there is a 1 by 2 cm. defect within the posterior wall of the duodenum. This rim of this defect is formed by somewhat thickened and rolled and slightly reddened duodenal mucosa. The overlying serosal surface is somewhat reddened and shows a cut margin. The small segment of mesentery attached appears unremarkable. *Microscopic report:* Chronic peptic ulcer of duodenum. Segment of jejunum and stoma showing no evidenee of uleer.

The postoperative eourse was uneventful and the patient left the hospital on the 14th postoperative day symptom-free. The latest contact with him on February 26, 1955 disclosed that his insulin requirement was reduced almost 50% as compared with the amount needed before surgery. He was free of any gastrointestinal symptoms and considered himself restored to health.

DISCUSSION

Healing of a duodenal ulcer takes place following gastroenterostomy as a result of the diversion of a portion of the gastric contents away from the ulcer bearing area of the duodenum into the jejunum (11). Duodenal regurgitation taking place through the stoma of a gastroenterostomy presumably rapidly neutralizes gastric acidity (12). The effectiveness of a gastroenterostomy is therefore dependent on both mechanical and chemical factors. The chemical factor is dependent on the mechanical efficiency of the stoma allowing the alkaline duodenal secretions to reach the interior of the stomach and counteract the acid gastric contents. The site of recurrent ulceration following gastroenterostomy also seems to hinge largely on the functional patency of the stoma. If the duodenum is efficiently bypassed, the recurrence will occur at the stoma, or less frequently, along the lesser curvature of the stomach. If the stoma becomes stenotic and gastric content is not diverted away from the duodenum, a recurrent duodenal ulcer will occur. In such cases the stoma is not involved in ulceration.

In the case reported above, we have the unusual circumstance of a recurring duodenal ulcer in the presence of a non-ulcerated, patent, stoma. The explanation which seems logical is that even though the stoma was found patent on x-ray and at operation, physiologically it was poorly functioning, and the main current of gastric content was in the normal direction of the pylorus and duodenum. The experimental work of Cannon and Blake many years ago showed that even though a gastroenterostomy was patent and properly placed, it did not empty by gravity and food sometimes preferentially went through the duodenum rather than the anastomotic stoma (13). These authors also showed that if the stomach were stretched by ingested material, obstruction might occur in the efferent loop by its compression against the gastric wall. Vitkin, by means of balloons placed at the anastomosis, noted that there was a rhythmic evacuation occasioned by a periodic opening and closing of the anastomosis due to peristaltic contraction of the efferent loop (14). Such sphincter-like contractions of the stoma have also been observed through the gastroscope, by x-ray and at

operation (15, 16, 17). It is therefore possible that an anatomically patent stoma may be physiologically closed most of the time thus bringing about the same situation as existed prior to the gastroenterostomy. Other factors shown by controlled experiments to interfere with gastric emptying after gastroenterostomy, are hypoproteinemia and vitamin B deficiency (18, 19). One can only speculate as to which of the above mechanisms was responsible for the recurrent duodenal ulceration after a latent period of 33 years.

SUMMARY

Although the likelihood of recurring symptoms following gastroenterostomy for duodenal ulcer diminishes after 5 years, the possibility of their recurrence is ever present. Ulcer recurrences are usually anastomotic and those few instances of recurrent duodenal ulcers reported have occurred with stenotic anastomotic stomas. An unusual case of recurrent duodenal ulcer, in the presence of a patent normal stoma, is presented. Possible etiological mechanisms are discussed.

REFERENCES

1. Mayo, H. W., Jr.: The Physiologic Basis of Operations for Duodenal, Gastric, and Gastrojejunal Ulcer. Surgery, 26: 251, 1949.
2. Judd, E. S.: Jejunal Ulcer. Surg., Gynec. & Obst., 33: 120, 1921.
3. Lewisohn, R.: The Frequency of Gastrojejunal Ulcers. S. G. & O., 40: 70, 1925.
4. Ivy, A. C., Grossman, M. I., and Bachrach, W. H.: Peptic Ulcer. The Blakiston Co., Philadelphia, 1950.
5. Boyd, W.: Surgical Pathology, 6th edition. W. B. Saunders Co., Philadelphia, 1947.
6. Christopher, F.: Textbook of Surgery, 5th edition. W. B. Saunders Co., Philadelphia, 1949.
7. Bockus, H. L.: Gastroenterology. W. B. Saunders Co., Philadelphia, 1943.
8. Ginzburg, L., and Mage, S.: Failures Following Gastroenterostomy for Gastroduodenal Ulcer. S., G. & O., 67: 788, 1938.
9. Weinstein, V. A., and Colp, R.: Gastrojejunal Ulcer, a Ten Year Study. Surgery, 32: 96, 1952.
10. Wright, G.: Collective Inquiry by the Fellows of the Association of Surgeons into Gastrojejunal Ulceration. Brit. J. Surg., 22: 433, 1926.
11. Meyer, K. A., and Stein, I. F.: Management of Recurrent Peptic Ulcer. Surg. Clin. No. Am. (Feb.), 1952, p. 35.
12. Holman, C., and Sandusky, W. R.: Gastric Acidity after Gastroenterostomy. Am. J. Med. Sci., 195: 220, 1938.
13. Cannon, W. B., and Blake, J. B.: Gastroenterostomy and Pyloroplasty—An Experimental Study by Means of Roentgen Rays. Ann. Surg., 41: 686, 1905.
14. Vitkin, S. F.: Motor Functions of the Stomach after Resection. Ann. Surg., 111: 27, 1940.
15. Schindler, R., and Dailey, M. E.: Gastroscopic Observations on Gastric Motility. Am. J. Dig. Dis., 8: 8, 1941.
16. Kennedy, C. S., Reynolds, R. P., and Cantor, M. O.: A Study of the Gastric Stoma after Partial Gastrectomy. Surgery, 22: 41, 1947.
17. Kennedy, C. S., Reynolds, R. P., and Cantor, M. O.: Demonstration at Operation of Sphincteric Action at the True Gastric Stoma. Am. J. Surg., 74: 808, 1947.
18. Rhoads, J.: Surgical Physiology of the Stomach. Surg. Clin. No. Am., 29(6): 1964, (Dec.) 1949.
19. Heublein, G. W., Thompson, W. D., and Scully, J. P.: Effect of Vitamin B Complex Deficiency on Gastric Emptying and Small Intestinal Motility. Am. J. Roentgenol., 46: 866, 1941.

DR. KAUFMAN SCHLIVEK

To Dr. Kaufman Schlivek, past attending ophthalmic surgeon to The Mount Sinai Hospital, consultant to The Mount Sinai Hospital, N. Y. Eye and Ear Infirmary, Monmouth Memorial and St. Joseph Hospitals; past chairman of the Eye Section of the New York Academy of Medicine, clinical professor of ophthalmology of the College of Physicians and Surgeons of Columbia University; ophthalmologist to The Mount Sinai Hospital in the great tradition of Koller and May; always ready to impart his great clinical and surgical knowledge to all who had the capacity and willingness to learn; innovator of many original surgical and therapeutic techniques; teacher, counsellor and friend to residents, students, colleagues and patients; in recognition of his steadfast and wholehearted loyalty to Mount Sinai and its traditions, we present with respect, love and esteem this medallion of merit.

DR. REUBEN OTTENBERG

To Dr. Reuben Ottenberg, first to perform a blood transfusion in which the donor was tested for blood group compatibility, first to suspect that the blood groups were inherited according to Mendel's Law, demonstrator of hemolysins and agglutinins in blood transfusions in the dog, active worker in the heroic age of blood transfusion, investigator of hepatic function when that organ was terra incognita, sound clinician, gentle, kindly, lovable man, the Jacobi Medallion is presented by this Association.

DR. RALPH COLP

To Dr. Ralph Colp, important contributor to gastric, biliary and intestinal surgery, teacher of generations of medical students and young surgeons, long time Chief of a Surgical service at The Mount Sinai Hospital, which was known wherever good surgery was performed, former President of the Medical Board of The Mount Sinai Hospital, Fellow of the American Surgical Society, former President of the New York Surgical Society, formerly Clinical Professor of Surgery at Columbia and now at the New York Medical College, a leader of men, the Alumni Association takes pleasure and pride in conferring this medal for meritorious service.

DR. JONAS E. SALK

To Dr. Jonas E. Salk, former interne and House Physician at The Mount Sinai Hospital, for outstanding accomplishments in the fight against poliomyelitis and influenza, for the hope you have given to the parents of children all over the world, and for what you are, the Association of Alumni of The Mount Sinai Hospital is pleased and privileged to honor you and to present to you the Jacobi Medallion which is given to Mount Sinai Alumni who have served the Association well, or who have made significant contributions to the world.

NOTICE

Subscribers

Librarians

The Journal of The Mount Sinai Hospital will be issued on a calendar year basis. Volume XXII will terminate with the November-December number (4) and the new volume will begin with the January-February (1956) number.

ERRATUM

Page 40, line 30, Volume XXII (May-June 1955): The word "increased" should be deleted and the sentence which contains it should read, "According to Moschcowitz arteriosclerosis is a resultant of two factors, intravascular pressure and time."

Important Notice
TO SUBSCRIBERS

Changes in your address should be made in writing:

1. *To The Editor*, The Journal of the Mount Sinai Hospital, 1 East 100 Street, New York 29, New York. Notice should be given 60 days preceding your change of address, and your old and new address should be given.

2. *To your Postman.* Ask him for Form 22 and Form 22-S and fill these out carefully.

We regret that in instances of change of address guarantee cannot be made of replacement of issues not received. If you have recently had a change of address and have failed to receive the publication, assure delivery of future issues by writing promptly to The Editor.

THE JOURNAL OF
THE MOUNT SINAI HOSPITAL

In Memoriam

NATHAN ROSENTHAL

1890–1955

The life of Nathan Rosenthal is the life of the specialty of hematology, and as long as there are hematologists and laboratories of hematology, he will be remembered. This was *his field* in a very particular sense, because it developed into a specialty during the short span of his professional lifetime, largely due, to his efforts. Yet although he was a specialist and the pioneer of a new specialty, he was before that a physician, one whose first love and greatest enthusiasm was the practice of medicine, and one who will be long remembered by many hundreds of grateful patients.

Nathan Rosenthal was born in New York on March 14, 1890. He was educated in the New York public schools and was graduated in 1909 from the Central High School of Philadelphia. There was never any doubt as to his choice of profession, and he promptly entered Columbia University's College of Physicians and Surgeons.

On his graduation in 1913, there began the association with The Mount Sinai Hospital which was to serve as the cornerstone of his medical career. During his internship, another even more important association began; he met a student nurse, Anna Batt, whom he was to marry in 1922, and who was to furnish him, for the rest of his life, a loving and secure home—a refuge from the hurly-burly of professional life.

It was during his internship that he first manifested a particular interest in the study of blood. He read voraciously all the hematologic literature then available, and used and tested all the techniques he could, during the scanty leisure time available to a Mount Sinai intern. Although he finished his internship as House Surgeon, blood remained his chief interest.

From 1917 to 1919 he served in the United States Army with Base Hospital #3, first in southern France, and later at Coblenz in occupied Germany. His return to The Mount Sinai Hospital began thirty crowded and productive years. During this period he organized the Hematology Laboratory of the Hospital, the first laboratory in this country to be devoted exclusively to study of disease as it affects the blood. To this laboratory were attracted men from all over the country, and, indeed from many other countries as well. As the years went by, the study of hematology flourished, and Dr. Rosenthal became known as the dean of hematologists in the United States.

In 1938 the Hematology Department was expanded to include the blood bank—the second such installation in this country, which was started largely through Dr. Rosenthal's efforts. He was appointed Adjunct Physician in 1924, Associate Physician and Hematologist to the hospital in 1929 and Associate Clinical Professor of Medicine at Colombia University. Throughout these years

NATHAN ROSENTHAL

he was actively engaged, not only in teaching and administration, but in studies of lymphomas, leukemia, polycythemia and hemorrhagic diseases. His many publications in this field include several of major importance. He collaborated with Drs. Brill and Baehr in the classic description of follicular lymphoblastoma and his interest in this disease and especially in its cytology, continued throughout his life. Although cytology was perhaps his major interest, there is scarcely a subject of hematologic importance to which Dr. Rosenthal did not make a contribution. His enthusiasm for the unusual in medicine kept up all his life and as late as 1953, with his son Robert and Dr. O. H. Dreskin, he described a new clotting factor (PTA).

At the same time increasing demands were being made on his time by the growth of his private practice, devoted exclusively to hematology. He also organized a Hematology Service and Laboratory at Harlem Hospital to which he was appointed Attending Hematologist in 1927.

In his later years many honors came to Nathan Rosenthal. He was world-renowned and universally respected. He was awarded the Order of Carlos Finlay by the Republic of Cuba in 1952, and in 1953 was made the first recipient of the Harlow Brooks Medal of the New York Academy of Medicine.

And yet he was unchanged by all this. Throughout his life he remained gentle, humble, soft-spoken, friendly and kind. Loved and respected by his colleagues, loved and revered by his patients, this was a man of whom his co-religionists, his community and his Hospital might well be proud.

LACK OF CORRELATION BETWEEN THE ELECTROCARDIOGRAPHIC FINDINGS AND THE CLINICAL COURSE IN CORONARY OCCLUSION

HARRY L. JAFFE, M.D. AND ARTHUR M. MASTER, M.D.
New York, N. Y.

In coronary occlusion the electrocardiogram has generally been used in several ways in determining the management of the case. First, the extent of infarction and, therefore, the severity of the acute attack, have been judged from the degree of change in the electrocardiogram, particularly the number of leads showing alterations. Secondly, progressive change in the electrocardiogram has usually been considered evidence of active necrosis and, therefore, the patient has often been kept in bed or at strict rest until the electrocardiogram became relatively stationary, even when the clinical course of the patient has been mild and uneventful. Thirdly, the residual pattern of the electrocardiogram following the acute attack has been employed in evaluating the degree of recovery and the future course of the patient.

Our own experience, however, has indicated that the electrocardiogram should be used only diagnostically, whereas the severity of the attack should be judged solely on the basis of the clinical findings, i.e., the presence of persistent pain or tachycardia, or of congestive failure or shock is evidence of a severe attack (1, 2). In our experience, furthermore, it is not necessary to keep the patient in bed until the electrocardiographic pattern has become stable, since serial alteration in the electrocardiogram is a cardinal feature in acute coronary occlusion and probably is in part the result of reparative processes which begin soon after the acute infarction has occurred.

We also found no definite correlation between the electrocardiogram and the degree of recovery and ability to work in a follow-up study of 500 patients who had survived a coronary occlusion (3, 4). Of 41 per cent of patients who had made a complete functional recovery, only one fifth had a relatively normal electrocardiogram, and just as many had a very abnormal one, with large Q-waves and persistent RS-T elevation, suggesting ventricular aneurysm. The most reliable prognostic guide was the presence or absence of anginal pain or dyspnea.

The following case illustrates the lack of correlation between the degree of electrocardiographic change and the clinical course in acute coronary occlusion:

CASE REPORT

M. L., a 57 year old male, was awakened from sleep at 4 A.M. by severe substernal pain which persisted until his admission five hours later. Examination revealed a few rales at the right base. There was no tachycardia, gallop or pericardial rub. The liver was not palpable and there was no edema. The BP was 110/60, the temperature 99°, the WBC 10,800. The venous pressure and circulation time were normal. The electrocardiogram (Fig. 1, 8/8)

From the Electrocardiographic Laboratory, the Mount Sinai Hospital, New York City.

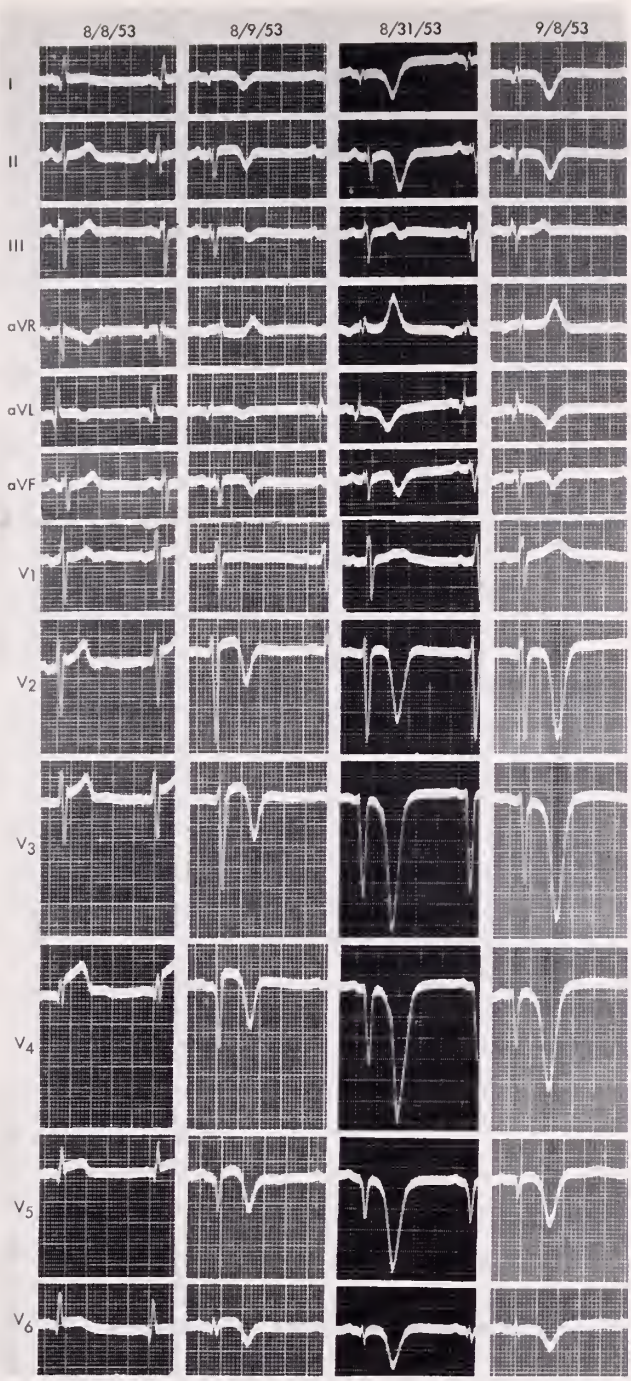

FIG. 1. M. L. m 57 (MSH 13308). Acute coronary occlusion with anterior wall infarction. First record (8/8), 8 hours after onset, showed Q-waves and ST elevation. Record taken the following day showed Q in V4, 5 and deeply inverted T-waves in all standard and chest leads. Later the T-wave inversion became extreme.

showed definite RS-T elevation in leads 1, a V_L and in the precardial leads, but only small Q-waves in leads 1, a V_L and V5, 6.

The patient was given Dicumarol for four weeks and was kept in bed for that period. The substernal pain subsided after two days and thereafter the course was asymptomatic and afebrile. At no time was there evidence of congestive failure, shock or thrombo-embolic phenomena. The sedimentation rate gradually rose to 64 mm and fell to 34 by discharge. The blood pressure rose to 120/80, the WBC fell to 9,500. The patient became ambulatory in the fifth week and was discharged after six weeks.

On the second day the RS-T elevations in the electrocardiogram were less marked, there were large Q-waves in lead 1, 2, a V_L and V4-6 and deeply inverted T-waves in practically all leads (8/9). During the following three weeks the r-wave almost disappeared in V3 and all the inverted T-waves became huge (8/31). The latter had diminished only slightly in size on discharge (9/8).

COMMENT

In this case the electrocardiogram showed changes in every lead but V_1 and were of extreme degree in most of the leads even after four weeks. If the electrocardiogram were used as a guide, it would be assumed that massive infarction was present and a severe clinical course would be expected. Actually the course was mild.

This case demonstrates that the province of the electrocardiogram in coronary occlusion is purely diagnostic and that the extent of infarction cannot be estimated from the number of leads showing alterations. The latter are the result of reorientation of electrical (vectorial) forces throughout the heart (5). The changes in any lead do not necessarily reflect electrical events in a specific, localized area of the myocardium; thus, each precordial lead does not tap only the muscle under the individual electrode. When infarction occurs, the electrical forces of that area are lost and, therefore, the vectorial forces in the opposite direction predominate. Which leads will be altered depends on several factors, but the exact number is not a reliable index of the extent of damage. This is true also of the degree of alteration in each wave, i.e., the size of the Q-wave, the amount of RS-T elevation or depression at first and the depth of T-wave inversion later on.

In view of these observations, we have relied completely upon the clinical findings, and not the electrocardiogram, in deciding when to put the patient in a chair during the acute attack, when he may become ambulatory, and when he may return to work. We have observed no untoward effects from this policy. If the clinical course is mild, following the initial pain, we have not hesitated to allow the patient to sit in a chair after the first week, or even before, regardless of the electrocardiographic findings. Such a patient begins to walk in the room by the end of the third week or before. At this time the electrocardiogram may still show mild progressive alteration. Levine has even instituted chair treatment immediately after the attack, not only in mild cases but particularly in the presence of congestive failure (6). This regimen also is carried out without taking the electrocardiogram into account. We have always individualized treatment and generally keep patients running a severe course in bed until they have improved greatly.

The majority of patients who have had a mild attack of coronary occlusion return to complete or part-time work in two or more months. At this time the electrocardiogram almost always reveals the typical pattern of the previous occlusion, with large Q-waves and inverted T-waves, even when the patient is entirely asymptomatic at work. Although occasionally the electrocardiogram returns to normal within several months, this usually takes six to eighteen months and occurs in only approximately 10 per cent of patients. As stated above, a considerable number of patients with very abnormal electrocardiograms continue working for many years, without deleterious effects.

CONCLUSION

In coronary occlusion, both during the acute attack and later on, the electrocardiogram is useful diagnostically but not prognostically. The management of the patient is determined by the clinical findings and treatment should be individualized.

BIBLIOGRAPHY

1. Master, A. M., Moser, M., and Jaffe, H. L.: Prevention and Treatment of Cardiac Emergencies and Heart Failure. Lea & Febiger, 2nd Ed., 1955, p. 110.
2. Master, A. M., and Jaffe, H. L.: Treatment of Acute Coronary Occlusion. In Press.
3. Master, A. M., and Jaffe, H. L.: Complete Functional Recovery after Coronary Occlusion and Insufficiency. J.A.M.A., 147: 1721, 1951.
4. Master, A. M., Jaffe, H. L., Teich, E. M. and Brinberg, L.: Survival and Rehabilitation After Coronary Occlusion. J.A.M.A., 156: 1552, 1954.
5. Grishman, A. and Scherlis, S.: Spatial Vectorcardiography. W. B. Saunders Co., Philadelphia, Pa., 1952.
6. Levine, S., and Loun, B.: "Armchair" Treatment of Acute Coronary Thrombosis. J.A.M.A., 148: 1365, 1952.

REFLEX HYPEREMIC DEOSSIFICATION (SUDECK'S ATROPHY)

JOEL HARTLEY, M.D.

New York, N. Y.

INTRODUCTION

Reflex hyperemic deossification is a disturbance of somatic and sympathetic reflex activity, initiated by local irritation of peripheral sensory nerves, resulting from trauma, infection or neoplasm. It is characterized by sympathetic and vascular disturbances, to which spotty hyperemic deossification is added, and frequently leads to intractable pain. Varying grades of temporary or permanent disability result. Secondary trophic changes may develop. Many consider this condition to be a variant of reflex dystrophy affecting the soft tissues of the extremities. The additional feature of spotty deossification places this entity in the group of osteodystrophies. When Sudeck first described an acute bone atrophy in 1900 (1), he designated inflammation as the antecedent cause, whereas, in the following year Kienbock (2) related the same clinical picture to trauma. Subsequently Sudeck (3) agreed that inflammation or trauma could be responsible.

The condition is known by a variety of names, such as: Sudeck's atrophy, traumatic reflex osteodystrophy, reflex trophoneurosis (Sudeck), acute bone atrophy (DeTakats), reflex nervous dystrophy, post-traumatic painful osteoporosis (Leriche).

Of all the designations for this disease, the term, reflex hyperemic deossification, used by deLorimier (4) seems most descriptive. It indicates localized areas of "active deossification in the sense that osseous constituents are actually washed out at sites of abundant blood supply. As such, it should be distinguished from the passive type of bone deficiency where there is a lack of normal stimuli for deposit of the inorganic constituents." This concept was first formulated by Pommer in 1925 (5).

The exact incidence is unknown but it has been estimated that in traumatic cases all dystrophic changes involving soft tissues and bone account for less than five per cent. If one were to include the milder changes of this type then the incidence would be higher. It occurs more commonly after war wounds than after civilian injuries.

The clinical features are well known although our knowledge of the mechanism of the underlying physiologic disturbance is incomplete. Trauma is the most common initiating factor. This may be quite minor, such as a contusion or a sprain. Fissure or occult fracture may also be responsible. Ordinary fractures or surgical procedures on bone may initiate this disorder. The changes may be at the site of the irritation or separated by one or more joints. The pain and loss of function are usually out of proportion to the degree of injury. It is more com-

From the Department of Orthopedic Surgery, The Mount Sinai Hospital, New York City.

mon in the upper extremities about the hand, wrist and forearm, but also occurs in the foot and ankle. The knee, hip, elbow, and shoulder regions are not as often involved.

Either lack of proper early splinting, too early and aggressive rehabilitation or prolonged immobilization may initiate the process of reflex hyperemic deossification. However, it rarely follows severe compound or comminuted fractures, fracture of long bones, complete severence of nerves or blood vessels or poliomyelitis. Infections in the soft tissues or bones, such as: cellulitis, osteomyelitis or infectious arthritis could be causative factors. The neoplasms are of the regional-vascular type, such as: a true giant cell tumor, or malignant-infiltrative, such as: osteogenic sarcoma or endothelial myeloma.

CLINICAL PICTURE

The clinical picture can be conveniently described in three stages (6).

I. The first stage is characterized by the onset of severe burning pain closely limited to the site of injury. At this stage the extremity is warm and dry (hyperemic). A hard, non-pitting edema usually involves the fingers, wrist, ankle or dorsum of the foot or other site of injury. The part is tender on pressure. The patient holds the part stiffly and limits motion. Trophic changes are not yet apparent. Deossification takes about four to six weeks to develop. Occasionally for some unknown reason symptoms do not develop until several months after an injury. The symptoms may stop at this stage, or the dystrophy advances to the second stage.

II. In the second stage the pain is even more severe and becomes more diffuse. The edema also involves a larger area. The part is not as warm as in the previous stage, or it may become hard, cold and cyanotic (vasospasm). Joint stiffness, muscle atrophy and spotty deossification are now more apparent. This stage is still capable of improvement after the vicious circle has been effected, in spite of the presence of severe continuous pain and contractures.

III. In the third stage the pain is intractable, and has spread to involve the root of the limb. Secondary trophic changes, such as, atrophy of skin and muscle fissuring and grooving of nails develop. Deossification progresses even further. Deossification is now diffuse and indistinguishable from atrophy of disuse, senile atrophy and other conditions. At this stage, in addition to analgesics, some interruption of nerves must be performed either by procaine block or operation.

ROENTGENOLOGICAL FEATURES

deLorimier et al. (4) have classified the x-ray findings into four patterns:

I. Discrete mottlings through a large portion of the bone or throughout several bones of a part occur. This type of deossification is especially prominent in the tarsals and in the carpals, but it also exists through the more cancellous portions of the long bones (Figs. 1 and 2). It is related to dilations of terminal branches of the nutrient artery and their anastomoses with cortical perforating vessels (as contained in Volkmann's canals).

II. Deossifications in metaphyseal zones or throughout the ends of the bones

FIG. 1. (a) Deossification of distal ends of metacarpals. (b) Relative ossification of shafts of metacarpals. (c) Deossification of proximal ends of metacarpals. (d) Generalized deossification of metacarpals. (e) Avascular state of proximal fragment of fractured carpal navicular. (f) Deossification distal end of radius and ulnar.
(Reproduced from Clinical Roentgenology, Vol. I, by de Lorimier et al. Chas C. Thomas, 1954. Through the courtesy of author and publisher.)

appear (Fig. 3). This pattern is seen particularly when dissolution occurs relatively early after insult of one sort or another. In some instances a distinct "banding" or rarefaction is found in the metaphyseal zones (Fig. 4). The explanation for this pattern is that of dilatation of the perforating metaphyseal vessels and their anastomoses with epiphyseal branches of the cortical perforating vessels of the bone.

III. Deossification beneath the subchondral articular cortices is noted (Fig. 5). This pattern is commonly found in the peripheries of the tarsals or the carpals, regardless of the irritating factor concerned. In cases of infectious arthritis it appears to be primarily concerned with the cortices adjacent to those joints involved. This type of dissolution is due to the existence of a particular dilatation of the terminal arcuate vessels which ordinarily nourish the articular cortices and the joints themselves.

IV. Progressive stages of reflex hyperemic deossification appear to be manifested by combination of two or all three of these patterns, and finally, by diffuse rarefaction which in many instances involves all portions of a bone or several bones. The explanation for these more extensive changes is a widespread dilatation and the element of time. Then too, the factor of disuse may contribute; the result being a combination of the two types of deossification reflex,

A. B.

FIG. 2. (A) Fracture of distal end of radius two months after fracture showing discrete mottling of the carpal bones, the articular ends of the metacarpals and the distal end of the radius and ulna. (B) Severe diffuse osteoporosis following chronic osteomyelitis of the tibia in a boy of 14 years. Base of proximal phalanx of the fourth toe destroyed by osteomyelitis. (Reproduced from Roentgen-diagnostics by Shurz et al. Vol. I. English translation arranged and edited by James T. Case, M.D., 1951. By courtesy of the publishers.)

together with the passive deficiency of stimulation for deposit of the inorganic constituents along the lines of stress and strain.

PATHOLOGICAL PHYSIOLOGY AND THE PROBABLE MECHANISM

Certain facts are known about the circulatory changes. In the early stages dilatation of the blood vessels with increase of local temperature and increased oscillometric readings are noted. Plethysmographic studies show an average increase of blood flow of thirty per cent. Capillary microscopy often shows dilated pulsating capillaries in the early stages (7). Deossification appears to be the direct result of hyperemia produced by vasomotor changes which result from reflexes originating in a traumatized or irritated region. Later the vasodilatation subsides and vasospasm appears. The cold, swollen part becomes prominent and remains during the chronic stage of the disease. Despite this change the deossification remains. Hence, the paradox in this later stage, of deossification accompanying vasospasm.

Psychiatric factors are extremely important in the etiology but no single personality pattern is characteristic for this syndrome (7). Functional instability

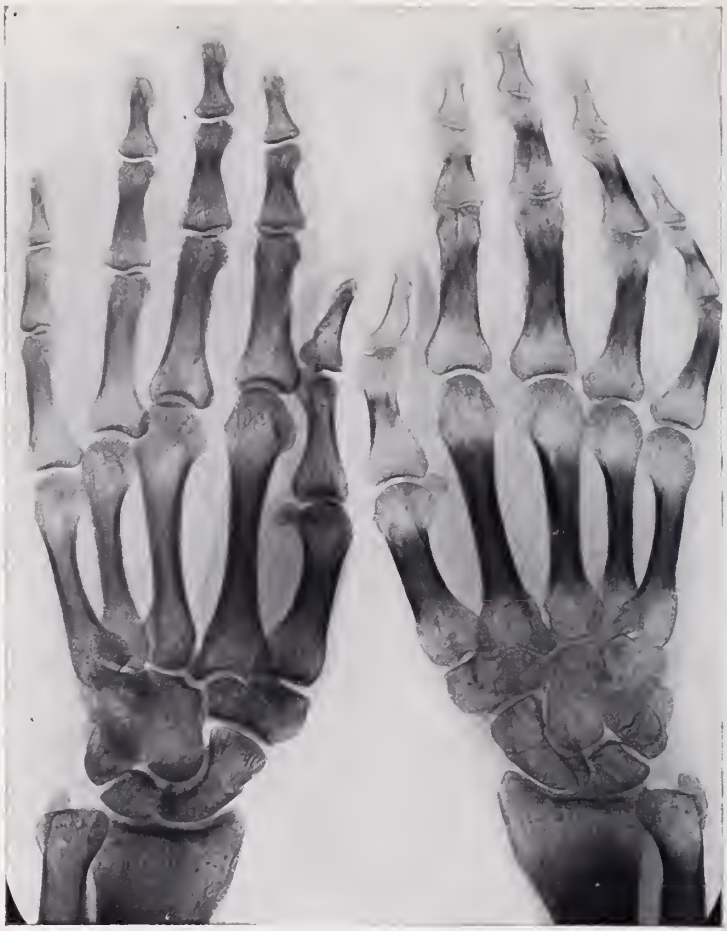

A. B.

FIG. 3. Deossification in ends of phalanges and metacarpals seen in B as contrasted with the normal opposite hand A.

(Reproduced from Roentgen-diagnostics by Shurz et al. Vol. I. English Translation arranged and edited by James T. Case, M.D., 1951. By courtesy of the publishers.)

as seen in obsessive-compulsive, anxious, hypochondriacal or narcissistic types of psychoneurotics seem to predispose the patient to this disease. Afferent stimuli emanating from a peripheral region through somatic afferent fibres causing reflex over-action of the efferent sympathetic fibres could account for many of the clinical findings (Fig. 6). Cortical and subcortical influences are definitely associated.

A unique feature of this disorder is the self-aggravating and self-maintained mechanism. The pain impulses originating peripherally at the site of irritation enters the spinal cord via sensory pathways and cause a constant re-excitation of internuncial neurones (8). Extension of stimuli to the anterior horn cells and efferent sympathetics results in muscular spasm, edema and vascular changes,

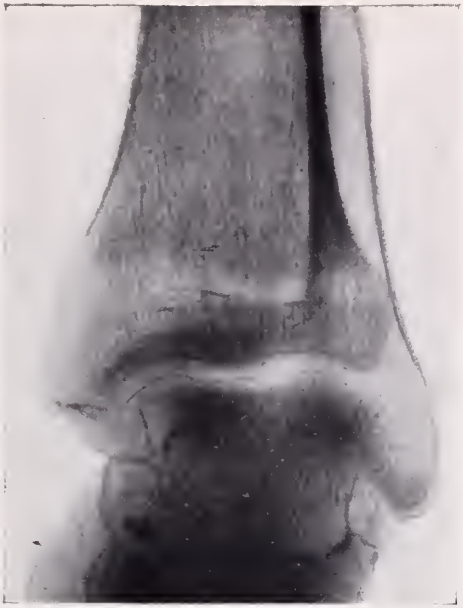

FIG. 4. Note transverse rarefaction across metaphysis,—"banding".
(Reproduced from Roentgen-diagnostics by Shurz et al. Vol. I. English translation arranged and edited by James T. Case, M.D., 1951. By courtesy of the publishers.)

which further aggravates the afferent pain impulses. Thus a vicious circle is set up. This circle must be interrupted by one means or another before improvement can be effected. In conditions, such as, poliomyelitis, tabes dorsalis and syringomyelia, where the reflex arc is broken, traumatic osteodystrophy does not occur.

Various adrenal cortical hormones may be involved in this condition but not enough is known on this aspect. Calcium and vitamin D are not significant factors. The loss of bone substance is a phenomenon secondary to pathological physiological changes and not the result of diminished intake or absorption.

There are a number of conditions which might produce a clinical picture that appears similar. The differential diagnosis includes: tenosynovitis, lymphatic edema, simple atrophy of disuse, senile or menopausal osteoporosis, tuberculosis or pyogenic osteomyelitis, peripheral neuritis or radiculitis, peripheral vascular diseases associated with intense pain, such as, arterioslerotic occlusion or thromboangiitis obliterans, x-ray bone changes after repeated hemarthrosis of hemophilia. Traumatic hysteria may be difficult to differentiate. Rheumatoid arthritis may produce a similar picture but is easily diagnosed.*

TREATMENT

The treatment consists of avoiding either too little immobilization of an injured part, too early and aggressive rehabilitation or prolonged immobiliza-

* An unrecognized glomus tumor can sometimes be deceiving.

Fig. 5. Deossification beneath the subchordral cortices of distal metacarpals and bases of the proximal phalanges. Transverse "banding" is also present at the distal ends of the metacarpals.

(Reproduced from Roentgen-diagnostics by Shurz et al. Vol. I. English translation arranged and edited by James T. Case, M.D., 1951. By courtesy of the publishers.)

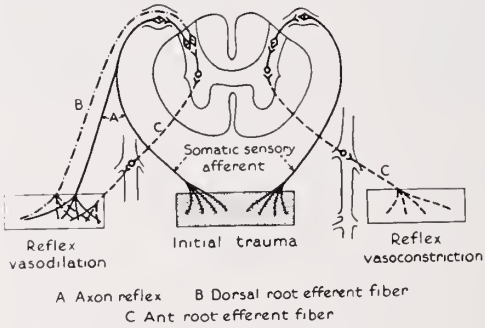

Fig. 6. Diagrammatic representation of neural pathways.

(Reproduced by courtesy of Surg. Gynec. & Obstet. from Vol. 75, 1942. Post-traumatic Dystrophy of the Extremities by Donald S. Miller & Geza de Takats.)

tion, if possible. Early recognition of the entity is extremely important. Graded active exercises, weight bearing and general gradual rehabilitation should be instituted promptly. The usual forms of heat and massage either aggravate the condition or do no good. The physician should play an active persuasive role in managing and encouraging the patient. Repeated or continuous sympathetic nerve blocks may be quite helpful but sympathectomy and periarterial stripping

should be reserved for later use in difficult cases. Repeated local procaine injections to relieve pain will aid greatly. Hydrocortone injections may also be tried. Vasodilator drugs may be employed if vasospasm is present. Calcium and vitamin D are of no value. Claims have been made for radiotherapy (9). Analgesics play a useful role. Where compensation neurosis seems to be a factor, early settlement is desirable, since it is known that cortical and subcortical influences are a factor in aggravating a Sudeck's atrophy or in causing a similar type of clinical picture. A psychiatric approach is invaluable. Active, persistent physician persuasion and encouragement towards recovery must be consistently applied. The patient should not be completely turned over to a physical therapist. The physician should maintain a personal interest and should check the patient's progress frequently. Many of these patients present obsessive-compulsive personalities and respond to a very specific regime, with detailed instructions. A schedule stating the exact time at which the exercises should be performed and the exact number of motions per session will be more successful than vague instructions. Some of these patients as they recover from the musculo-skeletal condition begin to develop some of their old intestinal symptoms. When returned to their family physician, they may be the same psychoneurotics they were before, but at least the reflex hyperemic deossification has been cured. Frequently a physician alert to the early evidences of traumatic osteodystrophy can prevent the development of a full blown case. Cordotomy for relief of intractable pain or amputation should only be considered as a last resort in severe chronic progressive cases that fail to respond to all other methods.

Thus, we have a condition which is initiated by some local irritation; which proceeds from a mild form of neurovascular and osseous change, hyperemic at first, and later vasospastic, to a stage of progressively increasing pain and trophic change. At any stage in its course it may improve spontaneously or as a result of therapy. Varying degrees of residual permanent disability may result. In rare instances, because of severe unremitting pain, neurosurgical interruption of neural pathways or even ablation of the part is necessary (10).

DISCUSSION

How are we to regard this peculiar entity? What is its relation to normal physiological mechanisms? What is its relation to other pathological states? We have already indicated that reflex hyperemic deossification is part of a larger group of reflex dystrophies or causalgic states which involve only the soft tissues. The feature of deossification establishes a separate sub-group. The lesion usually involves the hand or wrist or the feet and ankle. But it can involve the knee, hip or shoulder.

What is the relation of osteodystrophy to the mild degree of deossification and post-traumatic edema usually expected in common injuries? Is it not reasonable to suppose that the acute stage of traumatic reflex osteodystrophy represents an unusual acceleration of the normally occurring response to injury or irritation? Watson-Jones doubts whether the condition exists, except as the result of neglected disuse changes (11).

The concept of hyperemia as the cause of the localized roentgenographic

changes, as mediated via the special anatomic relationship of the circulatory system in bone, is very convincing (5). Blair theorized that *alternating* ischemia and hyperemia caused by contraction and relaxation of skeletal muscles has the effect of maintaining normal calcification of bone and aids in the healing of fractures (12). This differs from a persistent hyperemia which Pommer feels is the cause of the localized roentgenographic changes.

But why should blocking of the sympathetic fibres which causes increased blood flow, a prominent finding in the early stages, relieve pain? It is generally considered that pain travels along the sensory nerves only. However, it is an established clinical fact in humans that interruption of sympathetic nerve fibres can relieve pain. Although afferent sympathetic fibres from the *somatic zone* have not been demonstrated, as have *visceral afferent fibres*, there is reason to believe that sympathetic somatic afferent fibres exist. Pinching of periarterial tissues causes pain.

Is there any relationship of osteodystrophy to the alarm syndrome in bones in which an extensive generalized osteoporosis develops following a fracture or blunt trauma to an extremity without fracture (13)? In the alarm syndrome there develops a severe disturbance of protein metabolism under the influence of an increased mobilization of adrenal cortical hormone. Organic matrix, the scaffold for mineral deposition, is removed from bone and there is a concomitant loss of calcium and phosphorus. Does an adrenal cortical hormone offer a clue to the mechanism of reflex hyperemic deossification? Since the alarm syndrome is diffuse, whereas, reflex osteodystrophy is local, they appear to be two distinct entities.

It is obvious from this review that we know a good deal about reflex hyperemic deossification. The clinical picture is certainly distinct. However, there are wide gaps in our knowledge concerning details of mechanism. We don't know exactly why one patient develops this condition and another does not. Once recognized, the patient usually can be helped along the road of recovery. As in so many other conditions prophylaxis or early recognition is important.

REFERENCES

1. Sudeck, P.: Ueber die akute (reflektorische) Knochenatropie. Arch. f. Klin. Chir., 62: 147, 1900.
2. Kienbock, R.: Ueber akute Knochenatrophie bei Entzundungsprocessen an den Extremitaten (falschlich sogenannte Inactivitatsatrophie der Knochen) aud ihre Diagnose noch den. Rontgenbilde. Wien Med. Wchnschr., 51: 1345, 1901.
3. Sudeck, P.: Ueber die akute (reflektorische) Knochenatrophie nach Entzundungen und Verletzungen an den Extremitaten und ihre Klinichen Erscheinungen. Fortschr a.d.Geb.d. Roentgenstrahlen 5: 277, 1901-02.
4. deLorimier, A. A., Minear, W. L., and Boyd, H. B.: Reflex Hyperemic Deossification Regional to Joints of the Extremities. Radiology, 46: 227, 1946.
5. Pommer, G.: Ueber Osteoporose ihren Urspoung und ihre differential diagnostiche Bedeutung. Arch. f. Klin. Chir., 136: 1, 1925.
6. DeTakats, Geza: Nature of Painful Vasodilatation in Causalgic States. Arch. Neurol. & Psychiat., 50: 318, 1943.
7. Miller, D. S., and DeTakats, G.: Post-traumatic Dystrophy of the Extremities—Sudeck's Atrophy. Surg., Gynec. & Obstet., 75: 558, 1942.

8. Winter, S.: Sympathetic Reflex Dystrophies in Coronary Heart Disease. N. Y. State J. Med., 54: 2330, 1954.
9. Mumford, E. B.: Roentgeno-therapy in Acute Osteoporosis. J. Bone & Joint Surg., 20: 949, 1938.
10. Pain Syndromes and Their Treatment. James M. Tarsy, M.D., Chas. Thomas. Springfield, Ill. 1953.
11. Watson-Jones, R.: Fractures and Joint Injuries. P. 55, Vol. I, 4th Ed. Williams & Wilkins Co., Balt. 1952.
12. Blair, H. C.: The Alternation of Blood Supply as a Cause of Normal Calcification. Surg., Gynec. & Obstet., 67: 413, 1938.
13. Selye, H.: The General Adaptation Syndrome and the Disease of Adaptation. A Critical Survey of the Literature. J. Clin. Endocrinol., 6: 117, 1946.

PSYCHODYNAMIC ASPECTS OF BEHAVIOR IN OCCUPATIONAL THERAPY

LEONARD A. WEINROTH, M.D., AND FRED BROWN, PH.D.
New York, N. Y.

To a great extent occupational therapy is still not accorded the position it deserves in the total management and evaluation of psychiatric patients. Many psychiatrists feel that occupational therapy has no therapeutic significance but is provided in psychiatric hospitals and on psychiatric services chiefly in order to keep patients busy. The formal psychotherapeutic interview is accorded its deserved central position in the treatment of patients to the relative exclusion of other sources of information, among them occupational therapy. There are several reasons for such an attitude but they will not be discussed in this paper.

Actually, we are not concerned primarily with the therapeutic possibilities of occupational therapy. The utilization of this source of data to facilitate patients' insight and/or as an integrative experience, does not enter the scope of this study.

This is a report on two cases, wherein an attempt is made to arrive at a formulation based upon occupational therapy projects. These formulations are then compared with the clinical findings and psychological tests. The emphasis is on a comparison between utilization of occupational therapy as an expressive device and the usual psychological tests. When occupational therapy is non-directive it becomes such a technique, for when patients select their projects without any outside guidance their choices are unconsciously determined by their needs even though there is often also a conscious, rational set of reasons for the choice. Not only is the choice of the project thus determined by unconscious forces, but so is the time of its selection, manner in which it is approached, the quality and speed of the workmanship, the recipient of the article, etc.

Transference manifestations, ego defenses, and drives can often be observed in the work patients do. Relationships with siblings and parents and their repetition with hospital personnel and other patients will also manifest themselves through the medium of occupational therapy. Guilt, narcissism, masochism, sadism and greed are frequently observed. It would seem to be a partially non-verbal way of expressing conflicts and attitudes.

CASE #1

Mrs. D.S. was 42 years old at the time of her admission to the psychiatric ward of the Mount Sinai Hospital. About five years before her admission she developed sinusitis. According to the patient, her husband refused her permission to visit a doctor. Presumably, as a result of this neglect she developed pain in her cervical spine which eventually radiated to her left upper extremity, and finally included her right hand. After an unsuccessful application of a variety of treatments she was operated upon for the removal of a protruding intervertebral disc. The operation revealed no abnormality. Following the operation her

From the Department of Psychiatry, The Mount Sinai Hospital, New York, N. Y.

pain became more severe and incapacitating. Further neurological study revealed osteoarthritic changes in the cervical spine, which, in the opinion of the neurologists, could not cause pain of sufficient intensity to incapacitate her to the degree reported by her. The possible connection between her sinusitis, which was not observed and diagnosed by a physician, and her osteoarthritic changes, was present in the patient's mind, but could not be explained anatomically and/or physiologically, including the concept of focus of infection.

A few years before this series of symptoms, she experienced a period of gastro-intestinal complaints. Nausea, vomiting and diarrhea constituted this series. At that time also no organic pathology was present.

Her home life was completely unsatisfactory. She had begun to withdraw from social contacts for some time before the appearance of her symptoms. She stopped seeing the many women friends with whom she had socialized. This group of women often met men at bars, drank with them and went out with them. However, the drinking was not excessive and the dates were purely social. She had enjoyed dancing a good deal, just like her father who was a good dancer in spite of a leg crippled by poliomyelitis. The time she spent with her husband was minimal because he worked nights. He chose this shift some years previously following his recovery from a serious automobile accident wherein he sustained a number of fractures. While he was asleep during the day, the patient sat in the house and did a good deal of sewing and knitting. With the passing of the years husband and wife withdrew from one another to an even greater extent. The patient made an attempt to get closer to her only child. When he became an adolescent they discussed their sexual preoccupations. Her conscious feeling was that she was helping him in a difficult area, but in reality this had the characteristics of a mutual incestuous titillation. The boy grew up to be quite disturbed and was receiving psychotherapy at the time of the patient's admission to the hospital.

She accused her husband of being responsible for her withdrawal from friends and from him. He did not offer her any companionship or sexual gratification, but she made no attempt to enlist his cooperation in building a satisfactory family life. In fact she even tolerated and indirectly encouraged his friendship with a widow.

She became increasingly sad and cried often. She was a markedly sensitive person and reacted to real or imagined slights and insults by regressing to even greater inactivity. Eventually the pain in her hands became the signal for such a withdrawal. As soon as the pain appeared she stopped her work, got into bed and complained about her suffering. In this area, as well as in the relationship with her husband, there was no active attempt to seek a solution to her problems. Through her complaints the responsibility for the management of her illness was thrust entirely upon her environment. There were no prominent suicidal thoughts nor any conscious guilt or self-accusatory ideas.

Her past history was quite consistent with such an attitude toward life. She was born in a rural community as the fifth of ten children. She felt her mother to be an unloving and demanding person who expected her to bring up the younger children. This was experienced by the patient as an imposition. Accusations of incompetence were levelled by her mother against her on many occasions. For instance, she recalled chopping wood when the axe flew off its handle and injured a younger brother's head. She was accused of being responsible for this injury, and her brother's subsequent poor intellectual development was attributed to it.

One of the conscious images she had of her father was that of a happy man who liked to play the fiddle and to dance. However, there is ample direct and indirect evidence in her anamnesis that he too was a disappointing parent.

She was obliged to go to work at the age of 14 years because of poor family finances. At the age of 17 years she left home to work as a servant. At that time she had a series of superficial flirtations with young men, none of which developed into anything meaningful. Her behavior was most probably an attempt to imitate her father's lighter moments as a manifestation of her identification with him.

She was diagnosed as being a markedly narcissistic person in that she expended a minimum of libido on objects in her environment and was constantly preoccupied with herself.

Part of the narcissism assumed the form of complaints about her unfortunate lot in this world and part of it expressed itself through somatic symptoms. She was thought to be passive and masochistic in that she did not feel called upon to alter her internal and external environment. Suffering became her way of life, except for short moments when she was able to indulge in superficial and hysterically colored flirtations. Behind these traits were her chronically ungratified dependency needs and a great ever-present need to be loved. This was brought about by the demands her mother made upon her and her inability to turn to her father because of his indifference.

Her chief defenses were thought to be regression, projection, identification, somatization and displacement. Her most prevalent affect was that of depression.

Occupational Therapy Activities. During the first two to three weeks on the ward the patient did very little. She spent most of her time in bed, complaining of pain in her arms and hands. She was quite intolerant of any feelings she might have and promptly regressed to an intensification of her symptoms. As she began to be more accustomed to the atmosphere on the ward and more friendly with the other patients, she decided to go up to the occupational therapy shop to choose some project. By this time she had already seen many things that other patients were making. In addition, she saw still other projects in the sample case in the shop. Unlike many other patients she decided to make what she called a Dutch boy doll, which in reality was not Dutch at all. It had blond hair with blue eyes and wore a jacket and long trousers (not pantaloons) trimmed with material of a lighter color. The work progressed very slowly because of the pain in her hands which recurred quite often and for protracted periods. The unfinished doll was kept covered with a cloth in a box on her table. The facial resemblance between the doll and the patient was quite striking to everyone except the patient. When this resemblance was called to her attention, she denied it with some resentment. She had a good deal of difficulty in sewing the dolls neck and told the occupational therapist about it. When, after many weeks, the doll was finished, she decided to make a second one just like the first. She announced that her second doll would definitely not look like her. Nevertheless, it looked very much like the first one. However, the second was made in a much shorter period of time; she had no difficulty with the neck and the colors of the trimmings were brighter and gayer. The third and last of her dolls resembled the first two but was dressed in girl's clothes.

During this period she also made many ladies hats, bow-ties, and aprons. Much of the material for these things was brought to the ward in boxes by the husband of one of the patients. Some of the patients took whatever they could as soon as the material was brought, whereas Mrs. C. stood by wistfully and waited until the other patients took all they could and then she took the material that was left.

During the latter part of her hospitalization she painted on a tile a ballet dancer standing on the toes of one foot and the other leg lifted to a horizontal position. This, she said, was a representation of a friend of hers who actually was a dancer. Then she painted a seductive Spanish dancer on another tile. She had to ask for the occupational therapist's help in painting the dancer's necklace, hands and thighs.

After a good deal of deliberation she gave the boy-dolls to her husband's nephew. Some of the ties, aprons and hats were distributed among the nurses and doctors. The tile with the Spanish dancer was intended for the psychiatrist, whom she thought she had offended a few weeks earlier.

Comment on Occupational Therapy and Psychological Findings. In presenting the inferences derived from her occupational therapy behavior it will be instructive to interpolate statements from the psychological report which support these formulations. This has special significance when it is known that the test findings were interpreted without prior knowledge of the patient's history.

The resemblance of her dolls to the patient was interpreted as narcissism. This interpretation was made before the clinical impression was known to the

authors. This impression was strengthened by the fact that all three dolls resembled one another. The embroidery of such self-images was rarely observed in other patients.

("*In summary, this is an oral dependent, narcissistic and infantile individual. Each of the human figure drawings shows an awkward and highly atypical rendering of the neck region*").

Her hostility toward her husband was manifested by the fact that whereas she gave these dolls to his nephews, she made nothing for him during her entire stay on the ward. Undoubtedly he was aware also of the fact that she made a number of things for ward personnel and for her son.

("*On the one hand she is orally receptive, and on the other, she shows oral sadistic trends which are coupled with her castrative and depriving impulses*").

Her greed was demonstrated through the large number of projects that she made, even though she did not work for long periods of time because of pain in her hands. She did not distribute these things among patients, thus suggesting that she was attempting to curry favor with personnel, that is, people in authority.

("*Yet this woman is striving to maintain contact with others, however tenuous her resources for such contact may be, although the need to be a child, to cling and be dependent on her family is very overwhelming*").

She was able to gratify her wish for a variety of things, when she was able to get them in the shop upon request, but when she had to fight for material with other patients, she stood on the side-lines. The expression of overt aggression was impossible for her. Her oversensitivity prevented her from being actively aggressive. Whenever she developed a new exacerbation of symptoms she stopped working and got into bed, thus giving expression to her dependency needs. In effect, she was saying that she was incapable of working and that if the work was to be done, others were expected to do it for her.

("*Like a little child, she views the world from the standpoint of what she can obtain from it in an orally incorporative sense*").

The very same cessation of activity, resulting from an intensification of her pain, was an expression of her masochism. This turning of aggression against herself represents a very prominent trait in her personality. It is permissible to speculate that it was guilt, among other things, which prevented her from keeping most of the things she made. This was in striking contrast to the behavior of some other acquisitive patients, who kept everything for themselves. Her masculine identification found its expression in the maleness of her first two dolls.

("*She is considerably confused as to which role she must play*").

It was also quite instructive to observe that with the passage of time she finally made a female doll. In the protective atmosphere of the ward she was able to relinquish, if only temporarily, this mechanism of defense. During the period of relaxation the colors of her dolls' clothes became gayer, her depressed mood disappeared almost entirely and she became elated at times. This elation was expressed largely as flirtatiousness which she recorded through her two

dancers on tiles. These tiles express her identification with her friend the dancer. However, she was already serving notice that her flirtatiousness was spurious. She had difficulty in painting her Spanish dancers' hands and thighs, as though she were saying that masturbation and sex were frought with conflict.

(*"She can pose as a woman, but this is only a façade in which seductive mannerisms substitute for genuine emotional give and take; vaginal intercourse is experienced as a hostile and aggressive act and some sexual relief is undoubtedly achieved by masturbation. Several thematic appercception test stories related by this woman are indicative of discord in the marital relationship. There appears to be a great concern with the pelvic area, suggesting marked sexual conflicts: this patient attempts to evade genitality"*).

Finally the alteration of her body image, resulting from the operation, was indicated in her difficulty in sewing the doll's neck and in asking for help in painting the Spanish dancer's necklace.

CASE #2

The second case is that of Mrs. H. M. a 20 year old married woman who was admitted to the hospital during an attack of ulcerative colitis. She was acutely ill upon admission.

The patient developed her illness several months previously when her only child, a boy, was six months old. She was quite incapable of taking care of him and handed over most of the chores to her mother. Changing her boy's diapers was disgusting to her. She quarrelled with her husband a great deal because he was more interested in his family's welfare than in hers. They had had no sexual relations for some time past because of her complete frigidity.

During her pregnancy her weight had risen from 125 pounds to 185 pounds. After a few months of illness she weighed only 72 pounds, but shortly thereafter there was a turning point in her illness and she regained much of her weight rapidly. Her weight loss was probably more a result of marked anorexia rather than of frequent bloody bowel movements and fever, although they also were important. Other upper gastro-intestinal symptoms, such as nausea and vomiting also figured rather prominently in her illness. During the period of her greatest weight loss she was deeply depressed, staying in bed all the time and talking to almost no one. She was quite convinced that she was going to die. Although her mood eventually showed great improvement, she could not be considered a care-free person. She laughed and teased, but was not content. She chewed her finger-nails, warts, and lips to the point of bleeding. These were old habits of hers. In addition to her gastro-intestinal disturbances she manifested other disturbances of the vegetative nervous system. She blushed often and perspired profusely. The palms of her hands were cold and wet.

The patient was the oldest of three siblings in a family where the parents were perpetually quarreling. One brother was born when she was eighteen months old. When she was four years old, her father went to jail because of theft. During the eight years the he was in prison she slept with her mother. When he was released, the patient left her mother's bed and joined her brother. She slept with him until she began to go out with her husband at the age of 17 years. Her younger brother was born one year after her father came out of prison. She was more or less expected to raise this boy, which she did with mixed feelings.

Until the age of 12 years she was quite outgoing, had many friends, and participated in varied activities, especially in school plays. At about that age a number of things had occurred: she learned about sexual intercourse from her friends, she began to menstruate, and her father came out of jail. From that time on she became withdrawn and began to react with diarrhea and vaso-motor hyperirritability to many different situations. Whereas as a child she was a poor and finicky eater, she tended to put on excessive weight from this time on. She was always a rather dull student but enjoyed reading popular novels a

good deal. She was a fast reader. Until the age of 12 years, when she became inhibited she enjoyed participating in school plays and was apparently quite good in them. From that time on, however, she was forced to give up this activity.

It was the clinical impression that the patient was a narcissistic, infantile individual. Her ambivalent dependency upon her mother was substantiated by a great deal of clinical material. Her hostility toward men was quite apparent. Masochism was thought to be particularly pronounced. Regression, somatization, identification with a hostile mother, reversal of affect were some of her more apparent defenses.

Occupational Therapy Activities. During the first few weeks of her stay at the hospital she worked a good deal. She made a number of wallets, change purses, key cases and key chains. She made a few gun holsters and copper jewlery out of copper wire. Most of these things she distributed among her mother, mother-in-law, husband, brother and some cousins. Some of the copper jewelry was for herself. She made a bracelet for herself which was much too large for her thin wrist. The reason she gave was that she hoped to gain weight to make it fit. The work was of good quality, but she often asked for help where a fair amount of physical effort was required, such as punching holes in leather. During the same period she also made a clown out of jersey material. It was stuffed with cotton by another patient because she became anxious even at the thought of doing it herself. An animal that she made for her baby boy also was stuffed by someone else. When she was told that her child attempted to put the animal's head into its mouth, she was unable even to sew the material together for these stuffed animals.

During the many weeks of her depression which followed the period referred to in the above paragraph, she lay in bed almost motionless. Occasionally she reminded the occupational therapist that she had many unfinished projects and that she would finish them when her health improved. This was a period of marked regression. Then a change in her mood occurred concomitantly with a change from a negative to a positive transference. She became active again. During this period she made two more clowns which were not stuffed. The facial expression of all three clowns was the same. She described it as "mischievous." Moreover, there was a peculiar angularity about their features which resembled her own when she was very thin. All of these clowns were taken to her home. One of them was very small and the other one extremely large.

She made another attempt at making a stuffed animal. Again she found the stuffing difficult to do, but she was able to proceed with it. She was amazed at what she considered the large quantity of cotton that was accommodated by a small animal. Eventually, she tore the material and threw the toy away.

Then she was knitting a sweater for her husband. After making a large part of the sweater, she was dissatisfied with it, ripped it and used some of this wool to make a fluffy dog. In the meantime she also made a number of leather things which she distributed among various members of her family. Finally, just before leaving the hospital she made two beautiful clowns for her therapist's two children.

Just as she had a need to have her mother take care of her baby, so she also got various people on the ward to help her with some of her projects. Often, instead of going up to the shop by herself, she expected other patients to bring some material to her. This passive receptive orientation was, of course, intensified by her illness.

("*The patient's intense feelings of inadequacy and helplessness extend into the intellectual sphere and make problems in that area threatening to her. Her anxiety tolerance can be fairly easily bolstered by a highly dependent and child-like relationship. Essentially an oral demanding person, the patient's recent sporadic efforts to establish independence have led only to the intensification of her feelings of helplessness and inadequacy*").

Her hostility was mostly apparent in regard to her husband.

("*She tends to be exhibitionistic. . .preoccupied with fantasies of being beautiful*

and of going out and having a good time. These are probably also compensations for her disappointment with married life. She tends to overreact in close contacts in an oral aggressive manner which is detrimental to her marital relationship"). She was going to make a sweater for him but changed her mind, ripped it, and made a fluffy dog instead. The making of guns, holsters, even though her child was only six months old, was also suggestive.

As so often happens in oral, dependent characters, her regression manifested itself by inactivity, among other things. Even though there is ample clinical evidence of her hostility toward several members of her family, she gave them many of the things she had made. Her dependency needs account for this generosity. It was her way of holding on to her ambivalently loved objects.

("*Intense hostility is harbored especially toward the mother and husband which she cannot express directly because of her ambivalence toward them and her guilt feelings*"). When she was with them she fought with them. When she was away from them, she had to hold on to them.

Her oral greed was demonstrated by the fact that she gave none of her things to personnel, even though she was on the ward for a long time.

(". . .basically an infantile, oral dependent character. . . .").

Her great need to incorporate orally was shown in her voluminous and fast reading. She indicated her orality in this symbolic manner, but felt much too guilty to stuff animals, because this was too reminiscent of actual eating. On theoretical grounds, it is fair to assume that the difficulty she had with stuffing represented her hostile identification with mother.

("*Essentially she seems to identify with the mother. Because the patient feels that her mother has failed to give her sufficient oral succourance, she feels hostile towards her*").

Making clowns that looked mischievous was a kind of denial of her underlying depression.

("*Handles anxiety by resorting to a highly childish relationship, tending to becloud issues with cute kittenish behavior and comments. Though the patient has some mood swings, she appears to suffer from a chronic underlying depression which, while partly accepted with fatalistic resignation on one level, is denied and avoided by flights into adolescent fantasies of wealth and adventure on another*"). The fact that they ranged in size from small to large was an echo of her preoccupation with her own body size, which became so much smaller during her illness, as well as during her adolescence.

DISCUSSION

The occupational therapy and psychological formulations were arrived at independently by the psychiatrist and the psychologist. We were impressed by the parallelism between the two sources of data, and deliberately chose such cases from our material for a preliminary publication. We were interested in conveying the idea that occupational therapy often can serve as an important supplement to the standard psychological tests and we felt that cases which show such a parallelism would best demonstrate this.

In some of these cases psychological tests revealed much material which was not obvious in the occupational therapy projects, at least during the period of observation. There are also instances where the opposite is true, which should not be surprising. After all, even several psychological tests do not always reveal the same data. In a given case the Rorschach test may uncover the drives more than the ego defenses and the thematic apperception test will demonstrate the defenses more clearly.

The authors are fully aware that the temptation to make things fit is great in such a study and made a serious attempt to overcome this pitfall. Moreover, it is impossible to dissociate occupational therapy from other manifestations of behavior. The observers cannot help being influenced even if ever so subtly by these manifestations. In spite of these and other possible sources of contamination of judgement we felt it worth while to publish such a report, if for no other reason than to stimulate further interest in occupational therapy as an expressive diagnostic approach.

POSTERIOR FOSSA HEMATOMAS

SIDNEY W. GROSS, M.D.

New York, N. Y.

Posterior fossa hematomas of traumatic or spontaneous origin are uncommon. It is of interest to record the following case histories of posterior fossa hematomas in the extradural space, the subdural space and in the substance of the cerebellum. The first case* is that of a posterior fossa extradural hematoma.

A young man of about 20 was standing in the back of a truck which started suddenly, throwing him to the pavement. He lost consciousness immediately and, in this condition, was admitted to the hospital. A very slight abrasion was present on the scalp just above the inion. The pupils were equal and reacted well to light. A bilateral positive Babinski was present. Within 2 hours the patient became more alert and he responded to simple commands. However, he became quite restless. A spinal tap was done and the cerebrospinal fluid was found to be grossly bloody and under 120 mm. of pressure. During the next few hours he seemed to improve, when suddenly he became cyanotic and stopped breathing. In spite of emergency measures, the patient died.

Post-mortem disclosed a linear fracture of the skull beginning 5 cm. above the inion and extending straight down the midline to the foramen magnum. An extradural clot 8 x 6 x 2½ cm. covered the dura over the right cerebellar hemisphere and the pole of the right occipital lobe. A tear was present in the right lateral sinus near the torcula. In addition, small subdural hemorrhages were found over each temporal lobe. The ventral surfaces of the frontal and temporal lobes were moderately contused.

Extradural hematomas in the posterior fossa are rare. According to Kessel (1), up to 1938 when he reported the first successful case, he was unable to find another successfully operated case at that time. McKenzie reported a case in 1938. His patient, a child, sustained a slight head injury. After a symptom-free period of 30 hours, flaccidity of all extremities developed along with stupor. Fourteen hours later the patient died. Autopsy disclosed a 1-inch fracture of the occipital bone and an extradural clot compressing the right cerebellar hemisphere. McKenzie (2), in a review of the literature, found 19 other cases of posterior fossa extradural clots, all discovered at autopsy.

In 1941 Coleman and Thomson (3) reported the case of a 9-year old boy who fell from a moving truck, striking the back of his head. The only sign of injury was a small hematoma in the left occipital region and he was sent home. Twenty-four hours later he became drowsy, restless and he vomited several times. During the next 15 hours, his condition worsened. An X-ray showed a midline skull fracture extending from the lambdoid suture to the foramen magnum. Passive neck movements were painful and hypotonia and areflexia developed. At operation, an extradural clot 3 cm. thick was found over both cerebellar hemispheres. The bleeding came from a tear in the torcula. The patient recovered.

Kessel's (1) patient was thrown from her bicycle and struck the back of her head. X-rays showed separation of the left half of the lambdoid suture. The

From The Department of Neurosurgery, The Mount Sinai Hospital, New York, N. Y.

* Previously reported by Gordy, P., J. Neurosurg., 5: 294, 1948.

outstanding symptom in this patient was the cerebellar or "rigid" fits which developed about 30 hours after the accident. These were characterized by retraction of the head, rigidity of all four limbs, cyanosis, irregular breathing and loss of consciousness. Similar fits are occasionally observed in patients with cerebellar tumors, and are most likely closely related to decerebrated rigidity.

There are three sources of extradural hemorrhages, viz., the meningeal arteries, the diploic veins, and the venous sinuses. Most supratentorial extradural hemorrhages are of arterial origin. On the other hand, those occurring in the posterior fossa are nearly always due to tears in the transverse sinus or one of the veins draining into it. The posterior meningeal artery, a branch of the ascending pharyngeal artery, along with a meningeal branch of the vertebral artery supply the dura of the posterior fossa. It is possible that laceration of these arteries might cause extradural hemorrhages in the posterior fossa. However, I have not been able to find a report of such an occurrence.

Anderson (4), in 1949, reviewed the literature and added his own case. From a study of the report in the literature and my own observation of 1 patient with an extradural hematoma in the posterior fossa, any of the following symptoms and signs should make one suspect such a lesion:

1. A history of a fall or a blow to the back of the head with or without loss of consciousness;
2. Followed by headache, vomiting, dizziness and a tendency to lie on one side;
3. After a variable period, sometimes several hours but not infrequently several days, "rigid" fits and lethargy develop.
4. On examination, nuchal rigidity, nystagmus, ataxia, hypotonia and often, papilledema are found.
5. X-rays of the skull usually show a fracture of the occipital bone crossing the transverse sinus.

As far as treatment is concerned, lumbar puncture should be avoided and exploration should be undertaken as soon as there is adequate evidence to warrant the diagnosis. Since extradural hemorrhages of the posterior fossa may be associated with extradural clots over the occipital poles, in every case a burr hole should be made above the transverse sinus.

The second case is that of a patient with a chronic subdural hematoma in the posterior fossa. This was a woman of 51 at the time of her hospitalization in 1949. She complained of back pain and left lower extremity pain of four months' duration, and of staggering to the left of four weeks' duration. In addition, she had had occasional frontal and occipital headaches during the seven weeks prior to admission. She walked on a broad base. Early papilledema and nystagmus on left lateral gaze were present. A ventriculogram showed marked dilatation of the entire ventricular system including the aqueduct and fourth ventricle. At operation, a chronic subdural hematoma was found over the right cerebellar hemisphere. The patient improved and, when seen one year later, she had no complaints and appeared to be in good health.

In 1940 Coblentz (5) reported the first case of posterior fossa subdural hematoma suspected clinically and treated surgically with recovery. At that time, he was able to find only four other cases of posterior fossa subdural hematomas, all

found at autopsy and not recognized before death. Since then, only three or four additional cases have been reported. It would appear then, that subdural posterior fossa hematomas occur much less frequently than extradural infratentorial clots. Above the tentorium, the reverse is true. This has an anatomical basis since the venous drainage from the cerebellum does not involve cortical veins which drain into dural lacunae such as are found above the tentorium.

Posterior fossa subdural hematomas occur so infrequently that it would seem unwise to venture a pre-operative diagnosis or to attempt to delineate a clinical syndrome.

The third patient had an intracerebellar hematoma. This case was a male bank teller, 63 years old. He had had hypertension for at least ten years but, except for headaches from time to time, he had never been seriously disabled by his disease. On November 21, 1948, after climbing a steep hill, he suddenly complained of dizziness, nausea and faintness. He was able to drive his car home, but on arrival there he collapsed and had to be carried to bed. On attempting to walk he fell to the left and forwards. His speech became thick and garbled and he complained of blurred vision. On admission to the hospital, November 28, 1948, he appeared acutely and severely ill. He was unable to stand or walk. When he tried to sit up, he fell to the left and backwards. There was marked ataxia and incoordination in the left upper and lower extremities. The deep tendon reflexes were all hyperactive. Plantar flexion was absent on both sides. The abdominal reflexes were absent on the right. The fields and fundi were normal. Horizontal nystagmus was present in all directions of gaze, but slower and coarser on left lateral gaze. Blood pressure, 220/120. Lumbar puncture yielded a clear fluid under a pressure of 210 mm. An acute spontaneous intracerebellar hemorrhage was suspected. Bilateral posterior ventricular puncture and air injection were done. The ventricles were slightly enlarged. The tentorium on the left side was slightly elevated. An opening was made over the left cerebellar hemisphere. Exploration with a cannula yielded a chocolate-colored fluid about 1 cm. below the cerebellar cortex. A transcortical incision was made, and a clot the size of a golf ball was found and removed. Except for troublesome hiccough, the patient had a relatively smooth post-operative course. At the time of discharge on December 10, 1948, the patient was able to walk with assistance. He continued to improve and, but for slight left-sided ataxia, there were no residual findings.

In 1942, Mitchell and Angrist (6) reported 15 examples of spontaneous cerebellar hemorrhage discovered at autopsy. In their fairly comprehensive review of the literature, they were able to find 109 additional cases. They concluded that spontaneous cerebellar hemorrhage is similar to cerebral hemorrhage in incidence and that the contributory pathological factors are the same. They attribute the apparent infrequency of cerebellar hemorrhages in part, at least, to the failure to investigate adequately cases of sudden death. In 21 instances of spontaneous intracranial hemorrhage, where death occurred outside the hospital, cerebellar hemorrhages were found in seven. In a series of 115 cases of spontaneous intracranial hemorrhage, 15 were in the cerebellum. This is the approximate expected incidence based on the weight of the cerebellum as compared to that of the cerebrum. Hypertensive cardiovascular disease was the most common associated finding.

Hamby (7), in 1945, reported 16 cases of surgically-treated intracerebral hematomas. Two were located in the cerebellum. Examples of intracerebellar hematomas due to trauma were recently reported by Schneider, Lemmen and Bagchi (8).

In summary then, although hematomas in the posterior fossa are uncommon, they do occur and should be searched for when signs of cerebellar dysfunction come on following trauma or appear suddenly in a patient with hypertension. In traumatic cases a fracture, scalp hematoma, or contusion in the occipital region, is often found. It is likely that the reported incidence of posterior fossa hematomas will increase as the awareness of their occurrence increases.

REFERENCES

1. Kessel, F. K.: Cerebellar Extradural Haematoma. J. Neurol. & Psychiat., 5: 96, 1942.
2. McKenzie, K. G.: Extradural Hemorrhage. Brit. J. Surg., 26: 346, 1938.
3. Coleman, C. C., and Thomson, J. L.: Extradural Hemorrhage In The Posterior Fossa. Surg., 10: 985, 1941.
4. Anderson, F. M.: Extradural Cerebellar Hemorrhage. J. Neurosurg., 6: 191, 1949.
5. Coblentz, R. G.: Cerebellar Subdural Hematoma In Infant 2 Weeks Old With Secondary Hydrocephalus. Surg., 8: 771, 1940.
6. Mitchell, N., and Angrist, A.: Spontaneous Cerebellar Hemorrhage. Am. J. Path., 18: 935, 1942.
7. Hamby, W. B.: Gross Intracerebral Hematomas. N. Y. State J. M., 45: 866, 1945.
8. Schneider, R. C., Lemmen, L. J., and Baggchi, B. K.: The Syndrome of Traumatic Intracerebellar Hematoma. J. Neurosurg., 10: 122, 1953.

THE RELATION OF MALIGNANT HYPERTENSION TO PERIARTERITIS NODOSA IN HUMANS

NORMAN BANK, M.D.

New York, N. Y.

In recent years there has been increasing interest in a group of vascular diseases which has as its common denominator the histologic appearance of vessel wall necrosis with surrounding inflammatory reaction. Both clinical and experimental studies have indicated that widely divergent mechanisms may give rise to closely similar appearing lesions (1–10). Thus, one may produce vascular necrosis in rabbits by administration of foreign protein or sulpha drugs. Analogous diseases occur in man. Here the basic mechanism is presumably an allergic one. It is also well known that periarteritis nodosa-like lesions can be produced in rats by a number of techniques which seem to have in common the establishment of a hypertensive state (11–16). The relationship between hypertension and human periarteritis nodosa is less clearly understood. It was with the hope of better defining this relation, that the cases of periarteritis nodosa at the Mount Sinai Hospital were reviewed.

CASE MATERIAL

Only cases in which the final autopsy diagnosis was periarteritis nodosa were included. The total number of cases available was 42, covering the period 1930 to 1955. The clinical histories were carefully studied, with special emphasis on hypertension, renal disease, allergy, drug intake and blood transfusions. The physical findings and laboratory data were also reviewed. In addition, autopsy protocols and histologic sections were studied in each case.

RESULTS

Clinically, the group was a heterogeneous one. There were seven cases in which onset of symptoms followed administration of a sulpha drug, and one in which angiitis appeared to be secondary to serum sickness. These eight cases would appear to be allergic in nature and fit the group which Zeek has called hypersensitivity angiitis (17).

Nine of the 42 cases were included in a series reported by Churg and Strauss (18). These were characterized pathologically by extravascular granulomas as well as angiitis. The clinical picture is marked by severe asthma, fever, bizarre skin eruptions, recurrent pneumonia, pericarditis, arthralgia and exceedingly high eosinophilia. There were three cases of Wegener's Granulomatosis. The necrotizing vascular lesion that occurs in this syndrome is well known (19). Four cases were not placed in any group because there was insufficient information available concerning the clinical picture.

In the remaining 18 cases, there was no history of drug intake, serum or blood

From the Department of Pathology, The Mount Sinai Hospital, New York, N. Y.

transfusions, or any overt form of allergy. However, these cases seemed to fall into two distinct groups, depending upon the presence and degree of hypertension. Ten of the 18 presented the clinical syndrome of malignant hypertension, while in the other eight, hypertension was either entirely absent or of mild degree.

HYPERTENSIVE GROUP

The anamnestic data for this group are summarized in Table I. As can be seen, these patients were relatively young. Essential hypertension was known to be present from one to six years in five of the cases. In one case, there was a history of pyelonephritis and nephrectomy preceding the onset of hypertension. In all ten, there was rapid progression of symptoms in the few weeks prior to hospitalization. Severe headaches, nausea, vomiting, diminished visual acuity and mental dullness were common complaints. In four patients, symptoms of left ventricular failure were prominent.

The average systolic blood pressure, on admission, was 220 mm. of mercury; the average diastolic pressure was 140 mm. of mercury. Funduscopic examination revealed severe arteriolar narrowing in all cases, while flame-shaped hemorrhages and cotton-wool exudates were present in six. Papilledema of varying degree was present in five cases. Seven patients had clinical evidence of cardiac enlargement.

The laboratory findings are summarized in Table II. Three to four-plus albuminuria was present in all cases and fixation of urine specific gravity was common. Microscopic hematuria was found in every case. The blood urea nitrogen was elevated in eight cases, ranging from 96 mgm. per cent to 185 mgm. per cent. In the two cases in which blood urea nitrogen was normal, intra-abdominal vascular accidents terminated the course suddenly. Creatinine values paralleled the blood urea nitrogen. There was no consistent pattern in the white blood cell counts, and eosinophilia was not observed in any case.

In addition to the above clinical picture, symptoms were present in seven patients, which can be interpreted as evidence of diffuse vascular disease. Thus, two patients complained of severe pains in the muscles of the arms and legs. In five others, persistent abdominal pains were present. Repeated hematemeses occurred in one patient. Post mortem examination of these cases revealed widespread necrotizing arteritis of the gastrointestinal tract and gall bladder. In two cases, a subcapsular hematoma of the liver, secondary to rupture of a necrotic aneurysm, was the cause of abdominal pain. It is noteworthy that in each instance, hypertension preceded the onset of symptoms of vascular disease. The latter occurred only in the last weeks or months of life.

Case Histories

The following are representative case histories:

Case 9: J. O. The patient was a 32 year old white male physician with a five year history of hypertension, blood pressure averaging 180/90 mm. of mercury. There was no history of preceding renal disease and he was asymptomatic during this period. Six months prior to

TABLE I

Clinical Features: Hypertensive Group

Case	Age	Sex	Race	History of Allergy or Exposure to Foreign Protein	Duration of Hypertension	History of Preceding Renal Disease	Joint and Muscle Pains	Abdominal Pains	Symptoms of Congestive Heart Failure	Blood Pressure on Admission	Eye-Ground Changes	Cardiac Enlargement	Neurologic Symptoms	Abdominal Signs
1	50	M	W	None	3 years	None	Calves, 3 mos.	3 mos.	None	215/125	Grade IV retinopathy	+	Stupor, coma	None (stupor)
2	28	F	W	None	2 years	None	None	None	6 mos.	270/140	Grade IV retinopathy	+	Coma	None
3	47	M	N	None	Unknown	None	None	None	2 wks.	220/140	Grade III retinopathy	+	None	None
4	30	F	N	None	Unknown	None	None	4 wks.	4 wks.	205/145	Grade IV retinopathy	+	Stupor	Diffuse tenderness
5	40	M	W	None	4 years	None	None	None	5 days	210/130	Grade IV retinopathy	+	None	None
6	41	M	W	None	6 years	None	None	3 wks.	None	200/152	Grade II retinopathy	0	None	Tenderness in RUQ
7	58	M	W	None	1 year	Pyelonephritis, 3 yrs.; nephrectomy, 1 yr.	None	4 wks.	None	200/120	Not recorded	+	Semi-coma, convulsions	Liver enlarged and tender
8	54	F	W	None	4 years	None	Arms and legs, 2 wks.	2 wks.	None	230/150	Grade IV retinopathy	+	None	Diffuse tenderness
9	32	M	W	None	5 years	None	None	3 mos.	None	230/130	Grade IV retinopathy	+	Lethargy	Tenderness in RUQ
10	21	M	W	None	Unknown	None	Arthralgias, 6 wks.	24 hrs.	None	190/130	Grade IV retinop-	+	None	Tenderness in CVA

TABLE II

Laboratory Data: Hypertensive Group

Case	Hemoglobin gms%	White Blood cell Count	Eosinophils	Maximum Urine Specific Gravity	Albuminuria	Microscopic Hematoria	Blood Urea Nitrogen mgs. %	Serum Creatinine mgs. %	Chest X-Ray	Electrocardiogram	Serum Albumin gms %	Serum Globulins gms %
1	10.0	12,000	1%	1.022	4+	+	102–183	—	Cardiac enlargement.	Left axis deviation	Not recorded	Not recorded
2	12.0	18,800	2%	1.016	3+	+	21–96	10.0	Left ventricular enlargement	Left axis deviation, left ventricular strain	4.5	1.9
3	9.5	6,400	4%	1.010	3+	+	70–170	6.5	Pulmonary congestion, cardiac enlargement	Left axis deviation, left ventricular strain	3.6	2.0
4	7.0	9,500	1%	1.012	4+	+	115	—	Pulmonary congestion	Left axis deviation, left ventricular strain	3.9	2.2
5	7.5	15,000	None	1.010	3+	+	126	19.0	Cardiac enlargement	Left axis deviation	4.3	2.0
6	12.5	16,800	2%	1.028	3+	+	21	—	Negative	Normal	Not recorded	Not recorded
7	14.0	30,000	None	1.010	2+	+	105	9.6	Negative	Not recorded	2.8	3.7
8	12.2	20,000	None	1.018	3+	+	22	—	Cardiac enlargement	Left axis deviation, left ventricular strain	2.1	5.0
9	7.7	11,000	1%	1.012	3+	+	132–186	—	Negative	Left axis deviation, left ventricular strain	3.5	2.7
10	7.5	38,500	None	1.014	3+	+	22	—	Cardiac enlargement	Myocardial involvement	Not recorded	Not recorded

admission, he noted onset of anorexia, weight loss, and easy fatigability. Four months prior to admission he experienced a sudden massive hematemesis, followed by passage of tarry stools for three days. In the three months previous to hospitalization, he noted severe mid-epigastric pains, aggravated by meals. He vomited frequently.

On admission, he appeared to be chronically ill. His blood pressure was 230/130 mm. of mercury. Temperature, pulse and respiratory rates were normal. Examination of the fundi revealed tortuous arterioles and severe A-V nicking. There were many large confluent and well demarcated cotton-wool exudates, as well as multiple flame-shaped hemorrhages. Bilateral blurring of the optic discs, with loss of cupping was noted. There was no evidence of congestive heart failure. The lungs were clear to percussion and auscultation. The heart was enlarged to the left and A2 was accentuated. No significant murmurs were heard. The examination of the abdomen and extremities was essentially negative.

Laboratory data: Hemoglobin 7.7 gms. per cent. WBC 11,000, with a normal differential. Erythrocyte sedimentation rate 135 mm./hour. Urine: specific gravity 1.012, albumin three plus, sugar negative, many RBC, no WBC or casts. Blood urea nitrogen 132 mgm. per cent. Creatinine 13.5 mgm. per cent, CO_2 20 meq./liter, sodium 130 meq./liter, chloride 88 meq/liter, potassium 5.5 meq/liter, calcium 10.3 mgm. per cent, phosphorus 6.6 mgm. per cent. Serum albumin 3.5 grams per cent, globulins 2.7 grams per cent. Chest x-ray showed transverse enlargement of the heart. The lung fields were clear. An electrocardiogram showed changes indicative of enlargement of the left ventricle with ventricular "strain".

Soon after admission, the patient became severely lethargic. His urinary output fell to 300 cc. per day and by the fifth hospital day, he was completely anuric. His blood urea nitrogen rose to 186 mgm. per cent. He vomited guaiac positive material on several occasions. On the eighth hospital day, a gallop rhythm developed and the patient expired.

Post mortem examination revealed malignant nephrosclerosis and left ventricular hypertrophy. The heart weighed 510 grams. Microscopically, there were widespread arterial and arteriolar changes, consisting of marked intimal thickening and proliferation, fibrinoid necrosis of the media, and perivascular inflammatory cell reaction. These lesions were found in the pancreas, spleen, periadrenal fat, kidneys, gall bladder, and gastrointestinal tract. The mucosa of the small and large intestine showed multiple hemorrhages secondary to necrosis of submucosal arteries.

Case 6: C. P. was a 41 year old house painter with a six year history of asymptomatic hypertension. Six weeks prior to admission he noted severe headaches and became lethargic. Three weeks before admission, there was sudden onset of right upper quadrant pain which radiated to the right shoulder.

Physical examination revealed an acutely ill white male. His blood pressure was 200/150 mm. mercury. Pulse rate 125 per minute, respiratory rate 30 per minute, temperature 101 degrees Fahrenheit. Funduscopic examination revealed marked narrowing of the arterioles and bilateral hemorrhages and exudates. Minimal papilledema was present. The heart was not enlarged but A2 was accentuated. The lungs were clear to percussion and auscultation. There was marked direct and rebound tenderness in the right upper quadrant.

Laboratory data: Hemoglobin 12.5 gms. per cent. WBC 16,800 with a shift to the left. Erythrocyte sedimentation rate 100 mm/hour. Urine: specific gravity 1,028, albumin three plus, sugar negative, 10 to 15 RBC per high power field. The blood urea nitrogen was 21 mgm per cent. Chest x-ray showed minimal cardiac enlargement. The lung fields were clear.

On the fifth hospital day, there was a sudden exacerbation of right upper quadrant pain. Shortly thereafter, shock developed and the patient died.

Post mortem examination revealed a hemoperitoneum of 2000 cc. This was due to rupture of a necrotic aneurysm in the capsule of the liver. The kidneys weighed 120 gms. each and showed moderate parenchymal atrophy. There was diffuse vascular disease typical of that described as periarteritis nodosa. This involved the heart, liver, kidneys, stomach, gall bladder and seminal vesicles. In addition, there were arteriolar lesions commonly associated with malignant hypertension. These were found in the kidney, heart, pancreas bladder, and prostate. The heart weighed 420 gms. and showed left ventricular hypertrophy.

Case 8: G. F. was a 54 year old white female with a four year history of asymptomatic hypertension. In the eight months prior to hospitalization, hypertension increased in severity. There was no history of renal disease. Two weeks before admission, she noted the onset of pains in the muscles of the arms and legs, diffuse crampy abdominal pains and weakness. Two days prior to admission, persistent diarrhea developed.

Physical examination revealed an acutely ill white female. Her blood pressure was 230/150 mm. of mercury. Pulse rate was 100 per minute, respiratory rate 25 per minute, temperature 101.8 degrees Fahrenheit. Funduscopic examination revealed marked narrowing and tortuosity of arterioles, many flame-shaped hemorrhages and cotton-wool exudates. One plus papilledema was present. The heart was enlarged to the left, and the cardiac sounds were of poor quality. There was evidence of both left and right ventricular failure. Examination of the abdomen revealed diffuse tenderness, most marked in the epigastrium.

Laboratory data: Hemoglobin 12.2 gms per cent, WBC 17,200 with a shift to the left. Erythrocyte sedimentation rate 58 mm/hour. Urine: specific gravity 1.020, albumin three plus, sugar negative, 8 to 10 RBC per high power field. The blood urea nitrogen was 22 mgm. per cent. Chest x-ray revealed marked cardiac enlargement and increased broncho-vascular markings. An electrocardiogram showed left axis deviation and left ventricular "strain" pattern.

In the hospital, cyanosis of several digits of both hands developed. This rapidly progressed to full blown gangrene. The severe abdominal pains continued as did the diarrhea. On the eleventh hospital day, her blood pressure fell precipitously and she expired.

Post mortem examination revealed necrotizing arteritis with inflammatory reaction of the entire gastrointestinal tract with resultant necrotizing colitis and ileitis. Similar vascular lesions were noted in the gall bladder, heart, pancreas and urinary bladder. In addition, the arteriolar thickening and medial necrosis of malignant nephrosclerosis were found in the kidneys. The heart weighed 480 gms and showed left ventricular hypertrophy. The kidneys weighed 140 grams each. Renal parenchymal atrophy was minimal.

The remaining seven case histories are quite similar to the preceding and will not be described in detail. The cardinal clinical features are presented in Tables I and II.

The autopsy findings in this group of ten patients were reviewed and the tissue sections studied. In every case except one there were arteriolar changes commonly associated with malignant hypertension. These consisted of marked intimal thickening with cellular proliferation, medial necrosis, and red blood cells in the vessel wall. A typical lesion is shown in figure 1. These lesions were present most often in the kidney, but were found in other organs as well. They were present in the lung in only one case, and here they were sparse. In addition,

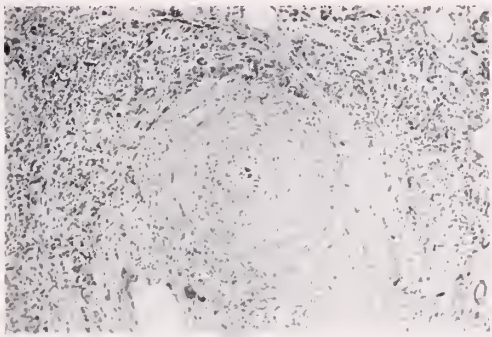

FIG. 1. Artery from case 2 showing marked intimal thickening and hyperplasia of the type seen in malignant hypertension.

there was, in every case, diffuse necrotizing arteritis of the type commonly termed periarteritis nodosa. These lesions consisted in severe necrosis involving the entire thickness of the vessel wall, and marked perivascular cellular reaction. An artery showing this change is pictured in figure 2. Small arteries and arterioles were involved exclusively and almost all lesions were in an acute stage. Grossly, arterial nodules were not recognized in any case. The distribution of arterial lesions is summarized in Table III. The lungs were not involved in any case by this type of lesion. Cardiac enlargement and left ventricular hypertrophy were present in every case.

IDIOPATHIC GROUP

In contrast to the cases described above, the remaining eight patients revealed neither clinical nor pathological evidence of malignant hypertension. Onset of symptoms in this "idiopathic" group occurred from three weeks to nine months previous to hospitalization. The anamnestic data and physical findings are presented in Table IV. As can be seen, the most common symptom

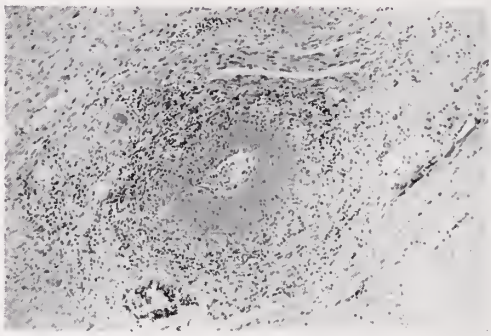

FIG. 2. Artery also from case 2, showing severe vessel wall necrosis and surrounding inflammatory cell reaction.

TABLE III

Distribution of Arterial Necrosis in Group with Malignant Hypertension: 10 Cases

Organ	No. of Cases
GI tract	8
Gallbladder	8
Kidney	7
Pancreas	6
Adrenal	4
Liver	4
Testis	4
Heart	2
Urinary bladder	2
Prostate	1
Spleen	1
Lungs	0

was pain in the muscles of the legs and arms, sometimes with evidence of peripheral neuritis and marked atrophy. Pain in the large joints was also a common complaint. Weight loss of ten to twenty pounds occurred in almost every case and a low grade fever of obscure origin was frequent. In one patient, the presenting symptom was epigastric pain, which proved to be due to gastric ulcerations secondary to necrotizing arteritis in the submucosa. These patients were older than those in the hypertensive group and there was a preponderance of males. All were normotensive on admission to the hospital. Two patients developed hypertension of moderate degree while under observation. The maximum recorded blood pressures in these two cases were 140/95 and 194/105 mm. of mercury respectively. In the remaining six cases, the blood pressure remained within normal limits, throughout the course of illness.

Positive physical findings in this group were most often noted in the extremities, and included muscle wasting, peripheral neuropathy, and evidence of arthritis. Abdominal pain and tenderness led to surgical intervention in one case. Here the appendix was removed, and revealed on microscopic examination, multiple foci of necrotizing arteritis. Post mortem examination two months later showed generalized periarteritis nodosa with involvement of many organs. In another case, severe costovertebral pain and tenderness developed, followed by shock and death four days later. Necropsy revealed a massive retroperitoneal hemorrhage originating from a necrotic blood vessel in the cortex of the right kidney. Evidence of malignant hypertension was conspicuously absent in the group as a whole. The average systolic blood pressure was 150 mm. of mercury; the average diastolic pressure was 90 mm. of mercury. Eye-ground examination was usually negative, or revealed moderate narrowing of the arterioles. Papilledema was not observed in any case.

The laboratory data for this group are presented in Table V. The ability to concentrate urine was present in almost every case. Albuminuria of one to two plus was a common finding, as was microscopic hematuria. The blood urea nitrogen was normal in four cases, was elevated to 48 and 56 mgm. per cent in two cases, and showed progressive elevation to 140 and 165 mgm. per cent in two others. The white blood cell counts varied greatly, showing no consistent pattern. Eosinophilia was not present in any case in this group.

Case Histories

The following are representative case histories:

Case #28: A. R. was a fifty-seven year old white male who was well until three months before admission to the hospital, at which time he noted crampy pains in the calf muscles and arms. This was followed by increasing weakness and atrophy of the involved muscles. A low grade fever, anorexia, and a ten pound weight loss were also noted.

On admission, his blood pressure was 130/70 mm. of mercury. His temperature was 101 degrees Fahrenheit. Pulse and respiratory rates were normal. Funduscopic examination was negative. Examination of the heart, lungs and abdomen was also negative. There was marked atrophy of the muscles of the arms and legs and fibrillations were noted. There was evidence of impairment of both motor and sensory functions over the involved areas.

Laboratory findings were as follows: Hemoglobin 11.0 grams per cent. White blood cell

TABLE IV

Clinical Features: "Idiopathic" Group

Case	Age	Sex	Race	History of Allergy or Exposure of Foreign Protein	History of Hypertension	Muscle Pains	Joint Pains	History of Fever	Weight Loss	Abdominal Pains	Blood Pressure on Admission	Muscle Wasting	Neurological Involvement
21	72	M	W	None	None	None	None	None	15 lbs.	Epigastric, 1 wk.	145/80	None	None
22	33	M	W	None	None	None	Knees and elbows (migratory)	1 mo.	None	2 wks.	140/75	None	None
23	51	M	W	None	None	Legs	Knees and ankles	6 mo.	20 lbs.	None	132/90	Arms and legs	Legs and postero-lateral columns
24	31	F	W	None	None	Legs	None	Intermittent, 3 yrs.	None	1 yr.	140/85 labile	Calves	Legs, facial paralysis
25	61	M	W	None	None	Legs and neck	Knees, ankles, and wrists	3 mo.	None	None	154/85	Thighs	Legs
26	42	M	W	None	None	Calves and arms	None	10 wks.	10 lbs.	None	140/110	Arms and legs	Arms and legs posterior columns
27	60	M	W	None	None	Generalized pains	None	3 wks.	15 lbs.	Costovertebral pain	140/85	None	None
28	57	M	W	None	None	Arms and legs	None	1 mo.	10 lbs.	None	130/70	Calves and biceps	Arms and legs

TABLE V

Laboratory Data: "Idiopathic" Group

Case	Hemoglobin gms. %	White Blood Cell Count	Eosinophils	Maximum Urine Specific Gravity	Albuminuria	Microscopic Hematuria	Blood Urea Nitrogen mgs. %	Chest X-ray	Electrocardiogram	Serum Albumin gms. %	Serum Globulins gms. %
21	14.0	10,700	None	1.010	1+	None	81 to 166	Negative	Left axis deviation	Not recorded	Not recorded
22	13.0	19,600	None	1.016	2+	+	56	Negative	Not recorded	3.4	3.0
23	11.0	19,200	None	1.030	None	None	14	Cardiac enlargement	Left axis deviation	3.4	2.5
24	13.5	Not recorded		1.020	2+	+	16	Cardiac enlargement	Changing T waves	Not recorded	Not recorded
25	12.0	8,000	4%	1.016	2+	+	48	Cardiac enlargement, pulmonary congestion	Myocardial damage	3.6	2.0
26	10.5	16,000	None	1.022	1+	+	13	Negative	Normal	Not recorded	Not recorded
27	12.0	18,000	1%	1.020	1+	+	22	Negative	Posterior wall infarction	3.1	2.7
28	11.0	24,500	3%	1.016	1+	None	20 to 142	Negative	Normal	2.6	3.6

count 25,000 with a shift to the left. Erythrocyte sedimentation rate 60 mm/hour. Urine: specific gravity 1.016, albumin two plus, occasional RBC. Blood urea nitrogen 20 mgm per cent. Serum albumin 2.6 grams per cent, globulin 3.6 grams per cent. Chest x-ray was negative. An electrocardiogram was normal.

In the hospital, the patient remained febrile, his temperature varying between 101 and 102 degrees Fahrenheit. He continued to complain of muscle pains and there was further atrophy and weight loss. The blood urea nitrogen rose steadily, reaching 142 mgm. per cent before death. Albuminuria and hematuria persisted. His blood pressure rose to 140/95 mm. of mercury. Preterminally, auricular fibrillation and pulmonary edema developed. He died during the fifth week of hospitalization.

Post mortem examination revealed diffuse necrotizing arteritis involving all of the major thoracic and abdominal organs. Dissection of the extremities was not carried out. There was no evidence of malignant nephrosclerosis nor vascular changes of malignant hypertension in any organ.

Case #25: J. F. was a 61 year old white male who was well until five months prior to hospitalization when he noted stiffness and swelling of the knees and weakness of leg muscles. During this period, he noted a fifteen pound weight loss. Several weeks before admission, his temperature became elevated to 102 degrees Fahrenheit.

On admission, he appeared to be chronically ill. His blood pressure was 155/85 mm. of mercury. Temperature was 101.6 degrees Fahrenheit. Examination of the fundi, heart, lungs, and abdomen was essentially negative. Swelling and increased warmth of the knees and elbows were noted. There were fasciculations of the thigh muscles, bilateral foot drop, and atrophy of the calf muscles.

Laboratory findings were as follows: Hemoglobin 12.0 grams per cent. White blood cell count 8,000 with a normal differential. Erythrocyte sedimentation rate 12 mm/hour. Urine: specific gravity 1.016, albumin two plus, 3–4 RBC/ high power field. Blood urea nitrogen 48 mgm. per cent. Serum albumin 3.6 grams per cent, globulins 2.0 grams per cent. Chest x-ray showed an increased transverse diameter of the heart. A skin and muscle biopsy of the calf showed an acute necrotizing arteritis with inflammatory response.

In the hospital, his temperature remained elevated to levels of 102 to 104 degrees Fahrenheit. Weight loss and muscle atrophy progressed. The blood urea nitrogen rose to 50 mgm. per cent and his blood pressure became elevated to 194/105 mm. of mercury. With this, the fundal arterioles showed narrowing, and hemorrhages and exudates developed

TABLE VI

Distribution of Vascular Necrosis in "Idiopathic" Group: 8 Cases

Organ	No. of Cases
Heart	8
Liver	8
Kidney	8
GI tract	8
Pancreas	7
Lung	6
Adrenal	6
Gallbladder	6
Testis	5
Spleen	3
Prostate	3
Diaphragm	3
Skin	2
Urinary bladder	1

bilaterally. Congestive heart failure terminated the course after four months of hospitalization.

Autopsy revealed periarteritis nodosa involving the heart, lung, liver, kidney, adrenal, gastrointestinal tract, testes, and spleen.

Analysis of the autopsy findings in this group reveals certain interesting differences from the group with malignant hypertension. In almost every one of the "idiopathic" cases, nodular aneurysms were grossly visible along the course of medium sized arteries. In the hypertensive group, arterial involvement could be demonstrated only by microscopic examination. A second striking difference was the frequency with which the lungs were involved in the "idiopathic" group as compared to the cases with malignant hypertension. The significance of this will be discussed below. Histologic examination of the "idiopathic" cases revealed arterial lesions in various stages of development and healing. In the patients with malignant hypertension, most of the lesions were in the acute stage and there was little evidence of fibrosis. Finally, there was no evidence of malignant nephrosclerosis nor arteriolar changes of malignant hypertension in any of the "idiopathic" cases.

DISCUSSION

It is now known that the term periarteritis nodosa, as it had been used in the past, encompassed several disease entities. Zeek has applied the generic term *necrotizing angiitis* to the group as a whole and suggests the following classification (17):

1. Hypersensitivity angiitis
2. Allergic granulomatous angiitis
3. Rheumatic arteritis
4. Periarteritis nodosa
5. Temporal arteritis

Hypersensitivity angiitis applies to cases in which there has been allergic response either to a drug or to serum. The major target tissue in the reaction lies in the vascular system; arteries, capillaries and veins may all be involved (20). The pulmonary as well as systemic blood vessels are the site of a necrotizing angiitis (21). There is usually supportive clinical evidence for an allergic state, such as skin rash and eosinophilia. Analogous lesions have been produced in experimental animals by the administration of sulpha drugs or foreign protein (11).

The group of cases described by Churg and Strauss and named by them *allergic granulomatosis and angiitis* appear to be closely related to hypersensitivity angiitis. Both clinically and morphologically, there is abundant evidence for the presence of a severe hypersensitive state (22). Not only is the entire vascular system subject to involvement, but extravascular connective tissue is also severely damaged (18). The offending allergen or allergens are unidentified.

In the remaining cases, there is no overt evidence of an allergic mechanism and it is for these that Zeek reserves the name periarteritis nodosa. Much has been written concerning the role of hypertension in the production of arteritis in this group, but there is as yet no uniform agreement. In the present series,

the nonallergic cases fell into two distinct groups. In one, malignant hypertension dominated the clinical picture and antedated symptoms of peripheral arterial disease. In the other, hypertension was never prominent, and occurred only after evidences of vascular disease had been present for some time.

The role of hypertension in the production of experimental arterial necrosis has been somewhat better defined but here too there is no universal agreement. Lesions which closely resemble human periarteritis nodosa have been produced in rats by numerous methods which include clamping one renal artery with or without excision of the contralateral kidney (23, 24), wrapping the kidneys in silk or cellophane (12), unilateral nephrectomy supplemented by desoxycorticosterone or anterior pituitary extract (8), administering sodium chloride and desoxycorticosterone without any surgical procedure (13). The weight of evidence now appears to favor the view that the basic underlying mechanism in the production of the arterial lesions in the rat is the presence of a state of severe hypertension (24–27). The presence or absence of azotemia does not seem to affect the results (12, 14, 24). The vascular changes produced by these techniques in the rat have a striking similarity to those observed in the patients with malignant hypertension in this series. There can be found arteriolar thickening with cellular proliferation in the intima and fibrinoid necrosis of the media, changes which are associated with human malignant hypertension (8, 13, 24). In addition, one finds widespread vascular lesions consisting in necrosis of all three coats with striking perivascular cellular reaction (8, 12, 13, 16, 24). These occur mainly in the splanchnic organs and are conspicuously infrequent in the lungs (21). It is most likely that these vascular lesions represent a spectrum of response to the common stimulus, hypertension. Many workers in the field believe that the differences in severity of vascular damage observed in reported series reflect the rapidity of onset and the levels of hypertension produced by the particular experimental method (14, 24, 27). Thus, it would seem that in the rat, the common response to severe hypertension is severe arterial necrosis with inflammatory reaction.

In dogs, hypertension produced by bilateral nephrectomy, results in arterial lesions which closely resemble those of human malignant hypertension (28–31). The experiments of Muirhead et al. indicate that the morphogenetic process begins in the media, with necrosis and eosinophilic smudging of the smooth muscle cells. This material then spreads into the adventitia and/or intima (29). The intima is usually thickened with resultant narrowing of the lumen. Perivascular inflammatory cell reaction is rare, and the usual features of periarteritis nodosa are not found in dogs made hypertensive by this method (29). This probably means that the degree of hypertension produced in dogs is not relatively as great as that produced in rats. Presumably, if higher pressure were attained, one would find the same vascular damage observed in rats.

The precise mechanism by which severe hypertension may result in arterial necrosis has been recently investigated by Byron (32). This author produced hypertension in rats by excising one kidney and applying a Goldblatt clamp to the contralateral renal artery two weeks later. Symptoms interpreted as hyper-

tensive encephalopathy developed at pressures of 200 mm. of mercury and above, and it was considered that a state of "malignant" hypertension had been produced. Direct observation of the cerebral blood vessels was then carried out, by means of cranial windows. During periods of severe hypertension, segmental, focal narrowing of the smaller arteries was seen. These spasms disappeared when the blood pressure was lowered by removal of the Goldblatt clamp. Byron believes that the localized narrowing is due to an intrinsic reflex contraction of the smooth muscle of the media to the increased intravascular tension. If the period of contraction be sustained long enough, the muscle undergoes necrosis. The altered sarcoplasm would then act as an irritant, and stimulate an inflammatory cell response.

The concept that the primary injury in malignant hypertension is to the media of small arteries and arterioles is supported by the studies of Montgomery, Muirhead, Turner, and Grollman (33–35). These authors, by means of a battery of histochemical tests, examined the necrotic arterial lesions occurring in dogs made hypertensive by bilateral nephrectomy. The staining properties of the fibrinoid material were compared to fibrinoid occurring in human malignant hypertension and to normal smooth muscle. The fibrinoid material from hypertensive dogs and human arteries had identical staining reactions, and was shown to consist of substances that are present in normal smooth muscle. This would indicate that fibrinoid in malignant hypertension is derived from the media.

Indirect evidence in favor of the view that medial spasm leads to necrosis, is the distribution of vascular lesions in malignant hypertension. It is the smaller arteries, in which the muscular coat is relatively large, that are primarily affected. This is in contrast to the involvement in "idiopathic" periarteritis nodosa, which affects primarily medium sized vessels (21). Furthermore the paucity of lesions in the lungs in the hypertensive group of patients, as in the rat and dog (30), supports the theory since only the bronchial arteries are exposed to the pressures of the general circulation. Cases reported in the literature as periarteritis nodosa limited to the lungs, have occurred only in patients with pulmonary hypertension (36).

It may be postulated, therefore, that malignant hypertension was the primary etiologic factor in the production of necrotizing arteritis in these patients. Knowles et al. have referred to cases of this type as "secondary periarteritis nodosa" (37). Perhaps it would be better to refer to them simply as necrotizing arteritis secondary to malignant hypertension. The important thing to recognize is that excessive elevations of blood pressure may result in a spectrum of arterial lesions, at one end of which the histologic appearance of idiopathic periarteritis nodosa is closely simulated.

There were eight cases in this series for which neither an allergic nor a hypertensive etiology could be proposed. Moderate elevations of blood pressure occurring in these patients were most likely secondary to renal involvement by the underlying arterial disease, rather than the cause of the arterial necrosis. These eight patients typify the only group for which, the author feels, the term periarteritis nodosa should be retained.

SUMMARY

1. Forty-two cases in which the autopsy diagnosis was periarteritis nodosa, were reviewed.

2. There were seventeen cases in which an allergic mechanism was probably involved in the production of arterial necrosis. Included in this group are nine cases of allergic granulomatosis and arteritis.

3. There were ten cases in which malignant hypertension appeared to play the most important role in the production of periarteritis nodosa-like lesions. Experimental support of this hypothesis is discussed. It is felt that these cases should not be referred to as secondary periarteritis nodosa, but rather as necrotizing arteritis secondary to malignant hypertension.

4. The term periarteritis nodosa should be used only for those cases of widespread necrotizing arteritis in which neither allergy nor malignent hypertension are present clinically.

REFERENCES

1. Black-Schaffer, B.: Pathology of Anaphylaxis due to Sulfonamide drugs. Arch. Path., 39: 301, 1945.
2. Chute, A. L., Orr, J. L., O'Brien, M. J., and Jones, E. E.: Vascular Lesions in Alloxan Diabetic Rats. Arch. Path., 52: 105, 1951.
3. Clark, E., and Kaplan, B.: Endocardial, Arterial and other Mesenchymal Alterations Associated with Serum Disease in Man. Arch. Path., 24: 458, 1937.
4. Ehrenreich, T., and Olmstead, E. V.: Malignant Hypertension Following the Administration of Cortisone in Periarteritis Nodosa. Arch. Path., 52: 145, 1951.
5. French, A. J.: Hypersensitivity in the Pathogenesis of the Histopathologic Changes Associated with Sulfonamide Chemotherapy. Am. J. Path., 22: 679, 1946.
6. Kipkie, G. F., and Johnson, D. S.: Possible Pathogenic Mechanisms Responsible for Human Periarteritis Nodosa. Arch. Path., 51: 387, 1951.
7. Lichtenstein, L., and Fox, L. J.: Necrotizing Arterial Lesions Resembling those of Periarteritis Nodosa and Focal Visceral Necrosis Following Administration of Sulfathiazole. Am. J. Path., 22: 665, 1946.
8. Masson, G. M. C., Hazard, J. B., Corcoran, A. C., and Page, I. H.: Experimental Vascular Disease due to Desoxycorticosterone and Anterior Pituitary Factors. Arch. Path., 49: 641, 1950.
9. Rich, A. R.: The Role of Hypersensitivity in Periarteritis Nodosa. Seven cases Developing Serum Sickness. Johns Hopkins Hosp. Bull., 71: 123, 1942.
10. Wilens, S. L., and Glynn, J.: Hypertensive and Non-Hypertensive Periarteritis Nodosa. Arch. Int. Med., 88: 51, 1951.
11. Rich, A. R., and Gregory, J. E.: The Experimental Demonstration that Periarteritis Nodosa is a Manifestation of Hypersensitivity. Johns Hopkins Hosp. Bull., 72: 65, 1943.
12. Friedman, B., Jarman, J., and Klemperer, P.: Sustained Hypertension Following Experimental Unilateral Renal Injuries. Effects of Nephrectomy. Am. J. Med. Sc., 202: 20, 1941.
13. Hall, C. E., and Hall, O.: Hypertensive Disease Produced by Desoxycorticosterone Acetate in Parabiotic Rats. Arch. Path., 51: 249, 1951.
14. Kempner, W., Peschel, E., and Black-Schaffer, B.: Effect of Diet on Experimental Hypertension and on the Development of Polyarteritis Nodosa in Rats. Circ. Res., 3: 73, 1955.
15. Loomis, D.: Hypertension and Necrotizing Arteritis in the Rats Following Renal Infarction. Arch. Path., 41: 231, 1946.

16. Race, G. J., and Peschel, E.: Pathogenesis of Polyarteritis Nodosa in Hypertensive Rats. Circ. Res., 6: 483, 1954.
17. Zeek, P. M.: Periarteritis Nodosa. A Critical Review. Am. J. Clin. Path., 22: 777, 1952.
18. Churg, J., and Strauss, L.: Allergic Granulomatosis, Allergic Angiitis and Periarteritis Nodosa. Am. J. Path., 27: 227, 1951.
19. Fahey, J. L., Leonard, E., Churg, J., and Godman, G.: Wegener's Granulomatosis. Am. J. Med., 17: 168, 1954.
20. Zeek, P. M., Smith, C. C., and Weeter, J. C.: Studies on Periarteritis Nodosa III. The Differentiation Between the Vascular Lesions of Periarteritis Nodosa and of Hypersensitivity. Am. J. Path., 24: 889, 1948.
21. Zeek, P. M.: Periarteritis Nodosa and Other Forms of Necrotizing Angiitis. New Eng. J. Med., 248: 764, 1953.
22. Harkavy, J.: Vascular Allergy III. J. Allergy, 14: 507, 1942.
23. Byrom, F. B., and Dodson, L. F.: The Mechanism of the Vicious Circle in Chronic Hypertension. Clin. Sc., 8: 1, 1949.
24. Wilson, C., and Byrom, F. B.: Renal Changes in Malignant Hypertension. Lancet, 236: 136, 1939.
25. Smith, C. C., and Zeek, P. M.: Studies on Periarteritis Nodosa II. The Role of Various Factors in the Etiology of Periarteritis Nodosa in Experimental Animals. Am. J. Path., 23: 147, 1947.
26. Smith, C. C. Zeek, P. M., and McGuire, J.: Periarteritis Nodosa in Experimental Hypertensive Rats and Dogs. Am. J. Path., 20: 721, 1944.
27. Muirhead, E. E., and Grollman, A.: Acute Renal Insufficiency in Man Manifesting the Arterial Necrosis Observed in Dogs, Following Bilateral Nephrectomy. Am. J. Med., 10: 780, 1951.
28. Masson, G. M. C., Plahl, G., Corcoran, A. C., and Page, I. H.: Accelerated Hypertensive Vascular Disease from Saline and Renin in Nephrectomized Dogs. Arch. Path., 55: 85, 1953.
29. Muirhead, E. E., Vanatta, J., and Grollman, A.: Hypertensive Cardiovascular Disease. An Experimental Study of Tissue Changes in Bilaterally Nephrectomized Dogs. Arch. Path., 48: 234, 1949.
30. Muirhead, E. E., Turner, L. B. and Grollman, A.: Hypertensive Cardiovascular Disease. Vascular Lesions of Dogs Maintained for Extended Periods Following Bilateral Nephrectomy or Ureteral Ligation. Arch. Path., 51: 575, 1951.
31. Muirhead, E. E., Stirman, J. A., Jones, F., Lesch, W., Burns, M., and Fogelman, M. J.: Cardiovascular Lesions Following Bilateral Nephrectomy of Dogs. Arch. Int. Med., 91: 250, 1953.
32. Byrom, F. B.: The Pathogenesis of Hypertensive Encephalopathy and Its Relation to the Malignant Phase of Hypertension. Lancet, 267: 201, 1954.
33. Montgomery, P. O'B., and Muirhead, E. E.: Similarities Between the Lesions in Human Malignant Hypertension and in the Hypertensive State of the Nephrectomized Dog. Am. J. Path., 29: 1147, 1953.
34. Montgomery, P. O'B., and Muirhead, E. E.: A Characterization of Hyaline Arteriolar Sclerosis by Histochemical Procedures. Am. J. Path., 30: 521, 1954.
35. Muirhead, E. E., Turner, L. B., and Grollman, A.: Hypertensive Cardiovascular Disease. Nature and Pathogenesis of the Arteriolar Sclerosis Induced by Bilateral Nephrectomy as Revealed by a Study of Its Tinctorial Characteristics. Arch. Path., 52: 266, 1951.
36. Old, J. W., and Russell, W. O.: Necrotizing Pulmonary Arteritis Occurring with Congenital Heart Disease (Eisenmenger Complex). Report of Case with Necropsy. Am. J. Path., 26: 789, 1950.
37. Knowles, H. C., Zeek, P. M., and Blankenhorn, M. A.: Studies on Necrotizing Angiitis. Arch. Int. Med., 92: 789, 1953.

TEMPORAL SLOWING AS A SOURCE OF ERROR IN ELECTROENCEPHALOGRAPHIC LOCALIZATION

HANS STRAUSS, M.D., MORTIMER OSTOW, M.D., MED. SC. D., LOUIS GREENSTEIN, M.D., AND SUZANNE LEWYN, B.A.

New York, N. Y.

This paper deals with errors in the electroencephalographic localization of lesions in the cerebral hemispheres. There are several sources of error. One of the most frequent is the presence of circulatory disturbances secondary to a neoplastic process. This circulatory disturbance may induce a focal electroencephalographic abnormality distant from the neoplasm itself. Other errors may be caused by pressure effects dislocating the brain substance, such as instances of uncal herniation. However, we believe and shall try to demonstrate that aside from such more or less mechanical sources of error, there are others due to intrinsic differences in the reaction of various parts of the cerebrum to disturbing factors.

The most common electroencephalographic abnormality in the presence of organic brain disease is the appearance of abnormally slow (delta)* activity. It is tacitly accepted that the location of a hemisphere lesion corresponds to the site of the greatest amount, highest voltage and slowest frequency of slow activity, unless other electroencephalographic features as e.g. extinction of activity, localized slowing of the alpha activity or appearance of spikes suggest a different localization.

Using the distribution of slow activity as our chief guide in localization, we obtained the results presented in "Diagnostic Electroencephalography" (1). Most of the observations reported there were made with the use of 15 electrodes (setting A). These electrodes included a medial group (a single midline vertex electrode and bilaterally symmetrical frontal, central, parietal and occipital electrodes) and a lateral group (inferior frontal, inferior parietal and ear lobe electrodes) (Fig. 1.). More than three years ago, we started to use an arrangement with 17 electrodes (setting B). While we made no changes in the placement of the medial group of electrodes, the lateral group (to which we also refer as the temporal group) now includes anterior temporal, midtemporal and posterior temporal electrodes in addition to the previously used ear lobe electrode. The instructions for the placement of these electrodes are described elsewhere (1). The differences between settings A and B are displayed in figure 1.

Using setting B, we made more errors in localization than before and soon had the impression that we tended to mislocalize the lesions usually in the direction of the anterior temporal electrode. It seemed to us that the temporal group of

From the Departments of Neurology and Neurosurgery, the Mount Sinai Hospital and the Beth Israel Hospital, New York, N. Y.

* We designate as delta activity, potentials with a frequency of six or less cycles per second (cps.) and a voltage of at least 20 microvolts. We do not use the designation "theta activity," but of course take notice of and report the various frequencies of the slow waves

electrodes was more sensitive than the medial group in the sense that the same degree of dysfunction in subjacent brain areas gives rise to greater electroencephalographic abnormality at the temporal than the medial electrodes. Further, among the temporal electrodes, the anterior temporal seemed the most sensitive, the ear electrode somewhat less so, and the others still less (2).

In order to determine the correctness of our impression, we undertook the following study.

MATERIAL AND METHOD

We assembled 104 cases in which focal lesions were demonstrated either at operation or necropsy, and in which the electroencephalogram yielded data of localizing value. These cases were observed on the Neurological and Neurosurgical Services of the Mount Sinai Hospital and Beth Israel Hospital in New York City, and on the Private Services of Dr. Leo M. Davidoff, who made available to us drawings of the lesions encountered at operation. The material includes 97 tumors, two single abscesses, two subdural hematomas, two intracerebral hematomas and one scar. The records were obtained in all cases with setting B. The leads used are described in Diagnostic Electroencephalography (1). They include leads composed of a scalp electrode with the vertex electrode or the ipsilateral ear electrode and a variety of leads composed of two scalp electrodes. In these 104 patients, we correlated the distribution of electroencephalographic abnormality with the localization of the lesion.

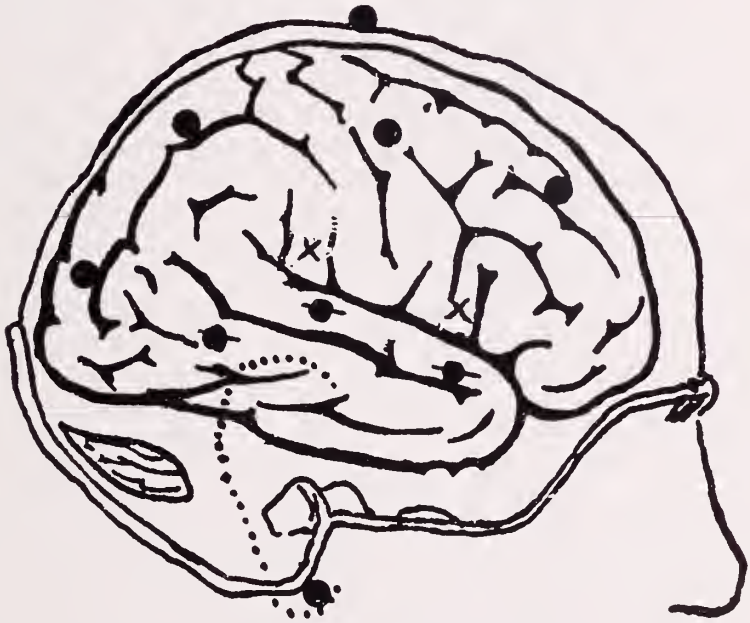

FIG. 1. Electrode settings A and B. Both settings use the frontal, central parietal, occipital, ear lobe and vertex electrodes (solid circles). Setting A in addition, included inferior frontal and inferior parietal electrodes (crosses). Setting B substitutes anterior temporal, mid-temporal, and posterior temporal electrodes (solid circles with cross line).

TABLE 1

Distribution of cases by location of lesion and electroencephalographic abnormality

(Numbers in parentheses indicates number of records with a high degree of abnormality.)

Location of Lesions ↓	Total Number of Cases	Delta Confined to temporal electrodes	Maximal Delta at temporal electrodes plus				Maximal Delta at Electrodes				Diffuse Delta	Bilateral Frontal Delta
			Frontal δ	Central δ	Parietal δ	Occipital δ	Frontal	Central	Parietal	Occipital		
Frontal	45	7 (1)	14 (9)	0	1 (1)	1 (0)	19 (16)	0	1 (0)	0	2 (1)	19 (17)
Central	14	2 (0)	1 (0)	0	1 (1)	0	5 (2)	0	4 (2)	0	1 (1)	2 (1)
Parietal	10	1 (0)	1 (1)	0	0	0	1 (1)	2	3 (2)	1 (0)	1 (1)	1 (1)
Occipital	14	0	0	1 (1)	0	2 (1)	1 (1)	0	1 (1)	8 (6)	1 (0)	0
Temporal	14	5 (4)	1 (1)	0	1 (1)	3 (3)	2 (1)	0	1 (1)	0	1 (1)	2 (1)
Thalamic	4	2 (2)	1 (1)	0	0	0	0	0	0	1 (1)	0	1 (1)
Total	101	17	18	1	3	6	28	2	10	10	6	25

RESULTS

In 101 cases there was localizing delta activity. In the remaining 3 cases, there were localizing differences in alpha activity, but no delta activity.

The cases were grouped according to the location of the lesion. In doing so, we were content to designate the location in terms of the conventional lobe areas (frontal, temporal, parietal and occipital) and a "central" area which included that territory bounded by the precentral sulcus anteriorly, the postcentral sulcus posteriorly, and the Sylvian Fissure inferiorly. With the relatively small number of cases at our disposal, it was not feasible to make a more detailed classification in terms of the location within the particular lobe. Of all the cases, there were only nine with delta activity absent from all the temporal electrodes. Correlations between the location of the lesion and the electroencephalogram are demonstrated in Table 1, which lists the 101 patients in whom delta activity was found. As to the distribution of delta activity, we classified the records as follows: (a) those with delta activity confined to the temporal electrodes, (b) those with delta activity maximal at the temporal electrodes and less at one of the medial electrodes, (c) those with maximal delta activity at one of the medial electrodes and less or no delta activity at the temporal electrodes, (d) those with diffuse delta activity, more on one side but without any focal accentuation anywhere on that side. We also list in this table the number of cases in which there was bilateral frontal delta activity. The numbers in brackets indicate how many of the total number of cases listed in the particular rubric showed a record with a high degree of abnormality. According to our definition (1) a high abnormality record is defined as one in which (a) the lowest frequency is two cps. or less, (b) the delta factor (percentage of time occupied by delta activity) is at least 35 in at least one lead and (c) the average delta factor is 20 or more. Unless all three criteria are fulfilled, the record is classified as a low abnormality record.

CLASSIFICATION BY LOCATION OF THE LESION

In this section we shall consider the lesions in various locations and describe the distribution of electroencephalographic abnormality associated with them.

A. *Frontal Lobe Lesions*

There were 45 patients with lesions of a frontal lobe.

Of these seven (15 per cent) showed delta activity at the temporal electrodes only. The degree of abnormality was low in six of these cases and high in the other.

In 14 (31 per cent) of the 45 patients with lesions of the frontal lobe, slowing appeared at the frontal electrodes, though not as prominently there as at the temporal electrodes. In these 14 cases, the anterior temporal electrode showed the highest degree of abnormality, and the frontal electrode next to the highest. In this subgroup, two cases showed an increase in alpha amplitude at the frontal electrode on the affected side.

The most common finding in patients with frontal lobe lesions was slowing most prominent at the frontal electrode and less prominent at one or more of the temporal electrodes. There were 19 such cases, constituting 42 per cent of the frontal lobe group. In this subgroup, only 15 per cent of the records showed low and 75 per cent high abnormality.

Five cases with different distributed abnormality are listed in the table.

In 42 per cent of the cases with frontal lobe lesions, slow activity appeared at the contralateral as well as the ipsilateral frontal electrode. While the percentage of bilateral frontal slowing is highest in patients with frontal lobe lesions and while most of these cases with bilateral frontal slowing were cases of either frontal parasagittal or subfrontal lesions, bilateral frontal slowing occurred also in cases with lesions located elsewhere. The unilateral increase in alpha amplitude in the frontal region in two cases, where the temporal slowing was more prominent than the frontal slowing, was helpful in avoiding mislocalization. In these cases the change in alpha frequency at the frontal electrode was a more reliable sign than the delta activity at the temporal electrodes.

In summary, in cases with frontal lobe lesions, the most frequent finding was maximal slowing at the frontal electrode with a smaller degree of slowing at the temporal electrodes. While this finding is not misleading, there was another relatively large group of cases with some slowing at the frontal electrodes but even more slowing at the anterior temporal electrode which may easily lead to a wrong localization of the lesion. There was a small group of cases with no slowing at the frontal electrode, although there was slowing at the temporal electrodes. To distinguish this last group of cases from those in which the lesion occupies the temporal lobe, we may take advantage of the fact that in the frontal lobe cases with only temporal slowing, the degree of abnormality is almost always low, while, as we shall see below, in the presence of temporal lobe lesions with only temporal slowing, 80 per cent of the records show a high degree of abnormality.

Finally bilateral frontal slowing favors a frontal lesion, even if slow activity appears maximally in the temporal region.

B. Central Lesions

There were 14 patients with lesions in the central region.

In five of these cases maximal slowing appeared at the frontal electrode in four at the parietal electrode. Two cases showed only temporal slowing, two others maximal temporal slowing.

C. Parietal Lesions

There were ten cases with lesions in the parietal lobe.

Three of them showed maximal slowing at the parietal, two at the central electrode. In one case, slow activity was confined to the temporal electrodes, in one most prominent at the temporal electrodes. In one of these cases, the proper localization was indicated by focal slowing of the alpha activity at the parietal electrode. In this case too, as we noted in two cases with frontal lobe lesions mentioned above, the change in alpha activity at one of the medial electrodes was a more reliable indication of the location of the lesion than the slowing in the temporal region.

D. Occipital Lobe Lesions

There were 14 cases with lesions located in the occipital lobe.

In eight of these, slowing was maximal at the occipital electrode, although it appeared also at the temporal electrodes. In two cases, the occipital slowing was less prominent than the temporal slowing, which was maximal at the posterior temporal electrode. The scattering of the other cases is indicated in the table. Depression of alpha amplitude at the site of the lesion is fairly frequent in this group.

E. Temporal Lobe Lesions

There were 14 cases with lesions of the temporal lobe.

In ten slowing was maximal at the temporal electrodes with nine of these records showing a high degree of abnormality. In two others the degree of slowing at the frontal electrode and in one at the parietal electrode was greater than at any temporal electrode. Variations in alpha activity were not helpful in this group.

CLASSIFICATION BY LOCATION OF ELECTROENCEPHALOGRAPHIC ABNORMALITY

In this section we shall consider the various locations of electroencephalographic abnormality and describe the distribution of lesions associated with them.

I. Records with slowing confined to the temporal electrodes

There were 17 cases with slowing confined to the temporal electrodes.

Seven of these cases were lesions occupying the frontal lobe and constituted

15 per cent of the entire group of 45 frontal lobe cases. Six of the seven showed a low degree of abnormality, and the other a high degree of abnormality. Two of the 17 cases had lesions confined to the central region and these two constituted 14 per cent of the 14 central lesions. Both showed a low degree of abnormality. One of the 17 cases showed a lesion in the parietal lobe, and this one constituted ten per cent of the group of ten parietal lobe cases. It showed a low degree of abnormality. This group of 17 cases with slow activity confined to the temporal electrodes included no case with an occipital lobe lesion. There were five cases with lesions confined to the temporal lobe and these five constituted 36 per cent of the group of 14 cases with temporal lobe lesions. Of these five, four showed a high degree of abnormality and the other a low degree of abnormality. There were also two cases with thalamic lesions. In 14 of the 17 cases, the anterior temporal electrode showed a greater degree of abnormality than any of the other temporal electrodes (that is: midtemporal, posterior temporal and ear lobe electrodes).

In summary, in 17 per cent of the 101 cases, slowing was confined to the temporal electrodes. This occurred in about 13 per cent of non-temporal and in 36 per cent of temporal lesions. Thus slowing confined to the temporal electrodes is two to three times more frequent in cases with lesions confined to the temporal lobe than in lesions distributed elsewhere (except thalamus). In those cases with lesions confined to the temporal lobe, a high degree of abnormality was frequent (80 per cent), while in non-temporal lesions a high degree of abnormality was either absent as in the central and parietal group or infrequent (18 per cent) as in the frontal group. It is interesting that there were two cases of parasagittal lesions (one central and one parietal) with slowing confined to the temporal electrodes. However, in one of these cases, focal slowing of the alpha waves indicated the site of the lesion.

II. Records with maximal slowing at the temporal electrodes and less at the frontal electrodes

There were 18 cases with this distribution.

Fourteen of these had frontal lobe lesions. While there was always slowing at more than one temporal electrode, the greatest amount of slowing in all the cases with frontal lobe lesion appeared at the anterior temporal electrode and the next greatest amount at the frontal electrode. When one of the other temporal electrodes showed a greater degree of abnormality than the frontal electrode (four cases) the lesion was not in the frontal lobe but in one of the other locations, except occipital.

III. Records with maximal slowing at the temporal electrodes and less slowing at the parietal electrode

There were three cases (one frontal, one central and one temporal) in this group. The anterior temporal electrode was never the only temporal electrode affected.

IV. Records with maximal slowing at the temporal electrodes and less at the occipital electrodes

There were six cases in this group with maximal slowing at the temporal electrodes and with a smaller degree of slowing at the occipital electrode. The anterior temporal electrode was the least frequently and severely involved of the temporal electrodes in this group. Of these six cases there were two with occipital lesions. There were three cases with temporal lobe lesions and these three constituted 21 per cent of the group of 14 cases with temporal lobe lesions.

V. Records with maximal slowing at the frontal electrode

There were 28 cases with maximal slowing at the frontal electrode. This group included 19 cases with frontal lobe lesions and these 19 cases constituted 42 per cent of the group of 45 cases with frontal lobe lesion. There were also five cases with central lesions and these five cases constituted 35 per cent of the 14 cases with central lesions. In all cases but one, the anterior temporal electrode showed the greatest amount of slowing after the frontal electrode.

VI. Records with maximal slowing at the central electrode

There were only two cases in this group and they were both cases with parietal lesions.

VII. Records with maximal slowing at the parietal electrode

There were ten cases with maximal slowing at the parietal electrode. In four of these, the lesions were central in location and these four cases constituted 28 per cent of the group of 14 cases of central lesions. There were also three cases with parietal lesions and these three cases constituted 30 per cent of the group of ten cases with parietal lesions. In seven cases, with maximal slowing at the parietal electrode the anterior temporal electrode showed less slowing than at least one of the other temporal electrodes.

VIII. Records with maximal slowing at the occipital electrodes

There were ten cases with maximal slowing at the occipital electrode. Eight of these ten cases were cases with occipital lesions and these eight constituted 56 per cent of the entire group of 14 cases with occipital lesions. In these eight cases, the posterior temporal electrode was the maximally involved temporal electrode.

ADDITIONAL DATA ON SLOW ACTIVITY

The combination of frontal and temporal slowing with either the frontal or one of the temporal electrodes showing maximal abnormality, occurred in 46 cases. Thirty three of these were cases with frontal lobe lesions, six were cases with central lesions and only three with temporal lesions. In terms of percentages, the 46 cases with both temporal and frontal slowing included 73 per cent of all cases with frontal lobe lesions, 42 per cent of all cases with central lesions, and

21 per cent of all cases with temporal lesions. Slowing at both frontal electrodes occurred mostly in cases with frontal lesions and among these, especially often when the lesions were parasagittal.

When bursts of slow activity occurred, whether focally or diffusely, they were less reliable for purposes of localization than the irregular delta activity.

Variations of alpha activity

We found variations in alpha activity to be of some help in localization, though in general, considerably less useful than the appearance of delta activity. There were three cases in this series with no slow activity but with only focal slowing of alpha. One of these was a fronto-temporal lesion with slowing of alpha activity at the frontal and temporal electrodes. A second was a central lesion with slowing of alpha at the central electrode. The third was a parietal lesion. In this case, the slowing was maximal at the anterior temporal and posterior temporal electrodes and less marked at the parietal electrode which indicates that alpha slowing at a medial electrode also is a more reliable clue to localization than its slowing at the temporal electrodes.

In many cases with delta activity, we found some change in alpha activity as well. In some instances, alpha amplitude was decreased, in others increased. Decrease in amplitude was much more frequent than increase in amplitude. The location of the change of amplitude corresponded to the focus of delta activity, or at least to the abnormal side. Alterations in alpha amplitude were more frequently associated with records showing a high degree of delta abnormality than in records showing a low degree of delta abnormality except where the delta focus was occipital. In the presence of occipital delta foci, alpha voltage asymmetry was especially frequent even when the degree of slowing was low.

Slowing of alpha activity in records also showing delta did not follow quite the same rules. Alpha slowing was more often diffuse than it was focal except in those cases in which there was focal occipital delta. In the presence of such occipital delta, alpha slowing occurred more often focally (at the occipital electrode) than diffusely. It is interesting, too, that whereas diffuse slowing of alpha activity (on the affected side) appeared almost exclusively in records with a high degree of abnormality, focal slowing of alpha activity appeared even in the presence of a low degree of abnormality. In general, focal slowing of alpha corresponded to the site of the delta focus. However, where the two did not correspond, the more medial electrode affected, whether by delta or by slow alpha, was the better clue to the localization of the lesion.

DISCUSSION

It turns out from these data that for purposes of localization one must divide the electrodes into two groups: the medial electrodes including the frontal, central, parietal, occipital and vertex; and the lateral electrodes including the anterior temporal, midtemporal, posterior temporal and ear lobe electrodes. It would seem that in the presence of a lesion in almost any part of the cerebral

hemisphere (except perhaps occipitally), the temporal electrodes showed delta activity earlier and often to a greater degree than others. Therefore, although they are more sensitive to the presence of a lesion in the hemispheres, they are not reliable as indicators of its location. We may infer that when there is slowing at a medial electrode, whether or not there is slowing at one of the temporal electrodes as well, the medial electrode is usually the more reliable guide to the location of the lesion. When there is any degree of slowing at the vertex electrode, the lesion is parasagittal and parietal or central. When the slowing is confined to the temporal electrodes, one is justified in inferring the existence of a temporal lobe lesion only in the presence of a high degree of abnormality. When the degree of delta activity is low and limited to the temporal electrodes, the lesion may be almost anywhere, although it is most likely frontal.

We are sure that similar observations have been made by others, though only rare mention is made in the literature. Baudouin and Fischgold (3) suggested that the anterior portions of the brain gave rise to delta activity in the presence of disease more readily than most regions. Krueger and Wayne (4) in describing electroencephalographic changes following topectomy, observed two to five cps. activity in the anterior temporal area. "In some instances, this defect of the temporal lobe was much severer than that of the frontal area. We are not able to offer any explanation for this involvement of the temporal lobe since the incision did not go beyond the prefrontal area in any case."

We realize fully that the statement that the temporal lobe, in particular the anterior temporal lobe, is more sensitive in the sense of electroencephalographic disturbance than other regions, is not really an explanation either.wever, we Ho believe that this increased disturbance of the electroencephalogram in this region is not due to the particular vascular supply of this region. The predisposition of this area to vascular disturbance on the basis of its specific pattern of vascularity has been emphasized recently by Earle, Baldwin and Penfield (5) and Sano and Malamud (6). We have seen the temporal accentuation of electroencephalographic disturbance in cases where vascular disturbances were not of significance. With particular attention to this phenomenon, we have studied the electroencephalogram of patients with an extracerebral cause of the cerebral dysfunction (e.g. cardiac failure with hypoxemia) and with artificially induced hypoglycemia. These investigations are still in progress but seem to indicate that in these cases, too, the anterior temporal region shows the most severe slowing.

The numerical data yielded by this study are closely dependent upon the exact electrode placements. Comparison of localization data among laboratories, therefore, is almost impossible unless exactly the same system of electrode placement is used in every laboratory. For this reason, the numerical data given in this paper can be directly applied only in those laboratories following the system of electrode placement corresponding to ours. We would urge that laboratories, employing different systems of electrode placement, make similar numerical studies. We suspect that the general principles which we have inferred may be valid at least to a certain degree in those laboratories, though the specific proportions will, of course, differ.

SUMMARY

The location of 104 discrete lesions in the cerebral hemisphere has been compared with the electroencephalographic foci obtained.

We have found it misleading to assume that the electrode showing the greatest amount of slow activity is the one closest to the site of the actual lesion. The following procedure is much more useful. The electrodes may be considered in two groups. The medial group comprises frontal, central, vertex, parietal and occipital electrodes and the lateral group comprises the anterior temporal, mid temporal, posterior temporal and ear electrodes. Abnormality at the temporal group of electrodes appears sooner and often in greater degree than abnormality elsewhere in the presence of disease in almost any part of the cerebral hemisphere. While, therefore, it is a more sensitive indicator of the presence of such disease, it is a poor indicator of the location of the disease process. When one of the medial electrodes shows maximal slow activity, it may be considered a relatively reliable guide to the location of the disease process whether or not there is also slowing at the temporal group of electrodes. When slowing appears at the vertex electrode, the lesion is parasagittal and central or parietal. When slowing is confined to the temporal group of electrodes, the inference of a temporal lobe lesion is not justified, unless the degree of abnormality is high. When focal slowing in alpha activity is distributed somewhat differently from the delta activity, a medial electrode is always a better guide to the location of the lesion than a temporal electrode, no matter which of the two kinds of abnormality is medial and which is temporal. These rules are valid only for those laboratories employing the system of electrode placement proposed by us. For other systems of electrode placement the same principles will probably hold, but the numerical relations will undoubtedly be different.

It is probable that the temporal lobe, in particular the anterior temporal lobe, reacts electroencephalographically more severely to a disturbance than the more medial cortical regions. This problem is currently still under investigation.

REFERENCES

1. Strauss, H., Ostow, M., and Greenstein, L.: Diagnostic Electroencephalography. Grune and Stratton. New York, 1952.
2. Strauss, H., Ostow, M., and Greenstein, L.: Patterns of Spread of Electroencephalographic Abnormality. EEG Clin. Neurophys., 4: 378, 1952.
3. Baudouin, H., and Fishgold, H.: Localisation des Tumeurs Cerebrales par L'Electroencephalographie, Archiv fur Psychiatrie und Nervenkrankheiten, 183: 116, 1949.
4. Krueger, E. G., and Wayne, H. L.: Clinical and Electroencephalographic Effect of Pre-frontal Lobotomy and Topectomy in Chronic Psychoses. Arch. Neurol. and Psych., 67: 661, 1952.
5. Earle, K. M., Baldwin, M., and Penfield, W.: Incisural Sclerosis and Temporal Lobe Seizures Produced by Hippocampal Herniation at Birth. Arch. Neurol. and Psych., 69: 27, 1953.
6. Sano, K., and Malamud, N.: Clinical Significance of Sclerosis of the Cornu Ammonis. Arch. Neurol. and Psych., 70: 40, 1953.

SKELETAL OSTEOPHYTOSIS

EDGAR M. BICK, M.D.

New York, N. Y.

There is a well known group of clinically and roentgenologically obvious syndromes, ordinarily classified as separate lesions, the pathogenesis of which have been almost invariably misinterpreted ever since their introduction into medical nosology. During the past few years, the special study of vertebral osteophytosis, a major member of this group, has brought to attention the paucity of basic information available on the other related syndromes.

Osteophytes may of course appear at almost any part of the axial or appendicular skeleton. However, it is a matter of common experience that certain sites show a marked propensity for their occurrence (Fig. 1). Among these in order of relative frequency are the spine, the pelvis, the calcaneous (both the superior and inferior borders of the tuberosity), the proximal border of the olecrenon process, and the lower end of the femur at the adductor tubercle.

The osteophyte of the vertebral column, since its earliest notice by pathologists and roentgenologists, had been interpreted as representing some form of arthritis under a variety of modifying adjectives. That at the lower border of the tuber calcanei, the so-called heel spur, has been at times classified as a manifestation of gonorrhoea (especially in the older French literature), of gout, or of non-specific infection. The osteophyte on the olecrenon has been occasionally called a manifestation of gout. The lesion appearing at the lower end of the femur has been too often diagnosed as osteochrondroma or periosteal reaction to the trauma of horseback riding.

It has been impossible in the past to specifically relate these etiological factors to any of the syndromes mentioned, nor is it necessary to assume extrinsic causes. In fact some of these older assumptions were based on the frequency of diagnosis of gonorrhoea, gout and local bone infection during the decades in which the supposed relationships were first established. Unfortunately these statements persisted in the text-books long after their validity had been seriously questioned, if not contradicted.

Skeletal osteophytes may appear at any age but are infrequent under the age of thirty. From that time on frequency increases rapidly with each passing decade. In the spine, for example, Schmorl and Junghanns in the 1930's recorded the occurrence of vertebral osteophtes in 10% of specimens taken from third decade spines, and their increase in frequency to the degree of 90% in males over fifty, and 100% in females over sixty (5). In a large series of x-rays of the feet (300 cases) examined recently, so-called heel spurs occurred in about 8% of men over forty, and but rarely in women of any age. In the latter a small heel spur may be suggested by the x-ray films but no significant one appeared at any time.

From the Department of Orthopedic Surgery, the Mount Sinai Hospital, New York City

It is anatomically obvious that the common sites of localization of skeletal osteophytes were all points of insertion of particularly powerful tendons or ligaments. Those of the spine which have been especially studied in the Orthopaedic Research Laboratory of this Hospital grow from the chondroosseous vertebral ring apophysis into the branched insertions of the longitudinal veretebral ligaments at that site (1, 2). These vertebral osteophytes appear most frequently in the anterior longitudinal ligament, secondly in the lateral and least often in the posterior. Under proper stimulation these vertebral osteophytes may occur at adjacent surfaces and growing towards each other along the ligament from the so-called osseous bridge (Fig. 2).

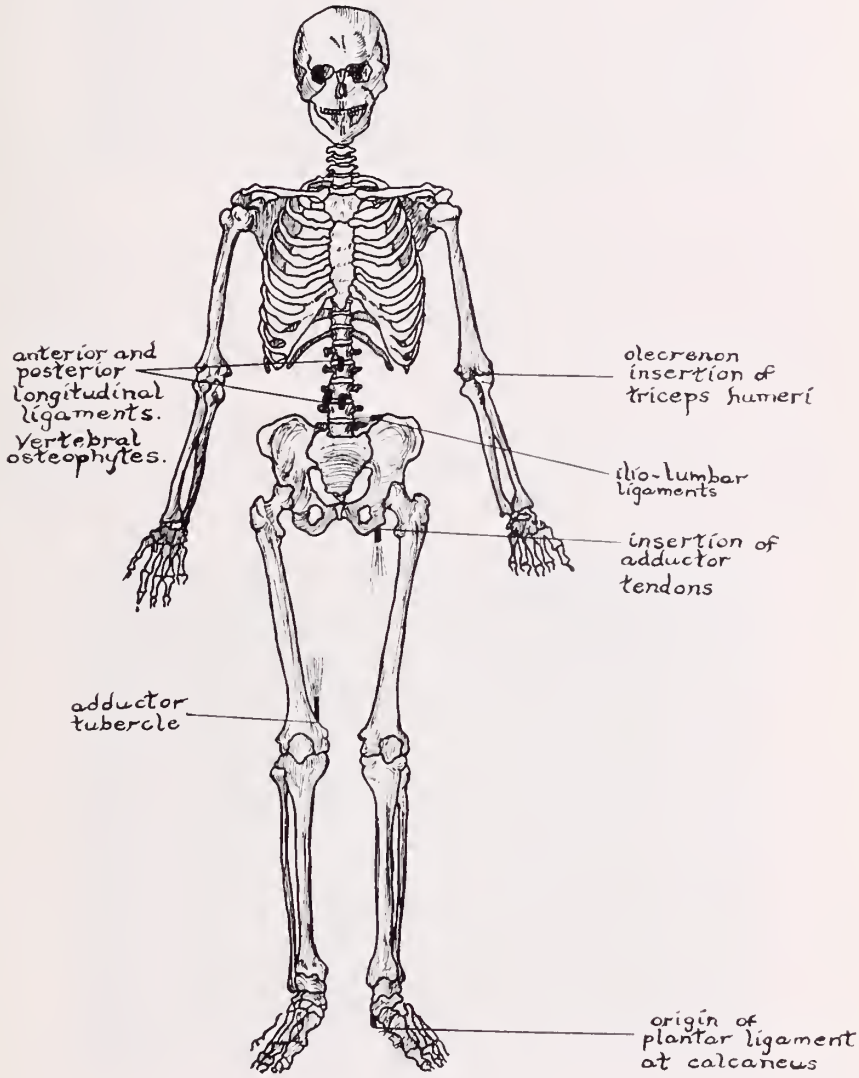

FIG. 1

At the pelvis, osteophytes occur commonly at one or more of several sites, more often than not symmetrically. Most frequent are those within the insertions of the ilio-lumbar ligaments arising from the iliac crests (Fig. 3). These powerful structures are important in maintaining the orthogrado posture in man. Another frequent site in the pelvic bones is the insertion of the strong adductor longus tendon into the pubic ramus.

On the calcaneus the two common localizations, the superior and inferior borders of the tuberosity are respectively the points of insertion of the tendo-Achilles and the long plantar ligament, the chief ligamentous check of the long arch. It is this latter which is commonly known as the heel spur (Fig. 4). Lastly among the common syndromes of osteophytosis is that of the proximal border of the olecrenon, the site of insertion of the tendon of the large triceps humeri muscle.

An osteophyte presents its own distinctive pathology (Fig. 5). It is a confined mass of productive primary bone growing within and replacing the fibers of ligaments or tendons at their insertions into periosteum and bone cortex. It does not extend beyond the ligament or tendon tissue. It shows no evidence of a disease process in the commonly accepted meaning of that term. There is no evidence of inflammatory, neoplastic or degenerative reaction. By its structure, localization and clinical nature it is best considered as an osteogenetic response to strain at areas of insertion of powerful tension tissues into bone. Basically it is therefore a traumatic phenomena, the result of persistent abnormal strain on osteo-periosteal tissue.

In the spine such strain may be due to postural imbalances or to localized imbalances following destructive lesions of the vertebrae, or paravertebral structures (3). In the plantar surface of the heel the osteophytic spur is usually found in heavy men or those who are on their feet for long periods. It occurs also

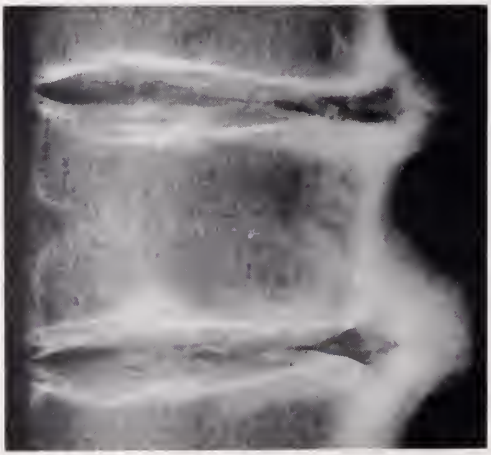

Fig. 2

Figures 2 and 5 reproduced with permission of the Am. J. Roent., (Vol. 73).

Fig. 3

following repeated periods of maximum effort such as required by professional athletes. At the insertion of the triceps, the adductor longus or the tendo-Achilles, physical activity, particularly in heavy set men, or the frequent repetition of special activities involving the muscles of those tendons, are usually part of the case history.

Skeletal osteophytes, in the sense in which the term is used here, must not be confused with osteochondromata, or with periarticular osteochondrotic excrescences found about the articular surfaces of degenerative arthroses. The former are of course the common benign tumor of bone composed of an osseous pedicle

Fig. 4

and core, capped by cartilage, and at times even containing cartilage cells within the mass. The latter are osteochondral attempts at repair of degenerative joint surfaces. Here too both bone and cartilage tissue is involved. The often times superficial resemblance of a skeletal osteophyte to an osteochondroma is due to the fact that the cartilage cap of the latter is radiolucent and only the osseous core is visible in x-ray. If the pedicle is long and narrow, and lies in the vicinity of a potentially common osteophyte, the error in interpretation may be understandable.

Skeletal osteophytosis then, is a syndrome of persistent muscle or ligament strain, occurring with some frequency at several sites in the axial and appendicular skeleton, and occasionally at almost any point of insertion of tendon or ligament. It may or may not be symptomatic. It may be a single lesion or appear at several locations. When it is symptomatic treatment is directed to relief of the strain either by extrinsic support or surgical release of the tissue. Occasionally when it appears quite large in a situation too closely subcutaneous, to the extent of inviting pressure symptoms, the osteophyte may have to be removed. However, such cases are most unusual.

Skeletal osteophytes are more or less limited in the extent of their breadth by the circumference of the ligament or tendon. They seem to be limited in their longitudinal growth by functional demand. They act in their growth as though they meant to attain a proportion sufficient to reinforce the need of the inserted structure. At least visibly they grow so far and no further, the size seeming to vary without other perceptible constraint.

A great deal of unnecessary repetition would be avoided if, in medical writings or in diagnostic reports, these natural osteogenetic responses to the stimuli of localized osteo-periosteal strain were no longer referred to as "arthritic" or neoplastic.

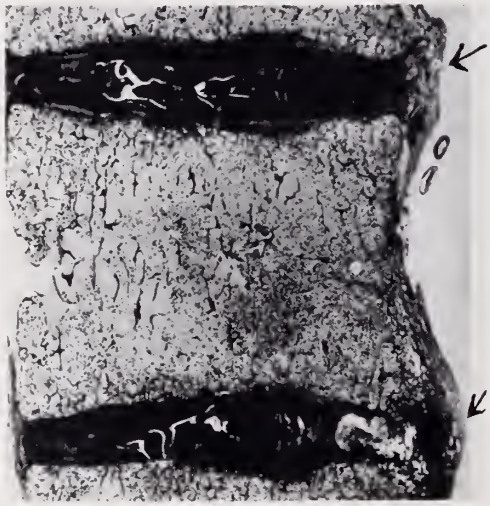

Fig. 5

In the spine relief of strain means a brace or belt; in the case of heel spur a foot plate. Both may be quite temporary needs and when the respective imbalances are corrected by the natural course of development of the osteophyte, the passing of symptoms suggest that the support is no longer required. It would seem that nature had constructed its own internal brace.

REFERENCES

1. Bick, E. M.: Osteohistology of the Normal Human Vertebrae. Jour. Mt. Sinai Hosp., 19: 490, 1952.
2. Bick, E. M., and Copel, J. W.: Ring Apophysis of the Human Vertebrae. Jour. Bone & Joint Surg., 33 A: 783, 1951.
3. Bick, E. M.: Vertebral Osteophytosis. Amer. Jour. Roentgen., 73: 979, 1955.
4. Collins, D. H.: The Pathology of Articular and Spinal Diseases. Williams & Wilkins, Balt. 1950.
5. Schmorl, G., and Junghanns, H.: Die gesunde und kranke Wirbelsäule im Röntgenbild. Fortsch. a. d. Geb. d. Röntgenstrahlen, 46: 361, 1932.

CURRENT CONCEPTS OF AFIBRINOGENEMIA IN PREGNANCY

MARTIN SILBERSWEIG, M.D.

New York, N. Y.

For many years, it has been noted that there is a hemorrhagic tendency associated with certain obstetrical complications. In 1901, De Lee described a fatal case of hemorrhage following abruptio placentae (1). Dieckmann in 1936 demonstrated lowered fibrinogen levels in a group of cases of abruptio placentae (2). Subsequent studies have revealed this hemorrhagic tendency to be present primarily in three obstetrical situations—abruptio placentae, amniotic fluid embolism, and intrauterine death with prolonged retention of the fetus.

The demonstration of a coagulation defect associated with decreased fibrinogen levels in these conditions, led to investigations concerned with the possible mechanisms of production of such defects in these types of obstetrical complications.

It has been demonstrated that human decidua, placenta and amniotic fluid possess thromboplastic activity. The slow injection of thromboplastin or extracts of decidual or placental tissue into animals will result in the deposition of fibrin cords parallel to blood vessel walls, primarily in the lung (3). If the animal is sacrificed 24 hours later, these changes will no longer be found, presumably due to fibrinolysis. The more rapid injection of the above materials results in almost immediate death (4).

Associated with these pathological lesions is fibrinogenopenia and failure of the blood to clot. Also, a mild thrombin inhibitory activity is demonstrated in the plasma (5). Page and Fulton infused extracts of human placenta into dogs and noted the same results plus a prolongation of the prothrombin time and a diminution in Ac-globulin concentration (6).

Therefore, experimental studies have conclusively demonstrated that decidual and placental amniotic fluid extracts contain thromboplastic activity, which when infused into animals results in a coagulation defect associated with diffuse intravascular clotting. The coagulation defect is presumably due to overutilization of some of the factors required in the clotting process. A correlation has been sought for in the syndromes clinically associated with this hemorrhagic tendency.

Reid, Weiner et al. reported several patients with amniotic fluid embolism whose blood failed to clot (7). These patients presented the clinical picture of collapse in labor with shock, followed by hemorrhage and afibrinogenemia. Uncontaminated amniotic fluid collected during labor contained a substance that behaved in many respects like thromboplastin, and when injected into rabbits, caused thrombosis. One of the patients died and squamous cells were found in the capillaries, arterioles and veins of the lung. The similarity to the experimental injection of thromboplastin into animals was noted. That is, following

From the Department of Medicine, The Mount Sinai Hospital, New York, N. Y.

the rapid injection of thromboplastin, shock and death resulted. Slow infusion resulted in survival, but also in intravascular fibrin deposition and subsequent fibrinogenopenia and failure of the blood to clot. They postulated that in the clinical condition described as amniotic fluid embolism, an infusion of amniotic fluid took place, usually during the first stage of a tumultuous labor. Rupture of the membranes in the upper uterine segment with dissection and escape of amniotic fluid through the utero-placental site into the sinusoids, and thence into the maternal circulation was invoked as the possible mechanism. They hypothesized that the occasional demonstration of a circulating fibrinolysin in such cases may represent the physiological response to extreme fibrin deposition associated with extensive intravascular clotting. Anti-thrombin activity, also occasionally demonstrated, may be also thought of in that light.

Ratnoff, in 1952, reported a case of amniotic fluid embolism which was studied in detail (8). His patient developed fibrinogenopenia (68 mgm.) an increase in plasma thrombin inhibitory activity, an increased plasma proteolytic activity and a slight thrombocytopenia.

Abruptio placentae has been similarly studied in an effort to correlate the clinical picture of a coagulation defect with the known experimental work referred to above. Reid and Weiner studied a large series of cases of premature separation of the placenta associated with a hemorrhagic tendency (9). They demonstrated a low serum fibrinogen, a slight decrease in prothrombin concentration, and the occasional presence of a circulating fibrinolysin (1 case.) They assume that thromboplastin is the responsible agent, derived from the damaged tissues of the detached placenta and decidua, gaining entrance into the circulation following the rise in intrauterine pressure. Clinically, they argue that artificial rupture of the membranes with a decrease in intrauterine pressure seems to diminish or prevent this phenomenon. The fibrinolysin occasionally seen may result from endothelial damage following intravascular fibrin deposition.

Johnson et al., studied 2 cases of abruptio placenta associated with a bleeding tendency and found not only a decrease in circulating fibrinogen and prothrombin but also, a marked diminution in plasma Ac-globulin (10). They postulated that the plasma Ac-globulin was diminished as a result of its utilization in extensive clotting in the following manner: the thromboplastin-like material released in abruptio placentae accelerates the conversion of prothrombin to thrombin, which in turn reacts with plasma Ac-globulin to convert it to serum Ac-globulin. Similar findings have been reported by Sawitsky, Hodgkinson and others (11, 12).

The third obstetrical complication recently reported associated with hemorrhagic tendency is that of long standing intrauterine death. These deaths are usually due to RH or group ABO antibody disease.

Reid reported 3 cases associated with intrauterine death of several weeks duration, all of whom bled profusely at delivery (13). All intrauterine deaths were due to RH disease. Studies revealed low fibrinogen levels, increase in prothrombin time, and mild thrombocytopenia. No fibrinolysin was demonstrated. Sometimes ecchymoses appeared before actual delivery of the dead

fetus. He postulated the possible entrance of thromboplastic material from autolysis of decidua and placenta into the circulation. Ratnoff reported a case in 1952 of fetal death at 6 months due to RH disease with hemorrhagic phenomena in the 8th month (14). The fibrinogen level was 92 mgm and the prothrombin time was elevated. No circulating anticoagulants or fibrinolysin could be demonstrated. Prior to hysterectomy, intravenous fibrinogen was administered and noted to disappear within 5 hours. Hodgkinson and Sawitsky have reported similar cases involving thrombocytopenia, Ac-globulin diminution and prothrombin diminution besides a decrease in fibrinogen levels (12, 11).

The following is a report of a case of abruptio placentae associated with fibrinogenopenia, thrombocytopenia and labile factor occurring on the wards of the obstetrical service of the Mount Sinai Hospital.

CASE REPORT

C.V., a 19 year old Puerto Rican female was admitted to the obstetrical service of the Mount Sinai Hospital on 8/28/54 with symptoms of pre-eclampsia. She was a primipara whose LMP was 11/8/53 and EDC was 9/5/54. Her blood group was A rh positive. Her past history was negative. Her prenatal course was uncomplicated except for the discovery of a positive Wasserman, for which she received 600,000 units of penicillin (lentopen) for 15 days. There was no history of hemorrhagic tendencies in the past. At 5 A.M. on 8/28/54 she was admitted to the labor floor with ruptured membranes and a complaint of severe throbbing headache for 24 hours. She had been in labor since 11 P.M. of 8/27/54.

Physical examination revealed a BP of 190/120 and pulse rate of 80. Heart and lungs were normal. One plus ankle edema was present. The fundus was felt 2 finger breadths below the xiphoid process. There was no vaginal bleeding. The fetal heart was heard in the RLQ. Urine examination revealed 4 plus albuminuria. She was treated with magnesium sulfate and morphine sulfate.

At 8:15 A.M. her BP was 170/125, the fetal heart was not heard and the uterus was hypertonic. At 9:45 her BP was 160/130. The fetal heart was not heard and a diagnosis of premature separation of the placenta was made. Intravenous pitocin was started at 10 A.M., and at that time it was noted that blood drawn failed to clot normally. The patient was transfused and at 11 A.M. received 2 grams of fibrinogen intravenously. At noon she was taken to the delivery room where she was delivered of a dead fetus, weighing 3290 grams. The patient was found to have a premature separation of the placenta. Approximately 1700 cc of unclotted blood escaped following delivery of the placenta. The patient received an additional 3 grams of fibrinogen intravenously while in the delivery room. A total of 2000 cc of blood and 5 grams of fibrinogen were administered. Post delivery her blood pressure returned to the normal range of 110/70 and she experienced no unusual post partum bleeding and had a benign post partum course.

Coagulation studies conducted are summarized below.

Laboratory Studies

Clotting Time

a) Before treatment—tiny pin head sized clot formed in 10 minutes and was extremely fragile.

b) After 2 grams of fibrinogen intravenously—a poor clot formed in 8, 10, and 14 minutes respectively with 2 to 3 plus retraction in 1 hour and many untrapped cells.

c) After a total of 5 grams of fibrinogen intravenously at 2 P.M. on 8/28/54, a good clot formed in 6, 7, and 8 minutes with good retraction. At 7 P.M. on 8/28/54, a good clot formed in 5, 5½ and 5½ minutes.

d) On 8/29 and 8/30, a normal clotting time was obtained with good clot formation.

Serum Prothrombin Activity

After 2 grams of fibrinogen intravenously a time of 17 and 16.3 seconds was obtained. The normal range is greater than 20 seconds. This indicates a decrease in prothrombin consumption which can be explained by a deficiency in "labile" factor as is demonstrated further below. On 9/1 a serum prothrombin activity of 28 and 25 seconds was obtained (normal value).

Prothrombin Times

Controls: 13.2 and 14.0 seconds; 10% dilution—22.0 seconds.

a) After 200 cc of blood, but before intravenous fibrinogen, prothrombin times of 35 and 33.0 seconds were obtained. This defect may be explained by the lack of circulating fibrinogen to give an end point, and possible lack of labile factor. 10% dilution prothrombin time was 21.0 seconds, which is normal, and may be explained by the addition of labile factor in the diluent.

b) After 2 grams of fibrinogen administered intravenously, values of 25, 23, and 25.2 seconds were obtained. 10% dilution prothrombin time revealed values of 19.8 and 20.0 seconds.

c) On 8/31 and 9/1, normal prothrombin times were obtained.

Test for the Presence of "Labile" Factor

The prothrombin time of old stored plasma (thus lacking the labile factor) was obtained at 51 seconds. The addition of fresh plasma to this, corrected the prothrombin time to 20 seconds and 21 seconds. The addition of the patient's plasma (before fibrinogen had been administered) to the stored plasma corrected the prothrombin time to 27.2 and 27.2 seconds. The addition of the patient's plasma after 2 grams of fibrinogen had been given, corrected the prothrombin time to 27.0 seconds. This demonstrated a deficiency of "labile" factor in the patient's plasma in so far as it was incapable of correcting the prothrombin time of stored plasma (lacking "labile" factor) to the same degree that normal fresh plasma was capable of doing.

Presumptive Qualitative Tests for Fibrinogen

(Method—addition of thrombin to the patient's plasma and reading the intensity of the resultant clot.)

The addition of 1 unit of thrombin to control plasma resulted in a 4 plus clot. Thrombin, added to patient's plasma before she had received fibrinogen revealed no clot. After 2 grams of fibrinogen had been administered, a 2 plus clot was obtained. After 5 grams of fibrinogen had been given, a 4 plus clot was noted. On 8/29 and 8/30, 4 plus clots were obtained.

Platelet Counts

On 8/28, the patient had platelet counts of 78,000 and 80,000. On 8/30 her platelet count was 120,000.

Fibrinolysin Studies

Clots obtained from the patient's blood at all phases of her acute disorder, were kept at 37° C for 48 hours and no evidence of fibrinolysin was observed.

Fibrinogen Levels (Biuret Method)

These results are subject to some criticism in terms of their exact level because of technical errors involved in this case. However, they are thought to represent the general range of fibrinogen level present.

Before administration of intravenous fibrinogen, the value was 30 mgm/100 cc. After 5 grams of fibrinogen intravenously, the values were 75 mgm/100 cc and 145 mgm/100 cc. The

former value was obtained at 2:30 P.M. on 8/28 and the latter at 7 P.M. on 8/28. On 8/29/54 the level was 225 mgm/100 cc and on 8/30/54 it was 310 mgm/100 cc.

DISCUSSION

This patient demonstrated a deficiency of several factors concerned in coagulation with acute premature separation of the placenta. Of primary importance was a deficiency in fibrinogen which was accompanied by a thrombocytopenia and a "labile" factor deficiency. No fibrinolysin was demonstrated. These multiple deficiencies are compatible with the concept of multiple intravascular thrombi resulting from the release of "thromboplastin-like" material into the systemic circulation following premature separation of the placenta.

As a result of these extensive widespread clots, it is hypothesized that the fibrinogen, platelets, and other factors are used up, resulting in deficiencies associated with a bleeding tendency. The intravenous administration of fibrinogen corrected her primary deficiency as noted in the above laboratory data.

SUMMARY

Afibrinogenemia has been noted in 3 primary obstetrical complications—premature separation of the placenta, amniotic fluid embolization, and prolonged intrauterine retention of a dead fetus. The physiological mechanisms involved in this coagulation defect are discussed from the point of view of the experimental and clinical evidence available.

A case of fibrinogenopenia associated with premature separation of the placenta is presented. Coagulation studies confirmed a deficiency of "labile" factor, platelets, and fibrinogen. The coagulation defect responded to the rapid administration of intravenous fibrinogen.

The demonstration of multiple deficiencies of clotting factors in this and other cases, lends support to the presently accepted concept that extensive intravascular clotting results from the release of circulating thromboplastin-like material into the systemic circulation during these obstetrical complications. Consequently, utilization of fibrinogen and other factors involved in coagulation, results in the above deficiencies, leading to a hemorrhagic tendency.

REFERENCES

1. De Lee, J. B.: A case of fatal hemorrhagic diathesis with premature detachment of the placenta. Am. J. Obst. & Gynec. 44: 785, 1901.
2. Dieckmann, W. J.: Blood chemistry and renal function in abruptio placentae. Am. J. Obst. & Gynec. 31: 734, 1936.
3. Schneider, C. L.: Thromboplastin complications of pregnancy, Bull. Margaret Hague Maternity Hosp. March, 1951.
4. Conley, C. L., and Ratnoff, O. D.: Studies in afibrinogenemia, Bull. Johns Hopkins Hosp. 88: 402, 1951.
5. Conley, C. L.: Ibid.
6. Page, E. W., Fulton, L. D., and Glendening, M. B.: The cause of the blood coagulation defect following abruptio placentae. Am. J. Obst. & Gynec. 61: 1116, 1951.
7. Reid, D. E., Weiner, A. E., and Roby, C. C.: Intravascular clotting and afibrinogenemia; the presumptive lethal factors in the syndrome of amniotic fluid embolism. Am. J. Obst. & Gynec. 66: 465, 1953.

8. Ratnoff, O. D., and Vosburgh, G. I.: Observations on the clotting defect in amniotic fluid embolism. New Eng. J. Med. 247: 970, 1952.
9. Weiner, A. E., Reid, D. E., and Roby, C. E.: II. Incoagulable blood in severe premature separation of the placenta: A method of management. Am. J. Obst. & Gynec. 66: 475, 1953.
10. Johnson, J. F., Siegers, W. H., and Broden, R. G.: Plasma Ac-globulin changes in placenta abruptio. Am. J. Clin. Path. 22: 322, 1952.
11. Sawitsky, A., Leahy, D. J., and Carpenter, F.: Massive post partum hemorrhage associated with coagulation defect. Am. J. Obst. & Gynec. 67: 349, 1954.
12. Hodgkinson, C. P., Margulis, R. R., and Luzadre, J. H.: Etiology and management of hypofibrinogenemia of pregnancy. J.A.M.A. 154: 557, 1954.
13. Reid, D. E. et al: III. Maternal afibrinogenemia associated with long-standing intrauterine fetal death. Am. J. Obst. & Gynec. 66: 500, 1953.
14. Ratnoff, O. D. et al: A hemorrhagic state during pregnancy—with the presence of maternal RH antibodies, death of the fetus and hypofibrinogenemia. Am. J. Med. 13: 114, 1952.

THE ARGENTAFFINE CELL OF THE GASTROINTESTINAL TRACT AND PANCREAS: SOME CLINICAL FEATURES

MILTON SINGER, M.D., AND IRMIN STERNLIEB, M.D.

New York, N. Y.

Scattered throughout the gastrointestinal tract are silver staining cells, named by various authors argentaffine, argentophile or argyrophile cells. Although their existence has been known for a long time, their function or functions have been poorly understood. It is the purpose of this review to summarize some of the evidence regarding the nature, distribution and function of these cells, and especially to call attention to some recently described clinical syndromes in which the argentaffine cell appears to be involved. Especially noteworthy has been the demonstration that two important physiological agents, glucagon and serotonin (5-hydroxytryptamine), are probably secreted by the argentaffine cells.

DISTRIBUTION

The argentaffine cell (1, 2) was first discovered by Heidenhain in 1870 in the stomachs of the rabbit and dog, and at that time he described its chromaffin nature. Since then numerous investigators have studied this cell and its role in the human body. This is attested to by the numerous names given to the cell: *chromaffin cell*, *entero-chromaffin cell*, *gelbe Zelle* or *yellow cell*, *basal granular cell* and *Kultschitzky cell*. It is present in the stomach (especially in the cardiac and pyloric glands), the duodenum, the villi and crypts of the small and large intestine, the appendix, the mucosa of the gall bladder and the pancreatic ducts. The alpha cells of the islets of Langerhans possess a similar tinctorial affinity for silver stains. The form of the argentaffine cells, like that of the principal cells of the intestinal tract, varies somewhat with their location.

DESCRIPTION AND EMBRYOLOGY

The nucleus, usually round and vesicular, is always located in the proximal half of the cell. The cytoplasmic granules show a strong affinity for chromium salts, thus the name chromaffin cells; they also reduce silver nitrate, staining black, thus the term argentaffine cells.

The embryological origin is still subject to debate. Some claim that the cells are of entodermal origin, while others state that they have wandered into the entoderm from some outside source. Lewis and Geschickter (3) claim that they are derived from the neuroectoderm and migrate first to the celiac ganglion, then along the nerves through the intestinal wall to the mucosa.

PHYSIOLOGY

Numerous theories have been developed as to the function of the argentaffine cells. Kultschitzky, in 1897, believed they were concerned with absorption of

From the Department of Medicine, The Mount Sinai Hospital, New York, N. Y.

protein. Parat (4) in 1924 thought they poured secretin into the blood, but Cordier (5) in 1925 claims to have disproved that theory. Masson (6) called them *neurocrine* in function, secreting neither into the blood nor lymph stream, but pouring their secretion directly upon the nerve endings in the mucosa. Best and Taylor (7) have imputed an endocrine or enzymatic activity to them.

At the present time it is generally accepted that the two substances, serotonin and glucagon, are in part probably secreted by the argentaffine cell.

Serotonin (*8, 9*). About 80 years passed between the demonstration that the vasoconstrictor power of blood increases after clotting and the isolation from serum of a purified substance responsible for this action. This substance, called serotonin, was found to be identical with 5-hydroxytryptamine and with a substance found in extracts of rabbit's stomach mucosa, called enteramine. It has the following chemical formula

There is evidence that serotonin is present preformed in platelets and that its liberation is incidental to the clotting process. Its presence was demonstrated also in the mucosa of the stomach, small and large intestine, spleen, brain and glandular tissue, carcinoid tissue and as a normal excretion product in human and dog urine. Older person's serum contains less serotonin than that of younger individuals (9).

Intravenously injected serotonin causes, in man, a short period of hyperpnea and a transient fall in blood pressure, followed by a rise or fall depending upon the dose and the degree of neurogenic constrictor tone (9). The degree of response is extremely variable. In the cat it causes a rise in the pulmonary artery pressure. Serotonin also contracts the isolated artery of the sheep, dog and ox. The vascular actions are antagonized by yohimbine and ergotamine. Contraction of the jejunum and uterus of guinea pigs, the rat uterus, the nictitating membrane and pupillary sphincter of the cat, as well as relaxation of the virgin cat uterus in vivo have been demonstrated.

The functions of serotonin under physiological conditions are still in the realm of speculation. It appears that it aids in hemostasis by its property of constricting mesenteric, muscle and skin arteries and arterioles. Its presence in the gastrointestinal tract suggests a role in the muscular or vascular control of this system.

Glucagon. Soon after the discovery of insulin, several investigators (10, 11) noted that the hypoglycemic effect was preceded by a short but significant hyperglycemia. This latter effect was interpreted as a "paradoxic" glycogenolytic effect of insulin, until, through purification of the pancreatic extracts (12), crystalline insulin was prepared which did not cause any hyperglycemia. The factor responsible for this hyperglycemic effect, named glucagon by Murlin, has been subsequently isolated from commercial insulin preparations (13), where it is found in variable proportions (from 0 to 10 per cent).

Glucagon (or hyperglycemic-glycogenolytic factor, HGF) is found in extracts of normal human and animal pancreas, as well as in the beta-cell free pancreas

of alloxan diabetic animals (14). The distribution in the dog pancreas parallels roughly that of the islet cells (most concentrated in the tail, least in the head of the pancreas) (15). Fetal pancreas as well as sclerosed pancreatic tissue (after duct ligation) contain HGF.

Since the pancreas of alloxan diabetic animals and the sclerosed pancreas, in which the acinar tissue has been destroyed, contain glucagon, the alpha cells have been suggested as the most probable site of its origin. Diethyldithiocarbamate and cobaltous chloride, which seem to cause selective damage to the alpha cells, reduce the amount of HGF to about one third (16).

Considerable amounts of glucagon are found also in the mucosa of the upper two-thirds of the dog stomach, corresponding to the distribution of the argentophil cells described by Tehver (17). Minimal quantities are found in the small bowel, but none in the liver.

Glucagon has been purified and crystallized (18). It is a protein with a probable molecular weight of 6000 to 8000. On a weight basis the biologic potency of HGF is at least 10 times greater than that of insulin (19).

When injected intravenously in rabbits, purified HGF manifests its action by a rapid rise in blood sugar which lasts for about 50 minutes. The rise is more pronounced if the injection is performed into the portal vein. Amounts of HGF too small to produce hyperglycemia when injected into a peripheral vein, may induce it when injected directly into the portal vein. The response is directly proportional to the amounts of liver glycogen present and it disappears when the glycogen reserves are depleted. This observation has been confirmed by in vitro experiments (20, 15) testing the effect of HGF on liver slices. It has been demonstrated that HGF stimulates the phosphorylase system and therefore the breakdown of glycogen to glucose-1-phosphate.

There are still considerable controversies concerning the question whether HGF is a true hormone and its relationship to insulin. Although there is proof for an antagonistic effect between HGF and insulin (19) in the intact animal, definite evidence is still lacking as long as an experiment of complete withdrawal and substitution of HGF has not been devised.

CLINICAL ASPECTS

The Problem of the Argentaffine Cell and Pernicious Anemia

A relationship between the argentaffine cell and pernicious anemia was suggested by Erös (21), who found atrophy of these cells in the intestinal tract in patients who died of pernicious anemia. He hypothesized that the argentaffine cells play a role in hematopoiesis, a view supported also by Jacobson (22). The nature of this "haemopoietic factor" has not been elucidated as yet.

Landboe-Christensen (23) disputed the association of the argentaffine cell and pernicious anemia. He showed that preparations from the human jejunum with well-developed argentaffine cells have not demonstrated any anti-pernicious anemia activity. On the other hand Jacobson (24) reported recently the presence of vitamin B_{12} in extracts from argentaffine cell tumors.

Carcinoid Tumors (Argentaffinomas) of the Gastrointestinal Tract

DeLashmutt and Kolozsi (25) have prepared an excellent review of the subject. Oberdorfer (26) called these tumors carcinoids to denote they were benign lesions having histological resemblance to carcinomas. Masson (6) designated them as argentaffinomas because of their affinity to silver stains. Most authors agree that carcinoids are slow-growing tumors but are potentially malignant. They comprise approximately 1 per cent of all neoplasms involving the gastrointestinal tract and are found in the appendix, cecum, small bowel, rectum and stomach.

In various collective series 85 to 96 per cent of carcinoid tumors are in the region of the ileo-cecal valve (appendix, terminal ileum or cecum). They are usually located in the tip of the appendix. Early obstruction usually causes symptoms of appendicitis and operation is usually done before metastases occur. Carcinoids are present in approximately 0.2 to 0.5 per cent of appendices removed for acute appendicitis (27).

The terminal ileum is the most common site of extra-appendiceal carcinoid tumors. The tetrad of symptoms consists of recurrent obstruction, pain, diarrhea without blood and weight loss (28). Twenty-five per cent of carcinoids of the small intestine are malignant and may cause symptoms by peritoneal implantation. Carcinoids of the duodenum may have a more marked malignant potential.

The rectum and stomach are the third and fourth most frequent sites respectively for carcinoids (29–31). In addition, carcinoids have been reported in the following unusual locations: Meckel's diverticulum, gall bladder, mesentery (for which no adequate explanation is given) and in gastric tissue present in an ovarian dermoid cyst.

Carcinoids occur as solitary nodules in the appendix, but not infrequently are multiple in the small intestine. They are yellow or light brown in color, probably due to their high lipid content. Most frequently they are anti-mesenteric and submucosal in location, but they can invade the mucosa and ultimately break through the subserosa. The carcinoids also enter lymphatic channels and perineural spaces spreading slowly to lymph nodes. Blood invasion via the portal vein is relatively frequent with the primary tumor in the small intestine. Metastases have been reported in the lung, liver, spleen, adrenal, kidney, subcutaneous tissue, bone marrow and brain. These tumors ulcerate slowly and encroach the lumen only secondarily. Histologically they consist of compact cellular nests, cords and sheets separated by variable amounts of fibrous stroma. The cellular masses tend to assume either a solid or a pseudoglandular appearance. There is often a tendency for peripheral palisading of cells in the larger aggregates.

The Syndrome of Malignant Carcinoid of the Small Intestine

The occurrence of both pulmonary stenosis and malignant carcinoid of the small intestine is reported by Thorson et al. (32). The simultaneous occurrence of both conditions in 16 patients suggests that this unsuspected combination is a clinical and pathological syndrome and not a coincidence. The principal findings and symptoms of the syndrome are:

(A) Malignant carcinoids of the small intestine with slow progression and metastases to the liver and to other parenchymatous intra-abdominal organs; common symptoms being dependent edema, frequent watery stools, borborygmi and abdominal pain, rarer symptoms being ascites and pleural effusion.

(B) Generalized widening of the small vessels of the skin, telangiectases in some and pellagra-like cutaneous lesions in several patients.

(C) Plethoric appearance and total or partial cyanosis, in the absence of polycythemia, and a peculiar patchy flushing of the skin, in some cases combined with pilomotor symptoms.

(D) Pulmonary stenosis of the valvular type and tricuspid regurgitation.

(E) Attacks of "bronchial asthma" of a rather unusual type, the chief features of which are cyanosis, "exanthema" over the face and body and sudden dyspnea.

Of the 16 reported patients, seven had this syndrome unequivocally. Four probably had it, and five had partial or not fully verified symptoms. The cause of the syndrome is believed to be a malignant carcinoid of the small intestine with hormonal properties. As a matter of fact, large amounts of serotonin have been found in carcinoid tumors and in the blood of patients with metastatic carcinoid. Sjoerdsma and Udenfried (33) showed that markedly elevated levels and measurement of urinary 5-hydroxyindole acetic acid (a metabolic product of serotonin) can be used as a simple diagnostic test for the condition.

The striking skin changes (flushes and plethoric discoloration) which occur suddenly and show an irregular distribution and color, seem to represent various stages of contraction or dilatation in both precapillary arteries and capillaries, presumably due to the vasoconstrictor effect of 5-hydroxytryptamine. During the generalized red flush quickened heart rate and large pulse pressure often occur. The idea that serotonin and tryptophan metabolism might be related to the development of the cardiac lesions is highly speculative. The diversion of tryptophan from normal pathways may be a factor in the nutritional disturbance and in the occurrence of signs of pellagra in some of these patients (33).

There is less convincing evidence at the present time that hypersecretion of glucagon manifests itself in the form of a clinical syndrome. Nevertheless a number of syndromes are described in which distrubances of glucagon secretion are presumed to occur.

Familial Hypoglycemosis. Hereditary metabolic disorder (34) characterized by spontaneous hypoglycemia, was found by McQuarrie (35) to be associated with a deficiency of pancreatic alpha-cells. Special tests for dysfunction of the adrenals, the pituitary and the liver were negative. No evidence of adenoma or hyperplasia of the beta-cells could be found in those patients in whom partial pancreatectomy has been performed.

Amelioration of Diabetes Mellitus Following Subtotal Gastrectomy. Friedman and his group (36) reported the interesting observations of a significant diminution in the insulin requirements of 3 diabetic patients following subtotal gastrectomy for peptic ulcer. This diminution occurred suddenly postoperatively and persisted after the patients regained their weight without an associated recrudescence of glycosuria. The authors have postulated that the amelioration of the

diabetes in their patients is due to the removal of the glucagon-secreting argentaffine cells of the gastric and duodenal mucosa.

Diabetes Mellitus. Ferner's (37) interesting findings of a shift of the normal ratio of alpha- to beta-cells in the pancreas of diabetics are certainly worth mentioning. This author showed, on the basis of histological examinations, that the deficiency of beta-cells is associated with an increase of alpha-cells, inferring an over-production of glucagon.

Oneirophrenia. From the urine of patients with a peculiar type of schizophrenia increased amounts of HGF have been recovered (38).

Von Gierke's Disease. Gyorgy (39) suggested that certain cases of Von Gierke's disease, which is characterized by low blood sugar, insulin sensitivity and the excessive storage of glycogen may be due to a deficiency of the hyperglycemic factor. This may well be true in some but not all cases of this disease. In one patient, studied by Shay, the injection of 10 mgm. of glucagon did not affect the blood sugar level.

SUMMARY

1. The nature, distribution and functions of the argentaffine cell in the gastrointestinal tract and pancreas are discussed.

2. Serotonin (5-hydroxytryptamine) and glucagon, substances elaborated by the argentaffine cells, are described.

3. Carcinoids (argentaffine cell tumors) of the gastrointestinal tract are reviewed.

4. The new clinical syndrome of malignant carcinoid of the small intestine with metastases to the liver, pulmonary stenosis and tricuspid regurgitation, peripheral vasomotor symptoms, bronchoconstriction and an unusual type of cyanosis is discussed.

5. Several clinical entities related to glucagon have been reviewed.

ACKNOWLEDGEMENT

We are gratefully indebted to Dr. Henry D. Janowitz for the help and advice given us in the preparation of the present manuscript.

REFERENCES

1. Cowdry, E. V.: Special Cytology, I. New York. P. B. Hoeber, 1928, p. 185.
2. Maximow, A. A., and Bloom, W.: Textbook of Histology. Philadelphia. W. B. Saunders Co., 1948.
3. Lewis, D., and Geschickter, C. F.: Tumors of the Sympathetic Nervous System: Neuroblastoma, Paraganglioma, Ganglioneuroma. Arch. Surg., 28: 16, 1934.
4. Parat, M.: Contribution à l'Histophysiologie des Organes Digestifs de l'Embryon. Compt. Rend. Soc. Biol., 90: 1023, 1924.
5. Cordier, R.: A propos de la Signification Physiologique de la Cellule Argentaffine. Compt. Rend. Soc. Biol., 93: 65, 1925.
6. Masson, P.: Appendicite Neurogène et Carcinoides. Ann. d'Anat. Path. 1: 3, 1924.
7. Best, C. H., and Taylor, N. B.: The Physiological Basis of Medical Practice, 3rd ed. Baltimore. Williams and Wilkins Co. 1943.
8. Reid, G., and Rand, M.: Serotonin. Austral. J. Exp. Biol., 29: 401, 1951.
9. Page, I. H.: Serotonin (5-hydroxytryptamine). Physiol. Rev., 34: 563, 1954.

10. MacLeod, J. J. R.: The Source of Insulin. J. Metab. Res., 2: 149, 1922.
11. Murlin, J. R., Clough, H. D., Gibbs, C. B. F., and Stokes, A. M.: Aqueous Extracts of the Pancreas. J. Biol. Chem., 56: 253, 1923.
12. Abel, J. J.: Crystalline Insulin. J. Pharmacol. & Exper. Therap., 31: 65, 1927.
13. Sutherland, E. W., Cori, C. F., Haynes, R. and Olsen, N. S.: Purification of the Hyperglycemic-glycogenolytic Factor from Insulin and from Gastric Mucosa. J. Biol. Chem., 180: 825, 1949.
14. Foa, P. P., Weinstein, H. R., and Smith, J. A.: Secretion of Insulin and of a Hyperglycemic Substance by means of Pancreatic-femoral Cross-circulation Experiments. Am. J. Physiol., 157: 197, 1949.
15. Sutherland, E. W.: The Effect of the Hyperglycemic Factor of the Pancreas and of Epinephrine on Glycogenolysis. Rec. Progr. in Horm. Res., 5: 441, 1950.
16. Vuylsteke, C. A.: Influence du Traitement au Cobalt sur le Contenu en Facteur H. G. du Pancréas de Cobaye. Arch. Internat. Physiol., 60: 128, 1952.
17. Tehver, J.: Über die Entero-chromaffinen Zellen der Hauss augetiere. Z. Mikr. Anat. Forsch., 21: 462, 1930.
18. Staub, A.: Purification and Crystallization of Hyperglycemic-glycogenolytic Factor (HGF). Science, 117: 628, 1953.
19. Foa, P. P.: Glucagon, the Hyperglycemic-glycogenolytic Hormone of the Pancreas. Adv. in Int. Med., 6: 29, 1954.
20. Shipley, R. A., and Humel, E. J.: Carbohydrate and Acetone Body Metabolism of Liver Slices and Effect of Insulin. Am. J. Physiol., 144: 51, 1945.
21. Erös, G.: Wien. Klin. Wchnschr., 46: 1121, 1933.
22. Jacobson, W. and Stewart, Sir Halley: The Argentaffine Cells and Pernicious Anemia. J. Path. and Bact., 49: 1, 1939.
23. Landboe-Christensen, E.: Argentaffin Cells and Pernicious Anemia. Am. J. Med. Sci., 223: 182, 1952.
24. Jacobson, W.: The Yellow Pigment of the Argentaffine Cells of the Mammalian Gastrointestinal Tract. In Ciba Foundation Symposium on Chemistry and Biology of Pteridines. Boston. Little, Brown and Co., 1954. p. 314.
25. De Lashmutt, R. E., and Kolozsi, W. A.: Carcinoid Tumors (Argentaffinomas) of the Gastrointestinal Tract: a Report of Twelve Cases. Gastroenterology, 26: 743, 1954.
26. Obendorfer, S.: Ueber die "kleinen Dünndarmcarcinome". Verhandl. d. Deutsch. Path. Ges., 11: 113, 1907.
27. Porter, J. E., and Whelan, C. S.: Argentaffin Tumors; Report of 84 Cases, 3 with Metastases. Am. J. Cancer., 36: 343, 1939.
28. Grimes, O. F., and Bell, H. G.: Carcinoid Tumors of Intestine. Surg. Gynec. and Obstet., 88: 317, 1949.
29. Mrazek, R. G., Jr., Godwin, M. C., and Mohardt, J.: Carcinoid Tumors; a Clinical and Pathologic Study of 27 Cases. Surg. Gynec. and Obstet., 96: 661, 1953.
30. Foreman, C. R.: Carcinoid Tumors: a Report of 38 Cases. Ann. Surg., 136: 838, 1952.
31. Martin, J. D., Jr., and Atkins, E. C., Jr.: Carcinoid of the Stomach. Surg., 31: 698, 1952.
32. Thorson, A., Björck, G., Björkman, G., and Waldenström, J.: Malignant Carcinoid of the Small Intestine with Metastases to the Liver, Valvular Disease of the Right Side of the Heart (Pulmonary Stenosis and Tricuspid Regurgitation without Septal Defects), Peripheral Vasomotor Symptoms, Bronchoconstriction, and an Unusual Type of Cyanosis: a Clinical and Pathologic Syndrome. Am. Heart J., 47: 795, 1954.
33. Sjoerdsma, A., and Udenfried, S.: Studies on Indole Metabolism in Patients with Malignant Carcinoid (Argentaffinoma). In Abstracts of papers on the program of the 47th Annual meeting of the Am. Soc. for Clin. Investig., Atlantic City, 1955. p. 9.

34. Anderson, R. C., and McQuarrie, I.: An Extension of Two Pedigrees of Hypoglycemosis. Am. J. Hum. Gen., 6: 257, 1954.
35. McQuarrie, I., Bell, E. T., Zimmerman, B., and Wright, W. S.: Deficiency of Alpha-cells of Pancreas as Possible Etiological Factor in Familial Hypoglycemosis. Fed. Proc., 9: 337, 1950.
36. Friedman, M. N., Sancetta, A. J., and Magovern, G. J.: The Amelioration of Diabetes Mellitus following Subtotal Gastrectomy. Surg. Gynec. and Obstet., 100: 201, 1955.
37. Ferner, H.: Zur Bedeutung des Glukagons. Ärztl. Praxis, 4: 6, 1952.
38. Morgan, M. S., and Pilgrim, J. F.: Concentration of a Hyperglycemic Factor from Urine of Schizophrenics. Proc. Soc. Exper. Biol. & Med., 79: 106, 1952.
39. Gyorgi, P.: Oral observation, at meeting of Phila. Endocr. Soc. March 1948. (quoted by Pincus, I. J.: A Hyperglycemic Factor Extracted from the Pancreas. J. Clin. Endocr., 10: 556, 1950).

NEAR FATAL ALLERGIC REACTIONS TO BEE AND WASP STINGS: A REVIEW AND REPORT OF SEVEN CASES

ELY PERLMAN, M.D.

Roslyn Heights, N. Y.

The animal kingdom includes a large number and variety of species capable of introducing foreign substances into human beings in many different ways (1, 2). In some instances these foreign substances are toxins, but whether they are primarily toxic or not, they are capable of inducing allergic or anaphylactic reactions. Indeed, one of the first observations on allergic reactions was made by Richet, Hericourt and Portier, who found that repeated injection of an extract of the tentacles of actinia caused dogs to become more and more susceptible to this toxic substance and they coined the word "anaphylaxis" to describe this phenomenon.

Allergic reactions to insects are more familiar and these usually consist of an exaggeration of the expected response. Blood sucking insects such as mosquitoes, bedbugs, fleas, and some flies, cause some people more than considerable local discomfort and in some cases generalized urticaria (3–5). Stinging insects such as bees, wasps and ants of the order Hymenoptera are of most interest because of the severity of the reactions. Mild allergic reactions are undoubtedly common and severe reactions are rare, but there is an increasing number of reports of severe anaphylactic reactions, some fatal, appearing in the literature (8–10).

Bees and wasps belong to the class Hexapoda, (5, 6, 11), order Hymenoptera. The bees belong to the apid family and the wasps to the vespid family. While there are many species of both it is usually the *social* bees and wasps which are so prone to attack and sting humans. The mud dauber, potter and blue mud dauber wasps are commonly encountered solitary wasps and cause no trouble. The social apids consist of the honey bees (family apidae) and the bumble bees (family bombidae) of which there are some dozen or more species found in this area. The commonest species of honey bee is apis mellifica and was introduced into this country from Europe. The local social vespids constitute about a dozen species whose members are more diverse in appearance but only three species are of importance to the present problem. Honey bee hives may contain as many as 50,000 inhabitants and the worker bees will attack promptly if disturbed and will attack in groups if the colony is apparently threatened. Bumble bees make small nests underground with fewer inhabitants and seem to attack individually and then only after being repeatedly disturbed.

The three commonly encountered species of social wasps are the paper wasp (polistes pallipes), the yellow jacket (vespine wasp or hornet, vespa maculifrons) and the common white-faced hornet (vespa maculata). The paper wasp is the largest, builds small open-bottomed, comb type nests under eaves and in other open but protected areas. He stings on provocation only but can be troublesome when irritated. The white-faced hornet builds the large, gray football-shaped

From the Department of Microbiology, The Mount Sinai Hospital, New York, N. Y.

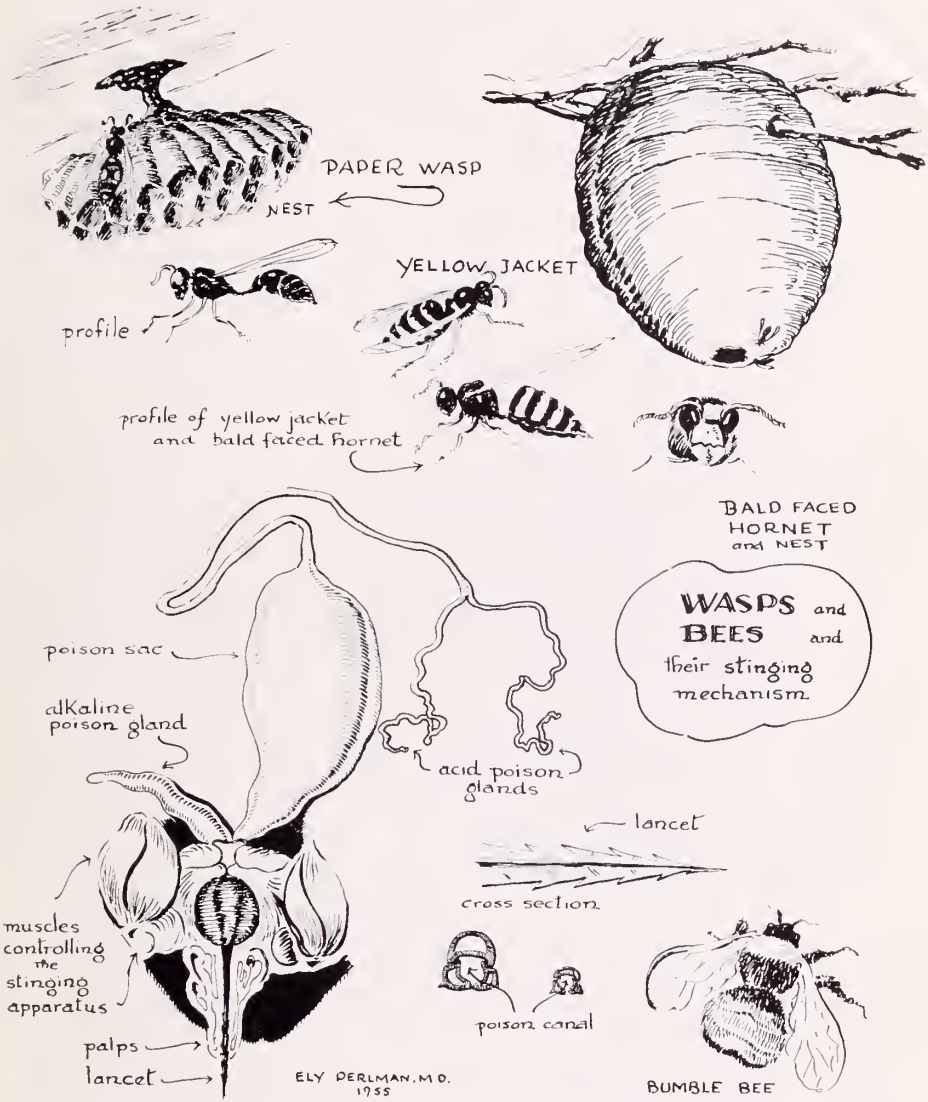
PAPER WASP
NEST
YELLOW JACKET
profile
profile of yellow jacket
and bald faced hornet
BALD FACED
HORNET
and NEST
WASPS and
BEES and
their stinging
mechanism
poison sac
alkaline
poison gland
acid poison
glands
lancet
cross section
muscles
controlling
the
stinging
apparatus
poison canal
palps
lancet
ELY PERLMAN, M.D.
1955
BUMBLE BEE

FIG. 1

paper nests often seen hanging from the branches of trees or shrubs. These nests contain as many as 10,000 citizens who pour out in large droves at the slightest threat to their colony. The yellow-jacket, so called because of the yellow bands on its body, is the smallest of the three but is probably the most frequently encountered, since its nests, although small, are just under the ground or on ground near old logs. They are therefore easily disturbed when mowing a lawn or when planting and they attack promptly when provoked (12).

In bees and wasps the stinging mechanism is similar and represents an adaptation of the egg laying apparatus (1, 11). It consists of an acid gland, a poison sac and an alkaline gland. The venom produced by the mixture of the contents of these glands is generally acid and is injected into the victim thru a hollow double lancet. In the instance of the worker bee, barbs are placed on the shaft of the lancet so as to cause the lancet and the poison gland to remain in the subject. The lancet should therefore be gently removed without squeezing the poison sac to avoid the inadvertent but additional injection of venom. The lancet of the queen bee, the bumble bee and the hornet have no barbs and that of the wasp has short barbs so that they can be withdrawn and each of these can therefore inflict multiple stings.

The exact nature of the poison is not understood and there are even considerable variations in the estimation of the amount injected, ranging from 0.05 ml. up to 0.3 ml. (13, 14), the most probable estimate being 0.05 ml. The venom's activity is destroyed by oxidation, by proteolytic enzymes and by heat. Formic acid is present in the toxin, and though it was originally considered to be the principal factor, it is present in too small amount to cause the primary effects (16). Based upon a variety of pharmacological studies it was thought that the acid gland manufactures inflammation-producing and stupefying substances while the alkaline gland secretes a convulsant factor. A hemolysin is also demonstrable and was considered to be one of the several enzymes found in the venom (14). Other investigators felt they could demonstrate three active toxic components; (a) a hemolysin—probably a phosphatidase, (b) a neurotoxin—causing edema and paralysis, and (c) a histamine-like substance causing primary inflammation (17). The evidence for the fact that the hemolysin and the neurotoxin are two separate substances is based upon the fact that acid hydrolysis of the whole venom destroys its neurotoxic activity without altering the hemolysin (18). Other chemical manipulations have also caused the separation of activities (dialysis, salting out, heating, etc. (19, 20)). It is postulated by some investigators that these two components (neurotoxin and hemolysin), one basic and one acidic, are bound in a salt linkage. An acid medium favors the salt linkage, while an alkaline medium favors separation (20).

This latter hypothesis is in better keeping with recent studies utilizing paper electrophoresis and chromatographic analyses. These technics revealed the presence of seven ninhydrin-reacting constituents, two of which are proteic (21). These two have been separated and Fraction I seems to exhibit all of the toxic properties previously ascribed to several different components. It is a "genuine" toxin with no enzyme action and exhibits the following activities:

(a) It directly hemolyzes "washed" erythrocytes

(b) It increases (after an initial depression) the blood pressure of the cat even after previous decapitation, adrenalectomy or the injection of atropine or antihistaminics.

(c) It paralyzes after a brief excitation, the phrenicus-diaphragm of the rat, the isolated perfused superior cervical ganglion of the cat and the guinea pig ileum. When applied locally it increases the permeability of the skin vessels and excised muscles. If placed on the conjunctiva of the eye or if injected intracutaneously, it causes local inflammation. Plasma cholinesterase is inhibited, fibrinogen is coagulated. Plasma hyaluronic acid and lecithin are inhibitors of Fraction I.

Fraction II, however, is pharmacologically inert and it is practically non-toxic. It contains hyaluronidase and phospholipase A, which splits lecithin to lysolecithin, inactivates structurebound enzymes such as succinodehydrogenase and brain and lung thromboplastin. It inhibits the heat coagulation of egg yolk and clears diluted egg yolk.

TOXICITY

The toxicity of the venom of these insects is not great enough to account for the severe local or generalized reactions which are being reported with increasing frequency. It is recorded that one bee keeper had been getting as many as 75 stings a day with no untoward effects. James and Walker (22) reported a case of an 18-month old child who received 477 stings with partial shock and anuria and who survived with the help of epinephrine and ACTH. Other reported cases of death from multipe insect stings followed more than 1200 stings (23).

ALLERGY

By far the majority of severe reactions reported in the literature have followed but one or a few stings (9, 10, 12, 24). This observation is suggestive of the allergic nature of these reactions. In addition, the clinical picture is reminiscent of experimental anaphylactic reactions and as far back as Richet's first description of this phenomenon it was suggested as the explanation.

As early as 1811 cases were described wherein but a few stings caused such severe or even fatal reactions that it was suspected even then that a mechanism other than primary toxicity was at work (25). Beginning about 1914, the term anaphylaxis was more frequently applied to such cases as reported by several observers (26–28). It became increasingly apparent that these unusual reactions were due to hypersensitivity, especially since many of the cases had numerous previous stings with little or no untoward reactions, only to develop generalized urticaria and even shock following a single subsequent sting (24, 29).

The first careful studies were done by Benson and Seminov who demonstrated that these sensitive patients have strong positive reactions to intracutaneous injections of high dilutions of bee venom. In addition, tests with a concentration of histamine more than that known to be present in this concentration of venom

gave slight reactions. Further, it was demonstrated that bee proteins extracted from the bodies of insects whose venom was previously removed, also gave strong reactions when tested in high dilution. These reactions were specific and did not occur in non-sensitive patients. It was further shown that the reactions were probably not due to entrained pollens. This was demonstrated by the absence of reactions to grass pollens and to honeycomb proteins. Trapped pollens were not found upon microscopic examination of the lancets of many bees.

TYPES OF REACTIONS

The reactions generally occur within a few minutes after the sting but it has been reported that delayed reactions can occur 24 hours later and even four to ten days later. In the last instance the mechanism was considered to be similar to that of serum sickness, the symptoms occurring after the first sting and only after an incubation period. Unequivocal cases of this type, however, are rare.

The reactions may consist simply of an unusual amount and/or duration of local swelling (30, 31). Generalized papular (32) urticaria has been reported but urticaria of the usual variety is a frequently observed symptom. Marked regional adenopathy consistently follows stings in some sensitive individuals. Petechial hemorrhages, locally, generalized, subcutaneous, or distributed thru many organs and even in the central nervous system have been observed (9). The more severe reactions consist of one or more of the following symptoms; constriction of throat and chest, dyspnea, asthma, cyanosis, abdominal cramps, diarrhea, nausea, vomiting, chills and fever, vertigo, laryngeal stridor, shock, loss of consciousness, involuntary bowel and bladder excretion, bloody frothing sputum. In a few instances reactions consisted of exfoliative dermatitis and recurrent neuritis (13). Numerous fatalities have been reported—many of them in the public press. The fatalities reported in the literature were reviewed by Williams (9) and those fatalities studied by autopsy were summarized by Schenkin, Tamisiea and Winter (10). The necropsy findings in the ten cases reviewed by Schenkin et al (10) showed the following changes in the order of their frequency of occurrence; pulmonary emphysema, cerebral edema, fatty metamorphosis of the liver, dilatation of the heart, epicardial hemorrhage, cerebral intraventricular hemorrhage, fluid blood, congestion of nasal sinuses, cutaneous petechiae, cerebral petechiae, meningeal hyperemia, fatty degeneration of the heart, cardiac hypertrophy, and lobar pneumonia.

Williams (9) reported eight fatalities from bee or wasp stings described in the American literature from 1915 to 1951 and 21 severe reactions. Schenken and co-authors (10) found five fatalities reported in the popular press in 1953 and nine fatalities with autopsy reports in the German literature (33). The number of fatalities and certainly the number of severe reactions is undoubtedly higher. Conversation with physicians, allergists and with entymologists will reveal that each knows of at least one instance of severe reactions. Many of the cases are reported in local newspapers and there is no way of estimating the total number of such reports.

IMMUNOLOGICAL CONSIDERATIONS

Specificity

Patients hypersensitive to bee and wasp stings are apparently allergic to an antigen contained in the body of the insect. The venom contains some of this antigen. Benson and Semenov (30) tested sensitive patients with an extract prepared from the bodies of bees whose venom sacs had been removed and obtained reactions equal to that obtained by an equivalent dilution of the venom itself. This was found true for yellow jackets by the present author in the case reported below. Benson (31) and Rockwell (4) report similar observations in cases of allergies to mosquito bites wherein various portions of the insects' bodies were used for testing. In spite of the often proposed possibility that pollens account for the reactions, it appears unlikely to the present author for the following reasons:

(a) Although many of the patients gave positive reactions to grass and/or ragweed pollen extracts, only about 50% of them were found to be allergic to pollens.

(b) The amount of pollen entrained in the stinger or in the body of the insect is likely to be insufficient to cause such severe reactions.

(c) Clinically, the type and severity of the reactions following insect stings generally differs from those seen in constitutional reactions to overdoses of pollen extracts.

(d) Severe reactions to wasp or bee stings can and have occurred during periods of the summer when the pollen to which the patient was specifically sensitive was not prevalent.

(e) Sensitivity occurs to many other insect stings and bites in cases where the insects are not associated with pollens (mosquito, etc.).

(f) Insect borne pollens are those least likely to cause clinical allergy.

Some authors report great specificity for the sensitivity, claiming that a patient may be *in*sensitive to another insect of a different species but of the same genus (34–36). It would appear that cross reactions between bees and wasp sensitivity is common but not clearly understood. Five out of seven bee-sensitive patients tested by Benson (31) gave positive reactions to wasp extract. Of ten patients sensitive to bees, six gave no reactions to pollens and several had no reactions to other allergens.

In all but a few cases previous stings were known to have occurred with no more than the usual reactions before the severe reaction occurred. This is generally the case in reports based upon the experience of bee keepers and their families. Since the sensitivity is, in a sense, an artificially induced one, similar to that of horse serum sickness, it would seem that any person, not necessarily atopic, could be sensitized, and in the reported cases a sufficient number gave no personal or family history of allergy. Four of seven of Mueller's patients (12) and four of eleven of Benson's patients (31) were not atopic. It is possible that in the atopic individuals reagin (passively transferrable, sensitizing antibody) may be present.

In one of Benson's cases he was able to demonstrate the presence of reagin by passive transfer tests. The sera of six wasp sensitive patients was studied by Loveless (37) and *none* contained demonstrable precipitating or reaginic antibodies.

Desensitization

Densensitization by injection of bee or wasp extract was first attempted by Fisher and Center (24). The term desensitization is often a source of justifiable confusion. Atopic people, sensitive to inhalants such as pollen or dust, contain reagins or sensitizing antibodies in their sera. If such a patient is injected with pollen or dust extract he develops neutralizing antibodies. This patient was not desensitized but, more accurately, he was immunized. If a patient develops serum sickness following the administration of tetanus antitoxin, one can demonstrate in the serum of this patient a precipitating antibody. This antibody can cause passive anaphylaxis in guinea pigs and has other properties which differentiate it from reagin (the sensitizing antibody described above). The repeated injection of horse serum (or antitoxin) into a sensitive patient in sub-shocking doses at 10 to 15 minute intervals is a true form of *rapid desensitization* and probably represents the exhaustion from the patient's blood of most of the circulating antibody in such a manner as to avoid any immediate reactions. Following this rapid and cautious desensitization, the patient is able to tolerate large doses of horse serum with no immediate effect—but the likelihood of this patient developing serum sickness within the next few days is *not* decreased by this type of desensitization. Nor is it possible to decrease the patient's sensitivity to horse serum by small weekly or biweekly injections or horse serum.

With these considerations in mind it is difficult to understand how a patient who has become sensitive to bee or wasp protein by the injected route can develop any protection from the artificial injection of the same venom at weekly intervals.

However, in spite of the fact that the immunological mechanism is not known, many workers have treated sensitive patients and it would appear that this has been attended with some degree of success. Thus, Braun (38) as early as 1925 described a 32 year old woman who lived near a swarm of wild bees. She received seven stings over a period of nine years and on each occasion the reactions became more severe. Within one minute she developed a hot flush over the entire body, followed quickly by a choking sensation, cough and swollen face and neck. She also suffered uterine cramps resembling labor pains. Anxiety, tremor and coma ensued and finally the patient became semicomatose for three to four days. Urticarial wheals generalized from the site of the sting. The patient was negative to routine skin tests. A provocative test was positive. The patient was desensitized with an extract of venom and after some time the patient was subjected to another sting and on this occasion suffered only a very mild systemic reaction.

In 1934, Fisher and Center (24) described a patient (a bee-keeper's wife) who was stung by bees on ten occasions with no ill effects. Shortly after the sixteenth sting, the patient developed urticaria and difficulty in breathing. The patient

became so sensitive that she would develop urticarial wheals at the site of contact with bee venom, and handling her husband's clothing would cause an attack of asthma. Each subsequent sting resulted in more severe and more rapidly developing symptoms. The patient was given a series of injections of whole bee extract (prepared by Lederle Laboratories) following which the patient's local and generalized symptoms became very mild.

Prince and Secrest (30) treated three patients with bee antigen. One of these patients was sensitive to bees and wasps and the other two were sensitive only to wasps. All of these patients had delayed local reactions, and no immediate severe anaphylaxis. However, after a series of injections the three were no longer sensitive and one was subsequently stung by bees and yellow jackets with only a slight reaction.

Benson and Semenov in 1930 (30) and subsequently Benson (31) studied in detail a total of eleven patients and attempted immunization with bee extract in seven. Of these, two were stung with no reactions. One of these received but eight inoculations and three years later was stung with no ill effect. The other, (a bee keeper) received injections for three months when he was stung 25 times with no reaction and this immunity persisted for the ten years during which the patient was observed. The remaining treated cases either received no further stings or were not heard from after being immunized.

McLane (34) in 1943 reported the interesting case of the wife of a professional bee keeper who became so sensitive that she would develop asthma from being near bees—and who was stung several times with severe general reactions. Wasp stings caused no trouble. Bee body extract was prepared and the first dose of one minim of 1:10,000,000 resulted in general urticaria and wheezing. She received a total of 30 injections at three to four day intervals and was able to tolerate 40 minims of 1:500. Three days after this last dose she was given one bee sting at weekly intervals with gradually decreasing reactions. The stings were taken at weekly intervals during the following four summers and every two weeks during the winter.

Fordwold (see discussion in ref. 36) felt that the immunity afforded by inoculation does not persist. He described a patient who was treated with wasp inoculations because of a nearly fatal reaction from stings. Approximately one year after treatment was lapsed he was stung several times with no reactions. However, subsequent stings were attended with increasing local reactions and then with systemic symptoms. He finally died from a sting.

Mueller and Hill (12) immunized seven children with severe anaphylactic reactions to wasps and bees. Only two of the group received subsequent stings but these were attended with moderate local reactions only.

Loveless (37) treated six patients with severe reactions to wasp stings. Treatment was administered in various ways including multiple intracutaneous injections and a single depository injection utilitzing the technic of Freund. Although the details were not published, proof of high clinical immunity was found by challenge tests with high doses and in some cases with insect stings that were deliberately or accidently inflicted.

REPORT OF CASES

Case #1 was a 26 year old housewife with a history of many previous yellow jacket stings with minimal local reactions. In 1940 the patient was stung six times and this resulted in angioedema, abdominal cramps and nausea, followed by generalized urticaria and asthma. She then became unconscious and slept for six hours. In 1947 the patient was stung once in the scalp by a yellow jacket. Within ten minutes she became nauseated and developed generalized itchiness and angioedema. Itchiness in stomach and generalized urticaria followed. She received epinephrine and Pyribenzamine and the symptoms subsided within one hour. The patient gave no family or personal history of allergy and was negative to intracutaneous tests with trees, grass and ragweed pollen extracts. The patient's sensitivity was specific in that she gave negative reactions to bee venom in a concentration as high as 1:10.

The author prepared venom and disembowled abdominal muscle extract from 48 yellow jackets kindly collected by Mr. Eddy of the New York Zoological Society. Marked local reactions of approximately equal intensity were obtained by intracutaneous tests with 1:100,000 dilution of the wasp venom and the muscle extract. This patient was not immunized. Recent conversation with the patient revealed that the patient did not get stung for two years. Since 1950 she was stung twice and on each occasion obtained epinephrine promptly. No severe reactions ensued.

Case #2. A 37 year old housewife was first seen on July 29, 1949 with a history of having been stung once on the left ear lobe by a yellow jacket while gardening. Within five minutes, the patient felt a tingling sensation in her tongue and hands, felt faint and had difficulty seeing. About five minutes later she became unconscious, cyanotic, and had convulsive seizures. There was frothing at the mouth and incontinence. Examination showed dilated pupils, bradycardia and a barely perceptible pulse. The patient received large amounts of epinephrine 1:1000 subcutaneously and some intravenously. Benadryl was also given parenterally and oxygen was administered. The patient gradually returned to consciousness and complained of severe abdominal cramps for which she was given intravenous calcium gluconate. The following day the ear lobe was swollen and it required 24 hours for the patient to return to normal. At that time the patient gave a negative reaction to wasp venom and wasp muscle extracts in a concentration of 1:200. Ragweed and grass pollen extracts gave a negative reaction. There was no family or personal history of allergies.

Nothing was done and the summer of 1950 was uneventful. In September of 1951, the patient was again stung by a yellow jacket on the dorsum of her arm and on this occasion she did not lose consciousness but did develop cyanosis and go into shock. There was incontinence and severe abdominal cramps. She received five cc of epinephrine very promptly and a small amount intravenously and oxygen by inhalation. Total duration of discomfort was 6 hours, perhaps because of the more prompt administration of epinephrine which was available in the form of Ampins. Following this the patient was again tested with wasp venom and gave a faint reaction at 1:100,000 and a definite one plus reaction at 1:10,000. Bee venom extract gave a negative reaction at 1:100,000, a slight reaction at 1:10,000 and a definite reaction at 1:1000. The wasp muscle extract gave a slightly smaller reaction at the same concentration. The wasp venom test gave a slight delayed reaction.

Immunization with bee and wasp extract was begun and except for tenderness at the site of injection there was no reaction until a dose of 0.35 cc of 1:100,000 wasp venom was given following which the patient experienced some dizziness for a half hour. The dose was increased cautiously and when 0.5 cc of wasp extract 1:10,000 was given the patient experienced abdominal cramps and headache one hour later. The dose was dropped and gradually increased with no reaction except that 0.35 cc of bee venom 1:10,000 gave local swelling on two occasions. The patient was finally able to tolerate a dose of 0.75 cc of 1:100 dilution of both the wasp and the bee extract with no effect. This dose has been maintained since but up to the present writing the patient has not suffered any further stings.

Case #3. A 36 year old housewife with a story of having been stung by a bee once in

childhood. She received one bee sting on the left knee in September, 1951. There was some local pain for five minutes. Following this there developed a bilateral axillary adenopathy, followed by a giant urticaria which involved back and abdomen. The patient then had a choking sensation associated with marked coughing, palpitations, and chills. She was given oral Pyribenzamine and gradually improved.

The patient had a history of grass and ragweed hay fever which was not severe. The patient gave a one plus reaction to bee and wasp venom 1:100,000 and to wasp muscle extract 1:100,000. Injections were given beginning with 0.05 of 1:100,000 bee extract and on each occasion there was marked local pain. When the patient got beyond 0.15 cc of 1:10,000 the local reactions became minimal and the patient finally received 0.35 cc of 1:1000 after which the injections were discontinued. From that time until the present writing the patient was not stung again.

Case #4. A 39 year old housewife had received many stings in the past and always responded with a moderate local reaction which only developed 24 hours later. In the early fall of 1954 she was stung by a yellow jacket and promptly developed a generalized itch and urticaria followed by nausea and vomiting. Because of an intolerance to epinephrine the patient was treated with intravenous Benadryl in small dose and improved gradually. Following this anaphylatic reaction the patient noticed a rash every time her hands became cold. The patient had no previous allergies and gave a negative reaction to test with grass and ragweed pollen extract. The patient had a definite cold urticaria readily elicited by the local application of ice water.

Intracutaneous test with wasp extract 1:100,000 (Arlington) was negative, with 1:10,000 was one plus and with 1:1000 was two plus. Injections were given two times weekly in gradually increasing doses. When 0.45 cc of 1:10,000 was given it resulted in severe local pain. The dose was gradually increased and two days following 0.5 cc of 1:1000 the patient was stung by a yellow jacket with no local or general reaction. The immunization is continuing and the patient is getting 0.6 cc of 1:100 (Hollister-Stain) with no reaction.

Case #5. A 9½ year old girl who was stung five times by yellow jackets three years ago with local reactions only. Each summer since, she suffered occasional stings. Following the last sting in September of 1954, the patient had no immediate or local reaction, but one week later developed a pruritic rash surrounding the area of the sting. This gradually got worse and ten days following the sting the patient developed generalized giant urticaria. Detailed history revealed that the patient was given penicillin two days before the sting and the case was considered to be a penicillin reaction. This was confirmed by testing with wasp extract. Negative reactions were obtained by intracutaneous test in a concentration of 1:1000. A provocative injection of 0.05 cc of 1:100 wasp extract caused no reaction.

Case #6. A 28 year old housewife was first seen in April 1955 with a history of being repeatedly stung by bees over the years with increasingly severe reactions. In the spring of 1955 the patient was stung by a "white-faced hornet" on the right wrist. There was a marked local reaction which was followed within 12 hours by an axillary adenopathy on the same side. This was associated with malaise, headache and some adenopathy on both sides of the neck. There was marked enlargement of the lymph nodes persisting for four to six weeks. The patient also claims that following each sting she developed a partial paralysis of the affected limb. She has vasomotor rhinitis and pollinosis and had been taking Chlor-Trimeton regularly. The patient was tested with Hollister-Steier wasp and bee venom 1:1,000,000 and 1:100,000 with negative reactions. Higher concentrations could not be used because they are supplied in 50 per cent glycerin.

Immunization with both bee and wasp extracts was begun and 24 hours after receiving 0.20 cc of wasp extract 1:1,000 the patient developed an axillary and posterior occipital adenopathy on the side of the injection with only minor local reaction and no other obvious explanation for the adenopathy. When 0.05 cc of bee extract 1:1000 was reached there was a marked local reaction. The dose of 0.25 cc of wasp 1:1000 had to be repeated four times before increasing, since on each of the first three occasions the patient experienced malaise and regional axillary adenopathy. The patient at the last visit reached a dose of 0.10 cc

of bee 1:100 and 0.10 cc of wasp 1:100 with no reaction. The patient has not been stung since. This patient made the observation that since she has stopped using perfumes she no longer seems to be surrounded by bees and wasps. Passive transfer tests were negative.

Case #7. A 37 year old man with a history of one previous sting attempted to move a laurel bush and disturbed a yellow jacket nest. He was stung six times around the ankles and within five minutes felt ill and developed a generalized giant urticaria. He took a Phenergan tablet (12.5 mg) immediately but in spite of this the urticaria became confluent over the entire body including the face. There was a marked tachycardia and chills, difficulty in breathing and nausea. Auscultation revealed no wheezing. The patient was given 40 units adrenocorticotrophic hormone in gelatin, 0.20 cc epinephrine and five mg. Chlor-Trimeton subcutaneously. He felt better after five minutes but 20 minutes later the skin flushed again and he was given an additional 0.30 cc of epinephrine 1:1000. Fifteen minutes later he vomited and had some diarrhea and then fell asleep. Three hours later he felt somewhat better but it required another 12 hours for the general malaise to disappear and an additional 48 hours for the local swelling and dependent edema of the legs to disappear. The patient was tested three weeks following this episode and gave negative reactions to 1:1,000,000 and 1:100,000 of both bee and wasp extract. Passive transfer tests were negative.

DISCUSSION

The chemistry of bee and wasp venom has been reviewed and the evidence for the allergic nature of the severe reactions to these stings has been presented in detail. Judging by the cases reported in detail above it would appear that a positive skin test is not required for proof of an existing allergy. Cases #2, 4, 6 and 7 gave negative reactions to high dilutions of the testing material. Case #7 may not have had sufficient time to develop positive skin reactions but this is not true of the others. Cases #2 and 4 gave positive reactions with higher concentrations only . Yet all of the cases were undoubtedly allergic, either from the clinical point of view or from the fact that the symptoms were reproduced in mild form when a sufficient subcutaneous dose was reached. In no instance was this dose higher than 0.2 cc of 1:1000 and this reaction could not have been due to a primary toxicity.

The evidence that injections of increasing amounts of the appropriate extract(s) does confer some degree of protection has been reviewed. In the author's group of patients there was one who was stung after immunization with no reaction and there were several patients who were able to tolerate doses of extract which they could not prior to immunization. Absolute proof that injections are useful cannot be obtained from the study of individual cases because it is not possible to predict the duration of sensitivity without therapy. However, from the cases in the literature and from cases #1, 2 and 6 above it can be seen that in at least a portion of the cases the sensitivity persists for years. The decision to immunize an individual case should be based upon the severity of the reactions and the frequency of the stings and whether the location or the occupation of the patient is such that future stings are likely to occur. In any case epinephrine, antihistamines and adrenocorticotrophic hormone or cortisone should be kept readily available for prompt use in the event of another sting.

At the present time the treatment of choice seems to be the prompt administration of epinephrine 1:1000 subcutaneously and in extreme instances intravenously. A tourniquet should be placed proximal to the site of the sting whenever

possible and the epinephrine should be given above the tourniquet. An antihistamine can be given by mouth or Chlor-Trimeton can be given with the epinephrine parenterally. Adrenocorticotrophic hormone should be given if the severity of the reaction warrants it. Epinephrine should be repeated at intervals depending upon the response of the patient.

Among the author's patients two had other allergies, mainly to pollens, and two of the six showed cross reactions between bee and wasp extract and one was specific. Tests for reagins were performed in two cases and were negative. One patient observed that her perfume seemed to attract bees and wasps. Although proof is wanting it is not an unreasonable possibility.

SUMMARY

The literature concerning the chemistry and immunology of bee and wasp stings has been reviewed. Evidence for the allergic nature of the reactions is presented. The value of immunization in highly sensitive patients is discussed and the author's cases have been described in detail.

REFERENCES

1. Bisse und Stiche einiger Gifttiere; Ihre Behandlung mit Calcium: publ. Sandoz, A. G., Basel, Switzerland. A copy of this detailed and beautifully illustrated book was provided through the kindness of Dr. C. Henze of Sandoz Pharmaceuticals.
2. Essex, H. E.: Animal Venoms. Physiol. Rev., 25: 1945.
3. Brown, E. P.: Insects and Allergy. Ann. Allergy, 2: 235, 1944.
4. Rockwell, E. M.: Some Investigational Studies Concerning Reactions to Insect Bites. Ann. Allergy, 10: 404, 1952.
5. Benson, R. L.: Diagnosis and Treatment of Sensitization to Mosquitoes. J. Allergy, 8: 47, 1936.
6. Bowen, R.: Insects and Allergic Problems. South. Med. Jour., 44: 836, 1951.
7. Morhouse, C. H.: Unusual Reaction to Ant Bites. J. A. M. A., 141: 193, 1949.
8. Darribere, P.: Revista Argentina de Allergia, 1: 207, 1954.
9. Williams, W. H., Jr.: Anaphylactic Shock from Wasp Stings. J. S. Carolina Med. Assoc., 47: 187, 1951.
10. Schenken, J. R., Tamisiea, J., and Winter, F. D.: Hypersensitivity to Bee Sting. Report of a fatal case and review of literature. Am. J. Clin. Path., 23: 1216, 1953.
11. Hegner, R. W.: Inverterbrate Zoology, The Macmillan Company, New York, 1933.
12. Mueller, H. L., and Hill, L. W.: Allergic Reactions to Bee and Wasp Stings. New Eng. J. Med., 249: 726, 1953.
13. Ross, A. T.: Peripheral Neuritis; Allergy to Honey Bee Stings. J. Allergy, 10: 382, 1931.
14. Phisalix, M.: Animaux Venemeux et Venins. Paris, Masson, 1: 359, 1922.
15. Strauss, W. T.: Antihistamine Therapy of Bee Stings. J. A. M. A., 140: 603, 1949.
16. Langer, J.: Über das Gift unserer Hönigsbiene. Arch. für Exper. Path. u. Pharmacol., 38: 381, 1896 1897.
17. Kellaway, C. H.: Animal Poisons. Ann. Rev. Biochem., 8: 541, 1939.
18. Reinert, M.: Zur Kenntnis des Biensengiftes, Festschrift Emil Barell, Basel, 1936.
19. Hahn, G., and Leditschke, H.: Über das Bienengift (IV Milleilung); Gewinnung beider Komponenten durch Dialyse. Ber-dtsch Chem. Ges., 70: 1637, 1937 II.
20. Hahn, G., and Fernholz, M. E.: Über das Bienengift (V Milleilung), Eine Einfache Chemische Trennung der Beiden Gift Komponenten. Ber. dtsch. Chem. Ges., 72: 1281, 1939.

21. Neumann, W., and Haberman, H.: Paper Electrophoretic Separation of Pharmacologically and Biochemically Active Components of Bee and Snake Venoms. Abst. of paper presented at 121st Annual Meeting of the A.A.A.S., Berkeley, Calif., Dec. 26 31, 1954.
22. James, E. S. and Walker, W. G.: ACTH in the Treatment of Multiple Wasp Stings. Canadian M. J., 67: 50, 1952.
23. Beck, B. F.: Bee Venom Therapy, New York. D. Appleton-Century Co., Inc., 1935.
24. Fisher, D. C., and Center, C.: Hypersensitivity to Bees Successfully Treated with Whole Bee Extract. J. Allergy, 5: 519, 1934.
25. Gould, G. M., and Pyle, W. L.: Anomalies and Curiosities of Medicine, Philadelphia: W. B. Saunders Co., 1900.
26. Waterhouse, A. T.: Bee Stings and Anaphylaxis. Lancet, 2: 946, 1914.
27. Goss, E. L.: A Bee Sting. Jour. Lancet, 46: 580, 1926.
28. Goodman, N. M.: Anaphylaxis from Bee Stings. Lancet, 2: 708, 1932.
29. Jex-Blake, A. J.: Bee Stings in Kenya Colony. Brit. Med. Jour., 2: 241, 1942.
30. Benson, R. L., and Semenov, H.: Allergy in its Relation to Bee Sting. J. Allergy, 1: 105, 1930.
31. Benson, R. L.: Diagnosis of Hypersensitiveness to the Bee and to the Mosquito, With Report on Successful Specific Treatment. Arch. Int. Med., 64: 1306, 1939.
32. Sonck, C. E.: Papular Wasp Sting Eruption. Acta Allergologica, 4: 1, 1951.
33. Halperin, L.: Über todliche Wirkung der Bienen und Wespenstiche. Inaugural Dissertation. Stettin, Germany and Basel, Switzerland: K. Schahl, 1936.
34. McLane, S. G.: Successful Treatment of Extreme Allergy to Bee Body and Bee Venom. Minnesota Med., 26: 1061, 1943.
35. Gordon, R. M.: Reactions produced by Arthropods Directly Injurious to Skin of Man. Brit. Med. Jour., 2: 316, 1950.
36. Swinny, B.: Severe Reactions from Insect Stings. Texas J. Med., 46: 639, 1950.
37. Loveless, M. H.: Allergy and Immunization for Wasp Stings. Paper presented at the 10th Annual Meeting of the American Academy of Allergy. Abstracted in J. Allergy, 25: 76, 1954.
38. Braun, L. I. B.: Notes on Desensitization of a Patient Hypersensitive to Bee Stings. S. African Med. Rec., 23: 408, 1925.
39. Prince, H. E., and Secrest, P. G., Jr.: Use of Whole Bee Extract in Sensitization to Bees, Wasps and Ants. J. Allergy, 10: 379, 1939.

INDEX TO VOLUME TWENTY-TWO

AFIBRINOGENEMIA in pregnancy, current aspects of, (M. Silbersweig), 322
Allergice reactions, near fatal, to bee and wasp stings: a review and report of seven cases, (E. Perlman), 336
Alumni awards, 257
Amyloidosis and idiopathic chronic ulcerative colitis, (I. Mandelbaum, D. Bryk), 24
Aufanger, H., Regional ileitis in children, 187
Angiography, intravenous cerebral: a technical note, (B. S. Wolf, M. Bender, S. A. Brahms), 62
Anorectal complications in regional ileitis, (S. D. Manheim), 184
Argentaffine cell of the gastrointestinal tract and pancreas: some clinical features, (M. Singer, I. Sternlieb), 328
Arnheim, E. E., et al., Enterolithiasis in the newborn, 58
Atheroselerosis: a review of the predisposing factors and the problems of treatment, (S. R. Robbin, S. Dack), 34
Atrophy, Sudeck's, reflex hyperemic deossification, (J. Hartley), 268

BACTERIAL sensitivity to erythromycin: two years experience, (S. S. Schneierson), 1
Bank, N., Relation of malignant hypertension to periarteritis nodosa in humans, 290
Bass, M., Profile: Henry D. Koplik, M.D., 229
Bassen, F. A., The variability of prothrombin time determinations with standardized thromboplastin preparations, 112
Bee and wasp stings, near fatal allergic reactions to: a review and report of seven cases, (E. Perlman), 336
Behavior in occupational therapy, psychodynamic aspects of, (L. A. Weinroth, F. Brown), 278
Bender, M., et al., Intravenous cerebral angiography: a technical note, 62
Bick, E. M., Skeletal osteophytosis, 316
Boas, Ernest Philip, M.D., obituary, 69
Brahms, S. A., et al., Intravenous cerebral angiography: a technical note, 62
Brown, F., et al., Psychodynamic aspects of behavior in occupational therapy, 278
Bryk, D., et al., Idiopathic chronic ulcerative colitis and amyloidosis, 24

CAROTID artery, internal, occlusion of: clinical diagnosis and therapy, (R. Ottenberg), 99
Cerebral angiography, intravenous: a technical note, (B. S. Wolf, M. Bender, S. A. Brahms), 62
Chatzinoff, A., et al., Congenital retinal detachment in microphthalmia with internal hydrocephalus, 54
Chicken pox, a minor epidemic, initiated by generalized herpes zoster, (H. W. Moscovitz), 79
Clinical experiences with the L. E. cell test, (S. L. Lee), 74
Colitis, ulcerative, some comparisons with, in extraintestinal manifestations of regional ileitis, (A. Cornell), 170
Colp, R., alumni award, 258
Congenital muscular dystrophy with mental deficiency, (De Lange's disease), (R. Marshall, H. Hodes), 119
Congenital retinal detachment in microphthalmia associated with internal hydrocephalus, (J. Laval, A. Chatzinoff), 54
Cornell, A., The extra-intestinal manifestations of regional ileitis: some comparisons with ulcerative colitis, 170
Cornell, A., et al., Ruptured jejunal intussusception with prolapse of intussusceptum, 47
Coronary occlusion, lack of correlation between the electrocardiographic findings and clinical course in, (H. Jaffe, A. M. Master), 264
Cullman, Joseph F., Jr., obituary, 73
Current aspects of afibrinogenemia in pregnancy, (M. Silbersweig), 322

DACK, S., et al., Atherosclerosis: a review of the predisposing factors and the problems of treatment, 34
De Lange's disease, congenital muscular dystrophy with mental deficiency, (R. Marshall, H. Hodes), 119
Deossification, reflex hyperemic (Sudeck's atrophy), (J. Hartley), 268
Diabetes insipidus, a discussion: including a reexamination of the site and mode of action of the antidiuretic hormone, (A. White), 15
Duodenal ulcer, recurrent, with normal patent stoma, 33 years after gastroenterostomy, (J. J. Leichtling, J. Garlock), 253
Duodenum and stomach, non-specific granulomatous disease of, (A. Riehman), 175

EARLY days of regional ileitis at The Mount Sinai Hospital—reminiscences, (B. B. Crohn), 143
Electrocardiographic findings and the clinical course in coronary occlusion, lack of correlation between, (H. Jaffe, A. M. Master), 264
Electroencephalographic localization, temporal slowing as a source of error in, (H. Strauss, M. Ostow, L. Greenstein, S. Lewyn), 306
Enteritis, regional, problems of, (H. D Janowitz), 223
Enteritis, regional, roentgen findings in, (R. M. Marshak, B. S. Wolf), 192

Enteritis, regional, surgical treatment of, (L. Ginzburg), 215
Enterocolitis, regional and regional ileitis, pathology of, (S. Otani), 147
Enterolithiasis in the newborn, (M. T. Khilnani, B. S. Wolf, E. E. Arnheim), 58
Erythromycin, bacterial sensitivity to: two years experience, (S. S. Schneierson), 1
Esophagus, normal, spontaneous rupture of, (F. Wachtel, G. Genkins), 6
Extra-intestinal manifestations of regional ileitis, some comparisons with ulcerative colitis, (A. Cornell), 170

GARLOCK, J., et al., Recurrent duodenal ulcer with normal patent stoma, 33 years after gastroenterostomy, 253
Gastroenterostomy, recurrent duodenal ulcer with normal patent stoma, 33 years after, (J. J. Leichtling, J. Garlock), 253
Gastrointestinal tract and pancreas, the argentaffine cell of: some clinical features, (M. Singer, I. Sternlieb), 328
Genkins, G., et al., Spontaneous rupture of the normal esophagus, 6
Ginzburg, L., Surgical treatment of regional enteritis, 215
Globus, Joseph H., Memorial Prize, 133
Gold, radioactive colloidal—a simple and safe method for its administration, (N. Simon, J. Melamed), 91
Granulomatous disease of the stomach and duodenum, non-specific, (A. Richman), 175
Greenstein, L., et al., Temporal slowing as a source of error in electroencephalographic localization, 306
Gross, S. W., Posterior fossa hematomas, 286
Group psychotherapy on a psychiatric ward of a general hospital, (A. Stein, W. C. Hulse, W. V. Lulow, M. R. Kaufman), 104

HARTLEY, J., Reflex hyperemic deossification (Sudeck's atrophy), 268
Hematomas, posterior fossa, (S. W. Gross), 286
Herpes zoster, generalized, initiating a minor epidemic of chicken pox, (H. L. Moscovitz), 79
Hodes, H., et al., Congenital muscular dystrophy with mental deficiency, (De Lange's disease), 119
Hulse, W. C., et al., Group psychotherapy on the psychiatric ward of a general hospital, 104
Hydrocephalus, internal, congenital retinal detachment in microphthalmia with, (J. Laval, A. Chatzinoff), 54
Hyperemic deossification, reflex, (Sudeck's atrophy, J. Hartley), 268
Hypertension, malignant, relation of, to periarteritis nodosa in humans, (N. Bank), 290

IDIOPATHIC chronic ulcerative colitis and amyloidosis, (I. Mandelbaum, D. Bryk), 24
Ileitis, regional and regional enterocolitis, pathology of, (S. Otani), 147
regional, anorectal complications in, (S. D. Manheim), 184
early days of at The Mount Sinai Hospital—reminiscences, (B. B. Crohn), 143
extra-intestinal manifestations of, some comparisons with ulcerative colitis, (A. Cornell), 170
in children, (H. Anfanger), 187
symposium on, 142
Ileocolitis, combined, syndrome of, (H. Yarnis), 159
Intravenous cerebral angiography: a technical note, (B. S. Wolf, M. Bender, S. A. Brahms), 62
Intussusception, ruptured jejunal with prolapse of intussusceptum, (E. E. Jemerin, A. Cornell), 47

JAFFE, H., et al., Lack of correlation between the electrocardiographic findings and the clinical course in coronary occlusion, 264
Janowitz, H. D., Problems of regional enteritis, 223
Jemerin, E. E., et al., Ruptured jejunal intussusception with prolapse of intussusceptum, 47

KAUFMAN, M. R., et al., Group psychiatry on a psychiatric ward of a general hospital, 104
Khilnani, M. T., et al., Enterolithiasis in the newborn, 58
Massive frontal osteoma: surgical management: report of 2 cases, 124
Koplik, H. D., Profile, (M. Bass), 229

LACK of correlation between the electrocardiographic findings and the clinical course in coronary occlusion, (H. Jaffe, A. M. Master), 264
Laval, J., et al., Congenital retinal detachment in microphthalmia associated with internal hydrocephalus, 54
L. E. Cell test, clinical experiences with, (S. Lee), 74
Lee, S., Clinical experiences with the L. E. cell test, 74
Leichtling, J. J., et al., Recurrent duodenal ulcer with normal patent stoma, 33 years after gastroenterostomy, 253
Lewyn, S., et al., Temporal slowing as a source of error in electroencephalographic localization, 306
Lulow, W. V., et al., Group psychiatry on the psychiatric ward of a general hospital, 104

MALIGNANT hypertension, relation of, to periarteritis nodosa in humans, (N. Bank), 290
Mandelbaum, I., et al., Idiopathic chronic ulcerative colitis and amyloidosis, 24
Manheim, S. D., Anorectal complications in regional ileitis, 184

Marshak, R. M., et al., The roentgen findings in regional enteritis, 192
Marshall, R., et al., Congenital muscular dystrophy with mental deficiency, (De Lange's Disease), 119
Massive frontal osteoma: surgical management; report of 2 cases, (M. L. Som, M. T. Khilnani), 124
Master, A. M., et al., Lack of correlation between electrocardiographic findings and the clinical course in coronary occlusion, 264
Melamed, J., et al., Radioactive colloidal gold—a simple and safe method for its administration, 91
Mental deficiency, congenital muscular dystrophy with, (De Lange's disease), (R. Marshall, H. Hodes), 119
Microphthalmia, congenital retinal detachment in, with internal hydrocephalus, (J. Laval, A. Chatzinoff), 54
Moscovitz, H. L., Generalized herpes zoster initiating a minor epidemic of chicken pox, 79
Muscular dystrophy, congenital, with mental deficiency, (De Lange's disease), (R. Marshall, H. Hodes), 119

NEAR fatal allergic reactions to bee and wasps stings: a review and report of seven cases, (E. Perlman), 336
Non-specific granulomatous disease of the stomach and duodenum, (A. Richman), 175

OBITUARY, Ernest Philip Boas, M.D., 69
Joseph F. Cullman, Jr., 73
Nathan Rosenthal, M.D., 261
Kaufman Schlivek, M.D., 141
Israel Strauss, M.D., 137
Occlusion of internal carotid artery: clinical diagnosis and therapy, (R. Ottenberg), 99
Occupational therapy, psychodynamic aspects of behavior in, (L. A. Weinroth, F. Brown), 278
Osteoma, massive frontal: surgical management; report of 2 cases, (M. L. Som, M. T. Khilnani), 124
Osteophytosis, skeletal, (E. M. Bick), 316
Ostow, M., et al., Temporal slowing as a source of error in electroencephalographic localization, 306
Otani, S., Pathology of regional ileitis and regional enterocolitis, 147
Ottenberg, R., alumni award, 257
Occlusion of internal carotid artery: clinical diagnosis and therapy, 99

PANCREAS and gastrointestinal tract, the argentaffine cell of: some clinical features of, (M. Singer, I. Sternlieb), 328
Pathology of regional ileitis and regional enterocolitis, (S. Otani), 147
Pelvimetry, roentgen: evaluation of the pelvic cavity, (B. S. Wolf), 236
Periarteritis nodosa in humans, relation of malignant hypertension to, (N. Bank), 290
Perlman, E., Near fatal allergic reactions to bee and wasp stings: a review and report of seven cases, 336
Posterior fossa hematomas, (S. W. Gross), 286
Problems of regional enteritis, (H. D. Janowitz), 223
Profile: Henry D. Koplik, M.D., (M. Bass), 229
Prothrombin time determinations, variability of, with standardized thromboplastin preparations, (F. A. Bassen), 112
Psychodynamic aspects of behavior in occupational therapy, (L. A. Weinroth, F. Brown), 278
Psychotherapy, group, on a psychiatric ward of a general hospital, (A. Stein, W. C. Hulse, W. V. Hulse, M. R. Kaufman), 104

RADIOACTIVE colloidal gold—a simple and sage method for its administration, (N. Simon, J. Melamed), 91
Radioactive gold treatment—results in 85 effusions due to cancer, (N. Simon), 96
Recurrent duodenal ulcer with normal patent stoma, 33 years after gastroenterostomy, (J. J. Leichtling, J. Garlock), 253
Reflex hyperemic deossification (Sudeck's atrophy), (J. Hartley), 268
Regional ileitis in children, (H. Anfanger), 187
Relation of malignant hypertension to periarteritis nodosa in humans, (N. Bank), 290
Retinal detachment, congenital, in microphthalmia associated with internal hydrocephalus, (J. Laval, A. Chatzinoff), 54
Richman, A., Non-specific granulomatous disease of the stomach and duodenum, 175
Robbin, S. R., et al., Atherosclerosis: a review of the predisposing factors and the problems of treatment, 34
Roentgen findings in regional enteritis, (R. M. Marshak, B. S. Wolf), 192
Roentgen pelvimetry: evaluation of the pelvic cavity, (B. S. Wolf), 236
Rosenthal, Nathan, M.D., obituary, 000
Ruptured jejunal intussusception with prolapse of intussusceptum, (E. E. Jemerin, A. Cornell), 47

SALK, J., alumni award, 258
Schlivek, Kaufman, alumni award, 257
obituary, 141
Schneierson, S. S., Bacterial sensitivity to erythromycin; two years experience, 1
Silbersweig, M., Current aspects of afibrinogenemia in pregnancy, 322
Simon, N., et al., Radioactive colloidal gold—a simple and safe method for its administration, 91
N. Simon, Radioactive gold treatment—results in 85 effusions due to cancer, 96
Singer, M., et al., The argentaffine cell of

the gastrointestinal tract and pancrease: some clinical features, 328
Skeletal osteophytosis, (E. W. Bick), 316
Som, M. L., et al., Massive frontal osteoma: surgical management; report of 2 cases, 124
Spontaneous rupture of the normal esophagus, (F. Wachtel, G. Genkins), 6
Stein, A., et al., Group psychotherapy on the psychiatric ward of a general hospital, 104
Sternlieb, I., et al., The argentaffine cell of the gastrointestinal tract and pancrease: some clinical features, 328
Stoma, normal patent, recurrent duodenal ulcer with, 33 years after gastroenterostomy, (J. J. Leichtling, J. Garlock), 253
Stomach and duodenum, non-specific granulomatous disease of, (A. Richman), 175
Strauss, H., et al., Temporal slowing as a source of error in electroencephalographic localization, 306
Strauss, Israel, M.D., obituary, 137
Sudeck's atrophy, reflex hyperemic decalcification, (J. Hartley), 268
Surgical treatment of regional enteritis, (L. Ginzburg), 215
Syndrome of combined ileocolitis, (H. Yarnis), 159

TEMPORAL slowing as a source of error in electroencephalographic localization, (H. Strauss, M. Ostow, L. Greenstein, S. Lewyn), 306
Thromboplastin preparations, standardized, the variability of prothrombin time determinations with, F. A. Bassen), 112

ULCER, recurrent duodenal, with normal patent stoma, 33 years after gastroenterostomy, (J. J. Leichtling, J. Garlock), 253

VARIABILITY of prothrombin time determinations with standardized thromboplastin preparations, (F. A. Bassen), 112

WACHTEL, F., et al., Spontaneous rupture of the normal esophagus, 6
Wasp and bee stings, near fatal allergic reactions to, a review and report of seven cases, (E. Perlman), 336
Weinroth, L. A., et al., Psychodynamic aspects of behavior in occupational therapy, 278
White, A., Diabetes insipidus, a discussion: including a reexamination of the site and mode of action of the antidiuretic hormone, 15
Wolf, B., et al., Enterolithiasis in the newborn, 58
Intravenous cerebral angiography: a technical note, 62
Wolf, B. S., et al, Roentgen findings in regional enteritis, 192
Wolf, B. S., Roentgen pelvimetry: evaluation of the pelvic cavity, 236

YARNIS, H., The syndrome of combined ileocolitis, 159

MOUNT SINAI HOSPITAL
JACOBI
LIBRARY

11323

Journal of the Mount Sinai
Hospital
v. 22 May 1955-Dec. 1955

LEVY LIBRARY MT. SINAI MEDICAL CENTER
3 4805 0059405 7